

# Early isolated central nervous system relapse of mantle cell lymphoma successfully treated with ibrutinib and CAR T-cell therapy

Časný izolovaný relaps lymfomu z buněk pláště v centrální nervové soustavě úspěšně léčen pomocí ibrutinibu a T-lymfocytů s chimerickým antigenním receptorem

Hrušková A., Szotkowská R., Papajík T., Obr A.

Department of Hemato-Oncology, Faculty of Medicine and Dentistry, Palacký University Olomouc and University Hospital Olomouc

**SUMMARY:** Mantle cell lymphoma (MCL) is a relatively rare and clinically distinct subtype of non-Hodgkin lymphoma. Involvement of the central nervous system is an uncommon manifestation at both diagnosis and recurrence. Central nervous system (CNS) relapse more frequently occurs in the context of aggressive disease behaviour and portends a poor prognosis. However, advances in therapeutic strategies for MCL have opened the possibility of achieving durable remission, even in this high-risk presentation. We report a case of a patient who developed an early, isolated CNS relapse following autologous stem cell transplantation. The patient was successfully treated with a sequential treatment protocol combining chemoimmunotherapy, ibrutinib and chimeric antigen receptor T-cell therapy.

**KEY WORDS:** mantle cell lymphoma – CNS involvement – ibrutinib – CAR T-cell therapy

**SOUHRN:** Lymfom z buněk pláště (MCL) je jedním ze vzácnějších podtypů B-nehodgkinských lymfomů. Postižení centrálního nervového systému je raritní, a to jak v době diagnózy, tak při recidivě. Relaps v centrální nervové soustavě (CNS) se častěji vyskytuje u nemocných s agresivními biologickými znaky nemoci a jedná se o prognosticky nepříznivý stav. Vzhledem k novým terapeutickým možnostem u pacientů s MCL je nicméně možné dosažení dlouhodobé remise i u těchto vysoce rizikových nemocných. V této kazuistice popisujeme případ pacienta s časným izolovaným relapsem v CNS po autologní transplantaci krevetvorných buněk. Pacient byl úspěšně léčen kombinací imunochemoterapie, ibrutinibu a T-lymfocytů s chimerickým antigenním receptorem.

**KLÍČOVÁ SLOVA:** lymfom z buněk pláštěvé zóny – postižení CNS – ibrutinib – CAR-T lymfocyty

## INTRODUCTION

Mantle cell lymphoma (MCL) is an uncommon subtype of non-Hodgkin lymphoma (NHL) with a heterogeneous clinical course. It is typically characterized by the hallmark chromosomal translocation t(11;14)(q13;q32), which results in the overexpression of cyclin D1. The most recent World Health Organization Classification of Haematolymphoid Tumours identifies three clinicopathologic variants: classic (nodal) MCL, non-nodal (primary leukemic) MCL, and *in situ* MCL. By cytomorphology, three prognosti-

cally distinct variants of nodal MCL are described: classic, pleomorphic, and blastoid variants [1]. Approximately 10% of MCL cases present at diagnosis with peripheral blood involvement (leukemic presentation), splenomegaly, and minimal or absent lymphadenomegaly. Some of these patients can be initially managed with a watch-and-wait strategy [2]. The majority of patients are diagnosed at an advanced stage, typically with nodal or combined nodal and extranodal involvement, and require immediate initiation of treatment.

While the historical median overall survival (OS) ranged between three and five years, modern diagnostic and therapeutic strategies have extended survival to more than 10 years [3–5]. Central nervous system (CNS) involvement remains rare, occurring in approximately 1% of newly diagnosed MCL cases and in 3–5% of relapsed cases [6,7]. Known risk factors for CNS infiltration include high-risk morphologic variants (blastoid or pleomorphic forms), elevated lactate dehydrogenase, and, in several studies, advanced disease stage (III/IV),

a high Mantle Cell Lymphoma International Prognostic Index (MIPI) score, and an increased Ki-67 proliferation index ( $\geq 30\%$ ) [6,8,9]. Although there is no established standard of treatment for MCL with CNS relapse, a combination of systemic chemoimmunotherapy (CIT) and intrathecal chemotherapy has been used in most cases. Treatment regimens mainly include cytostatic agents capable of penetrating the blood-brain barrier, most commonly methotrexate (MTX) and cytarabine (AraC) [8,10]. Alternative treatment modalities include intrathecal chemotherapy alone, radiotherapy, or best supportive care. In recent years, novel treatment options penetrating the blood-brain barrier have been explored for MCL patients with secondary CNS involvement including Bruton's tyrosine kinase inhibitors and chimeric antigen receptor (CAR) T-cell therapy [11,12].

## CASE REPORT

A 62-year-old male presented to our department in September 2023 with a history of lumbar back pain, fatigue, and leg cramps. An ultrasound scan revealed massive hepatosplenomegaly, and blood tests showed severe anaemia (80 g/L), leucocytosis ( $136 \times 10^9/L$ ) with absolute lymphocytosis ( $127 \times 10^9/L$ ), and moderate thrombocytopenia ( $97 \times 10^9/L$ ). The patient's medical history included chronic back pain, requiring hospitalization in 2006, and benign prostatic hyperplasia.

Flow cytometry of peripheral blood identified clonal B-lymphocytes with a typical MCL phenotype. Molecular testing confirmed cyclin D1 positivity. Cytogenetic analysis with fluorescence *in situ* hybridization revealed the t(11;14) translocation, 11q deletion (with ATM gene loss), and an isochromosome 8 with MYC amplification. Computed tomography (CT) imaging confirmed hepatosplenomegaly and mediastinal and mesenteric lymphadenopathy, with a maximum diameter of 2 cm at both sites.

The final diagnosis was established as MCL with t(11;14), clinical stage IVB ac-

cording to the Ann Arbor classification, classic morphology on peripheral blood smear, 11q deletion (ATM gene loss), and intermediate risk by MIPI score [13]. Due to the need for urgent treatment initiation and the presence of only minimal lymphadenopathy, a lymph node biopsy and positron emission tomography / computed tomography (PET/CT) were not performed. At the time of diagnosis, there were no clinical signs or symptoms of CNS involvement.

The patient began standard CIT, alternating R-CHOP (rituximab, cyclophosphamide, doxorubicin, vincristine and prednisone) and R-DHAOx (rituximab, cytarabine, oxaliplatin and dexamethasone) regimens. The first two cycles were complicated by an anti-CD20 infusion reaction, laboratory tumour lysis syndrome, and infections requiring intravenous antibiotics. After two cycles of treatment, an interim PET/CT scan showed partial remission. Laboratory assessment indicated normalization of blood counts. Following the sixth cycle, stem cells were successfully harvested for an autologous transplant. According to the PET/CT scan, complete metabolic remission (CMR) was achieved after six cycles of treatment.

In March 2024, our patient underwent an autologous stem-cell transplant (ASCT) after R-BEAM conditioning. During his hospital stay, he experienced a single episode of grade III febrile neutropenia and grade II oral mucositis, as defined by the Common Terminology Criteria for Adverse Events (CTCAE) [14]. Patient was discharged in proper condition on day +19 after stem-cell infusion. By day +58, he developed neutropenia ( $< 1.0 \times 10^9/L$ ) and T-cell lymphocytosis ( $6.0 \times 10^9/L$ ), as determined by flow cytometry. For potentially early relapse detection, a PET/CT scan was performed on day + 65, confirming ongoing CMR. Due to prolonged neutropenia and for complete restaging on day +107, a bone marrow biopsy was performed. No MCL cells were detected, but parvovirus B19 was identified by polymerase

chain reaction testing for opportunistic viral infections. The patient was started on immunoglobulin replacement therapy (once monthly) and granulocyte colony-stimulating factor (once or twice weekly, filgrastim) to maintain an absolute neutrophil count of greater than  $1.0 \times 10^9/L$ . The treatment was planned to end once parvovirus B19 negativity was confirmed in the peripheral blood.

Rituximab maintenance therapy began in September 2024. In November 2024, however, the patient presented with tingling in the lower limbs and lumbar back pain. A physical examination revealed no lymphadenopathy or hepatosplenomegaly. The patient did not have B symptoms, and laboratory tests revealed only mild neutropenia, with no change from the last check. A lumbosacral spine CT scan demonstrated degenerative changes in the lumbar and sacral spine. A subsequent emergency visit revealed urinary retention requiring catheterization, but the patient was discharged without further contact with our department. The following day, he was admitted with an Eastern Cooperative Oncology Group performance score of 3, severe weakness, and new-onset headache. A neurological examination revealed spinal ataxia, paraparesis of the lower limbs, and hyperreflexia. Magnetic resonance imaging (MRI) showed a tumour in the Th3-4 segment sized  $40 \times 3.5$  mm (Fig. 1). A lumbar puncture confirmed massive MCL infiltration in the cerebrospinal fluid (CSF). Flow cytometry and molecular analysis were positive for cyclin D1 and t(11;14). PET/CT showed no systemic involvement. In the next step, a ventricular catheter reservoir was inserted by a neurosurgeon.

The patient began receiving low-dose corticosteroids and systemic CIT with rituximab, MTX, AraC and thiotepa (MATRIS regimen), along with ibritinib and intrathecal cytostatic applications (MTX, AraC) – two procedures in four days. The first cycle was complicated by CTCAE grade IV severe colitis, requiring com-

plex care, including nursing and rehabilitation [14]. Subsequent MRI scans showed no tumour, and CSF examination revealed a significant reduction in MCL cells. Due to serious complications after the first MATRIX regimen cycle, we continued with only ibrutinib therapy and intrathecal applications (a total of six).

Due to persistence of CSF involvement by MCL cells after one cycle of MATRIX regimen and one month of ibrutinib therapy with another four intrathecal applications, the patient was referred for CAR T-cell therapy with brexucabtagene autoleucel. Mononuclear cell collection was performed in March 2025. The dynamics of CSF involvement by pathological lymphocytes are shown in Fig. 2. Following lymphodepletion with fludarabine and cyclophosphamide, CAR T-cell therapy was administered in April 2025. The patient's hospital stay was complicated by grade I cytokine release syndrome, as defined by the American Society for Transplantation and Cellular Therapy, as well as by prolonged pancytopenia (moderate anemia, severe

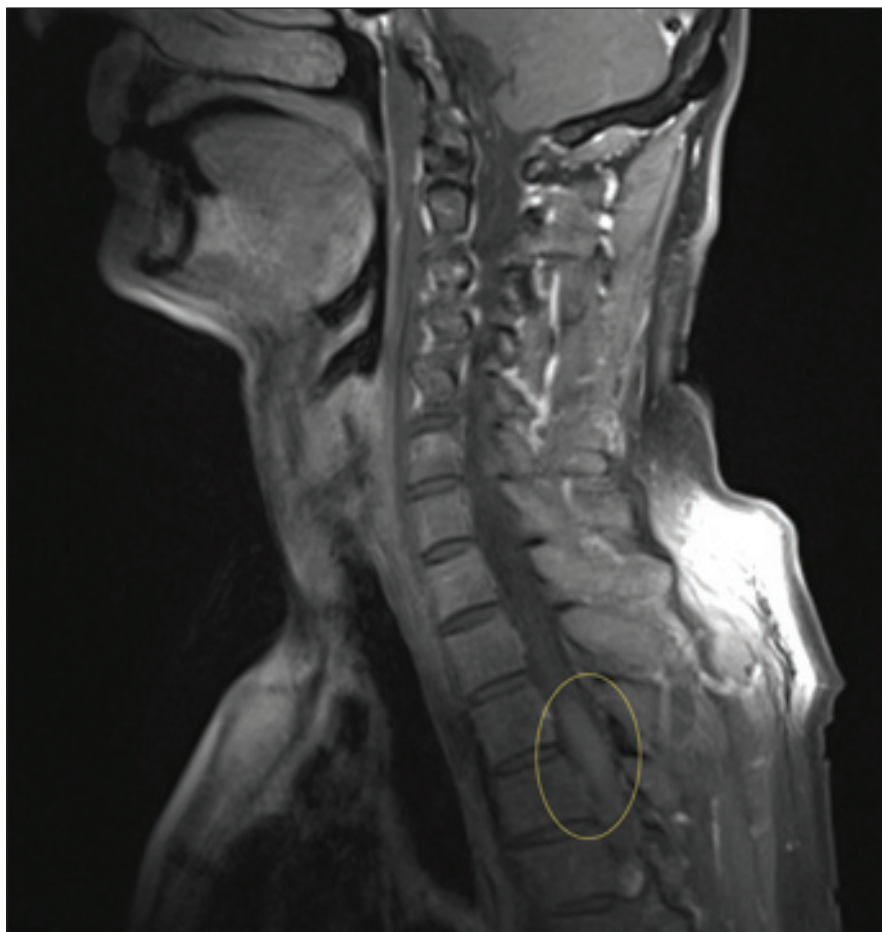

Fig. 1. Thoracic lesion on an MRI scan in November 2024.

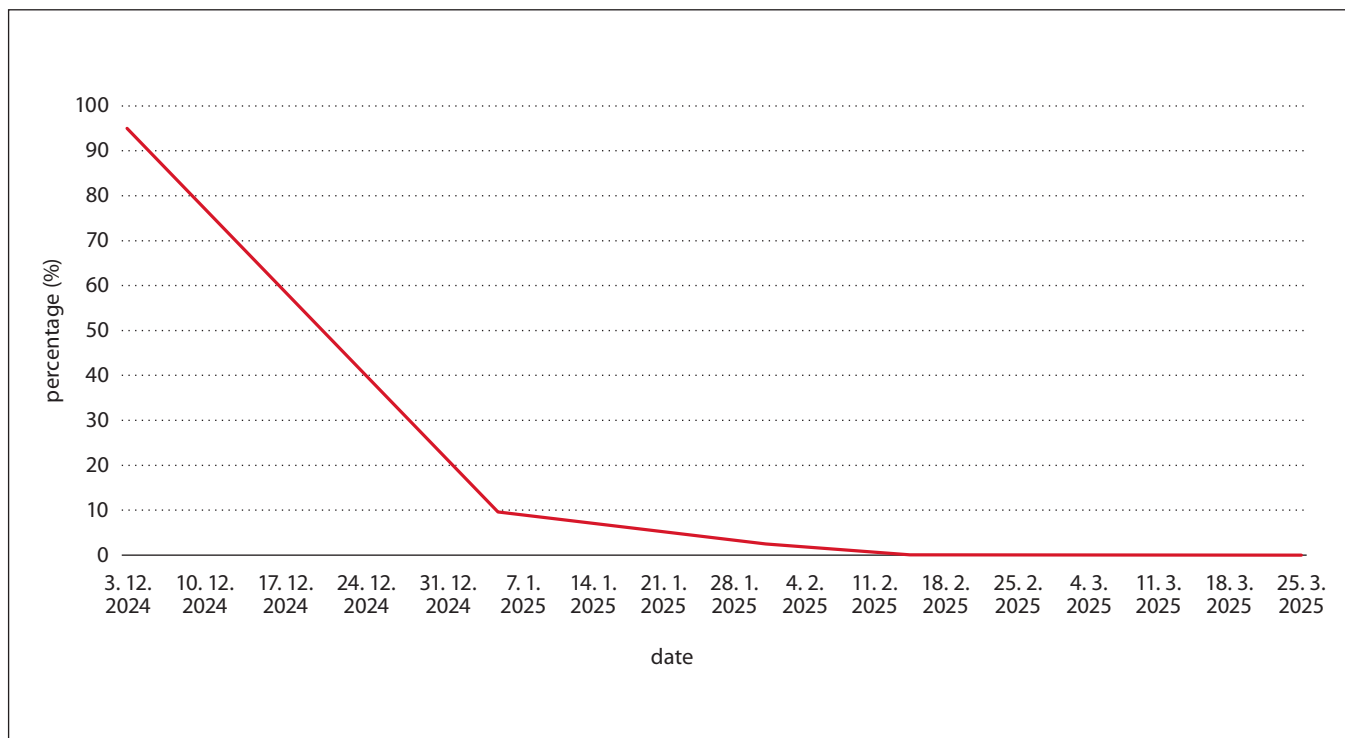


Fig. 2. Mantle cell lymphoma cell counts in the cerebrospinal fluid during the treatment.



**Fig. 3. Our patient three months after CAR T-cell therapy (with his permission).**

thrombocytopenia, and severe neutropenia), meeting the criteria for grade III late immune effector cell-associated haematologic toxicity [15,16]. A follow-up PET/CT scan, lumbar puncture, and bone marrow biopsy three months after CAR T-cell therapy showed no evidence of MCL, although the patient remained severely pancytopenic, with an improved neurological status (Fig. 3). Written informed consent for the publication of the clinical details and images in this case report was obtained from the patient.

## DISCUSSION

Despite advancements in MCL management, the diagnosis and treatment of CNS relapse remain significant clinical challenges. By the time of diagnosis our patient had not been suspected of

having CNS involvement (only an intermediate MIPI score and no high-risk cytomorphology – with the limitation that morphology was only assessed by peripheral blood smear; no specific neurological symptoms), and despite advanced intensive treatment and ASCT, early relapse occurred [5]. Our treatment approach with ibrutinib is based on a published paper by Rusconi et al., in which ibrutinib monotherapy was shown to improve median OS and progression-free survival (PFS) compared with CIT (16.8 vs. 4.4 months and 13.1 vs. 3.0 months, respectively) in MCL patients with CNS infiltration [17]. The combination of CIT and ibrutinib has only been published in a small case series by Tucker et al. (three MCL patients receiving the combination with MTX or AraC) and in a case report by Oh et al. (one MCL patient receiving the combination with a platinum regimen) [18,19]. The use of other Bruton's tyrosine kinase inhibitors in this setting has also been described, for example, in a case report involving acalabrutinib [20]. In our case, we also present the possibility of implanting a ventricular catheter reservoir (Ommaya reservoir) for safety reasons and need for repeated lumbar punctures (for intrathecal chemotherapy and treatment response monitoring) [21]. With a complete response in the spine lesion but still detectable MCL cells in the CSF, our patient required additional anti-lymphoma treatment. The use of CAR T-cell therapy for relapsed MCL with CNS involvement was first reported in 2023 by Wang Y. et al. and subsequently by other groups. These studies showed high overall response rates (75–92%) but relatively short PFS at 12 months, with follow-up still limited [12,22–24]. Another treatment option for our patient could be allogeneic hematopoietic cell transplantation (allo-HCT). However, given the fact that European Society for Blood and Marrow Transplantation registry data comparing CAR T-cell therapy and allo-HCT showed one-year non-relapse mortality of 3.6 % vs. 21.2 % and

one-year OS of 81.3 % vs. 59.2 %, respectively, even in populations without CNS involvement, CAR T-cell therapy was our preferred choice [25].

As novel agents and combination regimens for systemic MCL relapse are being developed, more data are expected for CNS relapses as well. One important remaining question is whether the incidence of CNS relapse will decrease as more patients receive Bruton's tyrosine kinase inhibitors in the first-line setting.

## References

1. Alaggio R, Amador C, Anagnostopoulos I, et al. The 5th edition of the World Health Organization Classification of Haematolymphoid Tumours: Lymphoid Neoplasms. *Leukemia*. 2022;36(7):1720–1748. doi:10.1038/s41375-022-01620-2.
2. Silkenstedt E, Linton K, Dreyling M. Mantle cell lymphoma – advances in molecular biology, prognostication and treatment approaches. *Br J Haematol*. 2021;195(2):162–173. doi:10.1111/bjh.17419.
3. Herrmann A, Hoster E, Zwingers T, et al. Improvement of overall survival in advanced stage mantle cell lymphoma. *J Clin Oncol*. 2009;27(4):511–518. doi:10.1200/JCO.2008.16.8435.
4. Eskelund CW, Kolstad A, Jerkeman M, et al. 15-year follow-up of the Second Nordic Mantle Cell Lymphoma trial (MCL2): prolonged remissions without survival plateau. *Br J Haematol*. 2016;175(3):410–418. doi:10.1111/bjh.14241.
5. Hermine O, Rule S, Forstpointner R, et al. High-dose cytarabine and autologous stem-cell transplantation in mantle cell lymphoma: long-term follow-up of the randomized Mantle Cell Lymphoma Younger trial of the European Mantle Cell Lymphoma Network. *J Clin Oncol*. 2023;41(3):479–484. doi:10.1200/JCO.22.01780.
6. Cheah CY, George A, Gine E, et al. Central nervous system involvement in mantle cell lymphoma: clinical features, prognostic factors and outcomes from the European Mantle Cell Lymphoma Network. *Ann Oncol*. 2013;24(8):2119–2123. doi:10.1093/annonc/mdt139.
7. Trab T, Möller MB, Pedersen MO, et al. Secondary central nervous system lymphoma (SCNSL) in mantle cell lymphoma (MCL): characteristics and risk factors in a Danish nationwide population-based study. *Br J Haematol*. 2025;207(4):1366–1376. doi:10.1111/bjh.70082.
8. McLaughlin N, Gao J, Goyal G, et al. Central nervous system involvement by mantle cell lymphoma. *Leuk Lymphoma*. 2023;64(2):371–377. doi:10.1080/10428194.2022.2148211.
9. Conconi A, Franceschetti S, Lobetti-Bodoni C, et al. Risk factors of central nervous system re-

lapse in mantle cell lymphoma. *Leuk Lymphoma*. 2013;54(9):1908–1914. doi:10.3109/10428194.2013.767454.

10. Alderuccio JP, Nayak L, Cwynarski K. How I treat secondary CNS involvement by aggressive lymphomas. *Blood*. 2023;142(21):1771–1783. doi:10.1182/blood.2023020168.

11. Bernard S, Goldwirt L, Amorim S, et al. Activity of ibrutinib in mantle cell lymphoma patients with central nervous system relapse. *Blood*. 2015;126(14):1695–1698. doi:10.1182/blood-2015-05-647834.

12. Ryan CE, Keane C, Khot A, et al. Clinical efficacy and safety of chimeric antigen receptor T-cell therapy for mantle cell lymphoma with secondary central nervous system involvement. *Br J Haematol*. 2023;203(5):774–780. doi:10.1111/bjh.19037.

13. Cheson BD, Fisher RI, Barrington SF, et al. Recommendations for initial evaluation, staging, and response assessment of Hodgkin and non-Hodgkin lymphoma: the Lugano classification. *J Clin Oncol*. 2014;32(27):3059–3067. doi:10.1200/JCO.2013.54.8800.

14. Common Terminology Criteria for Adverse Events (CTCAE). [Internet]. U.S. Department of Health and Human Services. [Accessed 2025 Oct 7]. Available from: [https://ctep.cancer.gov/protocoldevelopment/electronic\\_applications/ctc.htm](https://ctep.cancer.gov/protocoldevelopment/electronic_applications/ctc.htm)

15. Lee DW, Santomaso BD, Locke FL, et al. ASTCT consensus grading for cytokine release syndrome and neurologic toxicity associated with immune effector cells. *Biol Blood Marrow Transplant*. 2019;25(4):625–638. doi:10.1016/j.bbmt.2018.12.758.

16. Rejeski K, Roddie C, Bachmeier C, et al. Immune effector cell-associated hematotoxicity: EHA/EBMT consensus grading and best practice recommendations. *Blood*. 2023;142(10):865–877. doi:10.1182/blood.2023020578.

17. Rusconi C, Dreyling M, Zucca E, et al. Ibrutinib improves survival compared with chemotherapy in mantle cell lymphoma with central nervous

system relapse. *Blood*. 2022;140(17):1907–1916. doi:10.1182/blood.2022015560.

18. Tucker DL, Naylor G, Kruger A, Hamilton MS, Follows G, Rule SA. Ibrutinib is a safe and effective therapy for systemic mantle cell lymphoma with central nervous system involvement – a multi-centre case series from the United Kingdom. *Br J Haematol*. 2017;178(2):327–329. doi:10.1111/bjh.14122.

19. Oh TS, Burkart M, Behdad A, Savas H, Karmali R. Ibrutinib plus R-ICE induces remission in blastoid variant mantle cell lymphoma with CNS relapse. *Case Rep Hematol*. 2022;2022:1930546. doi:10.1155/2022/1930546.

20. Barrett A, Lowe J, Carroll A, et al. Complete response of mantle cell lymphoma with central nervous system involvement at diagnosis with acalabrutinib: case report. *eJHaem*. 2023;5(1):238–241. doi:10.1002/jha2.830.

21. Peyrl A, Chocholous M, Azizi AA, et al. Safety of Ommaya reservoirs in children with brain tumors: a 20-year experience with 5472 intraventricular drug administrations in 98 patients. *J Neurooncol*. 2014;120(1):139–145. doi:10.1007/s11060-014-1531-1.

22. Wang Y, Jain MD, Xu ML, et al. Brexucabtagene autoleucel for relapsed or refractory mantle cell lymphoma in standard-of-care practice: results from the US Lymphoma CAR T Consortium. *J Clin Oncol*. 2023;41(14):2594–2606. doi:10.1200/JCO.22.01797.

23. Ahmed G, Nastoupil LJ, Jain MD, et al. CAR-T-cell therapy in mantle cell lymphoma with secondary CNS involvement: a multicenter experience. *Blood Adv*. 2024;8(13):3528–3531. doi:10.1182/bloodadvances.2023012255.

24. Wang M, Munoz J, Goy A, et al. Lisocabtagene maraleucel in relapsed/refractory mantle cell lymphoma: primary analysis of the mantle cell lymphoma cohort from TRANSCEND NHL 001, a phase I multicenter seamless design study. *J Clin Oncol*. 2024;42(10):1146–1157. doi:10.1200/JCO.23.02214.

25. Liebers N, Bachmeier C, Bettac L, et al. Brexucabtagene autoleucel versus allogeneic he-

matopoietic cell transplantation in relapsed and refractory mantle cell lymphoma. *Blood Cancer Discov*. 2025;6(3):182–190. doi:10.1158/2643-3230.BCD-24-0178.

## AUTHOR CONTRIBUTIONS

A.H. – main author of manuscript, attending physician

A.O. – major revisions of the manuscript

R.S. – minor revisions of the manuscript, attending physician

T.P. – minor revisions of the manuscript

All authors read and approved the final manuscript.

## CONFLICT OF INTEREST

The authors declared no potential conflicts of interest with respect to authorship and publication of this article.

## ACKNOWLEDGMENT

We would like to thank Mgr. Pavel Kurfürst for language proofreading of the manuscript and constructive comments.

## FUNDING

Supported by IGA\_LF\_2025\_005, MH CZ – DRO (FNOL, 00098892).

*Submitted: October 16, 2025*

*Accepted after peer review:  
November 25, 2025*

*Andrea Hrušková, MD*

*Department of Hemato-Oncology*

*Faculty of Medicine and Dentistry*

*Palacký University Olomouc*

*and University Hospital Olomouc*

*Zdravotníků 248/7*

*779 00 Olomouc*

*e-mail: andrea.hruskova@fnol.cz*