proLékaře.cz | 29.9.2026

Sudden death after a mountain bike race

Michal Kováč[1], Boris Ťažký[1], Štefan Krnáč[2], Lukáš Hamerlik[3], Jozef Šidlo[4]

[1] *Department of Forensic Medicine and Pathology, Health Care Surveillance Authority, Banská Bystrica, Slovak Republic*
[2] *National delegate of Slovak Republic for quality and safety in primary health care EQuiP, EFPC, member of working group of EMA, Slovak Republic*
[3] *Institute of Forensic Medicine and Medical Law, Faculty Hospital Olomouc, Olomouc, Czech Republic*
[4] *Institute of Forensic Medicine, Faculty of Medicine, Comenius University in Bratislava, Bratislava, Slovak Republic*

SUMMARY

Presented case study deals with the sudden death of a 47 years old male, shortly after a mountain bike race after reported nausea and chest pain followed by loss of consciousness and resuscitation. Cardiopulmonary resuscitation was unsuccessful. An autopsy was enacted due to the sudden death in a seemingly healthy person. An acute infarction of the anterior cardiac wall on the basis of stenosis of the anterior interventricular branch of the left coronary artery with histopathological findings of eosinophilic coronary periarteritis was assessed. Sudden death during sport activities represents a complex problem which forensic physicians have to face. An external and internal examination of the body is not always sufficient. It is crucial for the forensic physician to have sufficient knowledge and enough information about the circumstances of the death and anamnestic records. Eosinophilic coronary periarteritis occurs rarely, predominantly in males and with uncertain etiology.

Keywords: sport deaths – cardiac death – eosinophilic coronary periarteritis

Náhle úmrtie športovca po súťaži v horskej cyklistike

SÚHRN

Cieľom predkladanej prípadovej štúdie je analýza úmrtia športovca, ktorý absolvoval preteky v horskej cyklistike, ktorému krátko po pretekoch bolo nevoľno s deklarovanými bolesťami na hrudníku, čo neskôr viedlo k poruche vedomia a k resuscitačnej príhode. Rozšírenou kardiopulmonálnou resuscitáciu sa životné funkcie nepodarilo obnoviť, čo viedlo k smrti. Nakoľko došlo k náhlemu úmrtiu z plného zdravia bolo nariadené prehliadajúcim lekárom vykonanie pitvy. Pitvou a histopatologickým vyšetrením bol zistený akútny infarkt prednej steny na podklade stenózy prednej medzikomorovej vetvy ľavej koronárnej artérie s histopatologickým nálezom eozinofilnej koronárnej periarteritídy. Náhle úmrtie pri športových aktivitách je komplexným problémom, pred ktorým stoja lekári vykonávajúci pitvu. Pre exaktné posúdenie prípadu nestačí len vykonať vonkajšiu a vnútornú prehliadku tela pri pitve, je tiež dôležité, aby súdny lekár mal dostatok znalostí z danej problematiky a mal k dispozícii dostatok informácii o okolnostiach úmrtia, anamnestické údaje ev. kompletnú zdravotnú dokumentáciu. Zistená eozinofilná koronárna periarteritída sa vyskytuje zriedkavo s dominantným výskytom v mužskej populácii, pričom etiológia doposiaľ nie je známa.

Kľúčové slová: úmrtia pri športe – kardiálna smrť – eozinofilná koronárna periarteritída

Soud Lek 2024; 69(2): 23–27

In this article, we will discuss death from morbid causes, as the autopsy and other examinations performed objectified and explained the cause of death in an otherwise healthy person. The authors analyse the death of an athlete who participated in a mountain bike race who collapsed shortly after arriving at the finish line and subsequently died after undergoing protracted, extended cardiopulmonary resuscitation. The range of sudden deaths during sport activities includes cases of sudden cardiac deaths due to functional or structural disorders of the cardiovascular system. An increased physical activity triggers physiological processes leading to adaptation to the given activity and ultimately to the heart, whose basal task is to ensure effective circulation. Such an increased need may accentuate hidden functional or structural defects or changes in the cardiovascular system. It is very difficult for forensic physicians to comment on functional disorders, therefore we will discuss structural changes.

According to prevailing opinions, sudden death is due to a pre-existing cardiovascular anomaly of a structural or functional (often genetic) nature, together with a high degree of physical strain. Excessive production/flow of catecholamines plays a role, as well as other phenomena accompanying physical activity, such as dehydration, electrolyte imbalance and overheating of the body (1).

In over 35-year old's, the cause of death in sports is in a majority of cases unrecognized coronary heart disease, but in under 35-year old's the causes might be diverse. The most common causes of sudden death in young athletes are: hypertrophic cardiomyopathy (one third of cases), arrhythmogenic right ventricular cardiomyopathy (a quarter of cases) (Table 1). About a third of sudden deaths in athletes remain etiologically unclear (2).

✉ ***Correspondence address:***
Michal Kováč, MD.
Department of Forensic Medicine and Pathology
Health Care Surveillance Authority
Nám. L. Svobodu 1
974 01 Banská Bystrica
Slovak Republic
tel.: +421904957833
e-mail: michal.kovac@hotmail.sk

Received: April 4, 2024.
Accepted: May 4, 2024.

CASE REPORT

At the Health Care Surveillance Authority in Banská Bystrica, an autopsy was performed on a 47-year-old man who fainted

proLékaře.cz | 29.9.2026

after completing a mountain bike race with a total length of 22.5 km and an elevation of 700 m. Just after arriving at the finish line, he had some sweet beverage and beer, complained about chest pain. The paramedics medicated him with magnesium 400 mg tablets, which seemed to alleviate the condition a bit.

Subsequently, he lost consciousness, did not breathe, had convulsions. A basic cardiopulmonary resuscitation was provided, later expanded, was intubated, received 1 x discharge from a defibrillator, 9 x intravenously medicated with Adrenaline and 2 x Atropine, resuscitated for 45 minutes with an unsuccessful end. According to the examination report, the examining doctor stated, based on available information, that he had not been treated for anything, had not taken medication and was an active athlete. An autopsy was performed within two days after death.

MATERIAL AND METHODS

We studied a sudden death case of an athlete shortly after a mountain bike race. The autopsy was performed in accordance with forensic autopsy performance standards, including external and internal examinations. At autopsy, the heart was fixed in a 10% formalin solution, and after prefixing, the myocardium and coronary arteries were extensively cut, dehydrated with alcohol and drenched in paraffin. The paraffin cuts were stained with haematoxylin – eosin, Congo – red and staining for evidence of trivalent iron. The myocardium was examined macroscopically and microscopically, the same approach was applied for other organs. In this case, medical records were requested upon application.

RESULTS

According to the obtained anamnestic records, more information regarding the health status could be found. The deceased male was an ex-smoker for 18 years, with occasional alcohol consumption, no drug user. He worked as a coordinator for high-altitude work and the forklift, worked at gas facilities, in the past as an assistant carpenter and also worked nightshifts. Family history not significant. In 2002, he was involved in a car accident with some injuries of the facial area with superficial abrasions of the skin and a fracture of the sixth rib on the right. Later, he reported severe headaches with nausea, he reported pain of the right half of the head radiating to the right ear area. He was diagnosed with cervicocranial syndrome.

He underwent an appendectomy for phlegmonous appendicitis with circumscribed peritonitis in 2017. The last time he reported a stinging pain in the left *inguen*, the condition after *halux valgus* surgery on the left foot. The results of the blood test: 10/2021 – total cholesterol 5.3 mmol/l, cholesterol LDL-S 3.3 mmol/l, cholesterol HDL-S 1.59 mmol/l, triacylglycerol-S 0.96 mmol/l. Antibodies against Ch. pneumoniae – borderline (2, 4/2017), negative (4/2019), antibodies against M. pneumoniae – negative (4/2019), antibodies against B. pertussis – negative (4/2019), throat swab (4/2019, 4/2017, 2/2017, 11/2012) finding Alpha haemolytic Streptococci had previously tested positive from an oral swab, Neisseria spp. (4/2019). Rectal bleeding (10/2019), anti CMV IgM negative, IgG ELISA borderline (4/2017), anti EBV EBNA IgM negative.

The last ECG revealed changes in the nature of the incomplete block of the right Tawar branch (10/2021), ECG 9/2014 without abnormalities, positive IgA for B. pertussis (2/2017) with antibiotic therapy (3/2017), at the last checkup he had an elevated LDL-S level of 3.3 mmol/l.

The external and internal examination of the body revealed: acute myocardial infarction of the anterior wall of the left ventricle of the heart (Fig. 1), stenosis of the anterior interventricular branch of the left coronary artery above 75% with fibrolipomatous streak in the area of narrowing (Fig. 2), double conveyance of the right coronary artery, hypoplastic peripheral branches of the *ramus interventricularis anterior*, excentric hypertrophy of the heart (weight 423 g) with dilated right atrium and insufficiency of the tricuspid valve (circumference 13.5 cm) (Fig. 3), dispersive myofibrosis of the left ventricle of the heart, acute haemorrhagic swelling of the lungs (right lung weighing 795 g, left lung 610 g), passive hyperemia of the abdominal organs, cavernous haemangioma of the left liver lobe.

Condition after the cardio-pulmonary resuscitation: typical serial bilateral rib fractures with blood sprains into the surrounding region (pleura still intact), inserted cannula in the oral cavity (no contents), superficial abrasions of the skin in the sternal area, typically located defibrillator stickers, needle punctures in the elbow pits with bruising around the puncture, inserted intravenous coil in the back of the right hand.

Injuries: bruising without skin injuries in the area of the anterior surface of the left shoulder joint, abrasion of the skin of the posterior surface of the left elbow joint, bruising without skin injuries on the dorsal surface of the left hand, superficial abrasion of the skin of the right tibia. An old striped scar on the inner-front surface of the left knee, skin tattoo in the area of the right shoulder blade.

The histopathological examination revealed: extensive examination of the heart muscle in the region of the right and left ventricle revealed corrugation of cardiomyocytes, over leaked interstitium, leucostasis (Fig. 4), contraction streaks across the cardiomyocytes (Fig. 5), eosinophilic coloration of cardiomyocytes with diffuse ischemic changes with a picture of acute myocardial infarction with partial overlap of the anterior part of the interventricular septum and into the lateral wall of the left

Table 1. Causes of sudden death in athletes under 35 years of age (6).

Structural heart disease	Hypertrophic cardiomyopathy
	Arrhytmogenic dysplasia of the right ventricle
	Dilated cardiomyopathy
	Myocarditis
	Congenital anomalies of the coronary arteries or early atherosclerosis
	Aortic stenosis
	Mitral valve prolaps
	Aortic rupture (Marfan syndrome)
	Congenital heart defects not treated or operated on
Cardiac arrhythmia and electrical abnormalities of the heart	Wolff-Parkinson-White syndrome
	Long QT syndrome (LQTS)
	Short QT syndrome (SQTS)
	Catecholaminergic ventricular tachycardia, premature repolarisation syndrome/idiopathic ventricular fibrillation
	Conduction disorders of cardiac impulses
Other causes	Prohibited substances
	Electrolyte imbalance
	Blunt chest trauma (*commotio cordis*)

proLékaře.cz | 29.9.2026

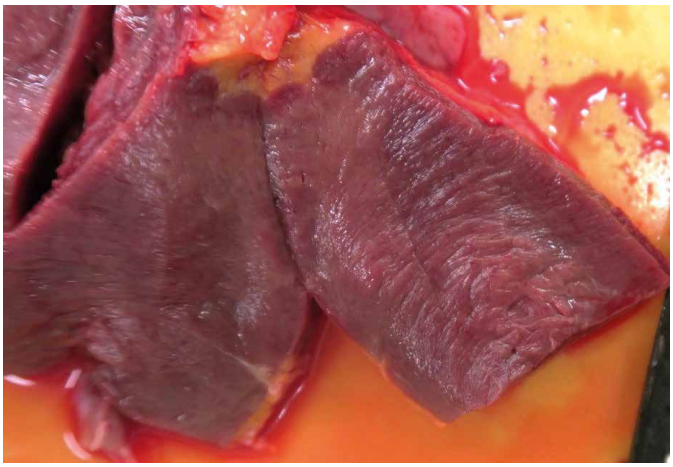

Figure 1. Gross section through the anterior wall of the left heart ventricle.

Figure 2. Lining of the anterior interventricular branch of the left coronary artery.

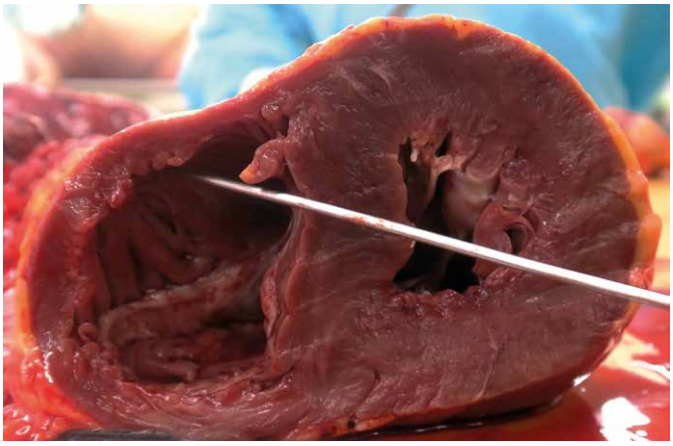

Figure 3. Transverse section through the heart ventricles.

ventricle of the heart. Staining of trivalent iron – negative, staining with congo-red – negative (excluded amyloid angiopathy), anterior wall of the right heart ventricle – perivascular fibrosis, arteriolosclerosis, irregular fibers of hypertrophic myocardium from the anteroseptal region (Fig. 6). Fibroblastic changes of the anterior interventricular branch of the left coronary artery, predominantly fibrosis with mixed inflammatory cellulization with a high number of eosinophils limited to the adventitia, and the periadventitial soft tissue, so-called eosinophilic coronary periarteritis (Fig. 7,8). Examination of samples of both lung lobes – haemorrhagic swelling of the lungs, chronic bronchitis, acute emphysema after cardiopulmocerebral resuscitation. Pancreas – ductular hyperplasia, periductal fibrosis, autolyzed tissue. Kidneys – nephrosclerosis with hyalinized glomeruli. Brain – diffuse swelling.

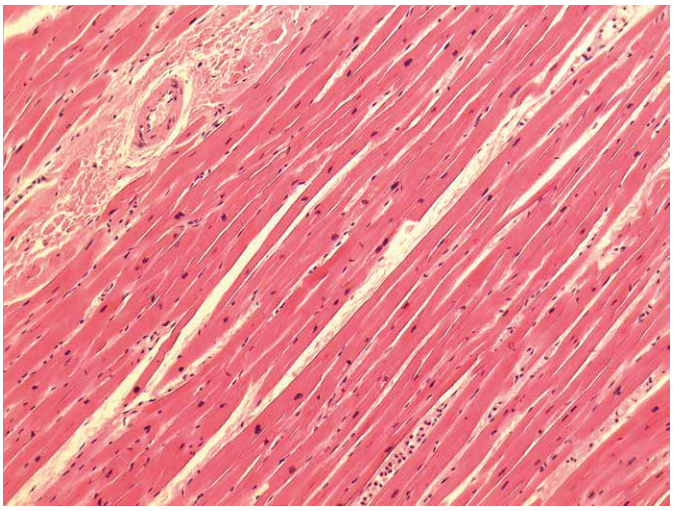

Figure 4. Microscopic image of the anterior wall of the left heart ventricle – infiltrate of neutrophils (HE, 200x).

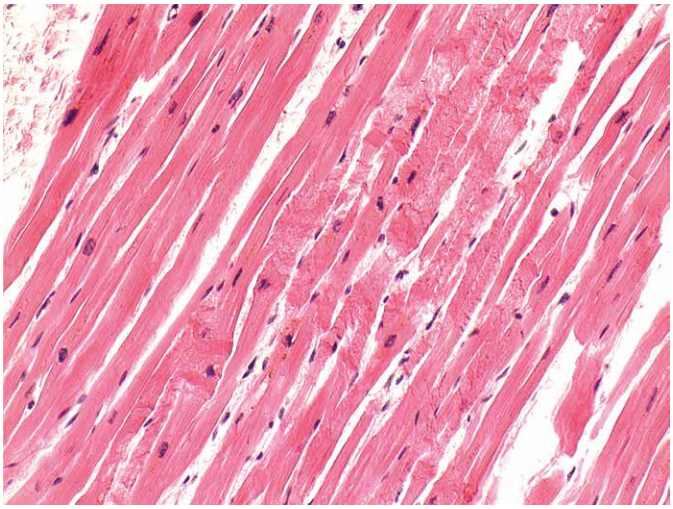

Figure 5. Microscopic image of the heart muscle from the anterior wall of the left heart ventricle, containing contraction stripes (HE, 200x).

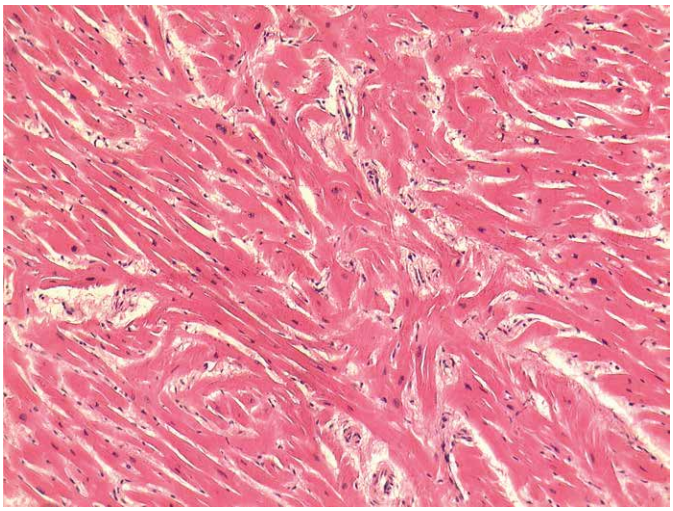

Figure 6. Irregular fibers of the hypertrophic myocardium (HE, 100x).

The toxicological examination using thin-layer chromatography – after processing the biological material (blood – 40 g, urine – 30 ml) during the screening for drugs, narcotic and

proLékaře.cz | 29.9.2026

psychotropic substances and other toxicologically important substances proved negative.

Gas chromatography blood and urine alcohol tests were negative. Immunochromatographic screening for drugs and drugs in blood and serum MULTI 5 – negative. Immunochromatographic screening of drugs and drugs in urine – MULTI 10 – negative.

The immediate cause of death of the 47-year-old man was acute myocardial infarction of the anterior wall of the left heart ventricle with narrowing of the anterior interventricular branch of the left ventricle of the heart with atherosclerotic changes and eosinophilic coronary periarteritis. In this case, it is death from morbid causes.

DISCUSSION

In the above presented case report of a sudden death of an athlete, the diseases of the cardiovascular system played a major role, therefore it is important that professional athletes take regular medical checkups, to an extent which is defined by the Sports Act. According to the act they are obliged to undergo a checkup once a year in order to assess their medical fitness.

In the above described case report, an isolated eosinophilic periarteritis of the anterior interventricular branch of the left coronary artery was detected in the area of the narrowing of the vessel's lumen by more than 75% with fibrolipomatous plaques present, which severely narrowed the translucency of the vessel and led to insufficient blood supply to the myocardium, which manifested only after an increased physical activity.

The etiology and pathogenesis of primary vasculitis is not well understood yet. Primary vasculitis is usually a systemic disease. The classification of primary vasculitis is in general based on the type and size of the affected vessels and the composition of the infiltrating inflammatory cells.

According to the American College of Rheumathology and the Chapel Hill International Consensus Conference, different sized vessels are affected by different types of primary vasculitis: a) large vessels are affected by giant cellular (temporal) arteritis and Takayasu's arteritis; (b) medium-sized blood vessels are affected in polyarthritis nodosa (PAN) and Kawasaki disease (KD); (c) vasculitis of small vessels includes allergic granulomatous angiitis (AGA) or Churg-Strauss syndrome, Wegener's granulomatosis, microscopic polyangitis, Hennoch-Schonlein purpura, essential cryoglobulin vasculitis and cutaneous leukocytoclastic angiitis.

In 1989, an autopsy was documented in which medium size arteries were affected with eosinophilic inflammation limited to the adventitia and periadvential soft tissue of the epicardial coronary artery and was called eosinophilic coronary periarteritis.

Eosinophilic coronary arteritis is not systemic and is histologically different from polyarteritis nodosa (PAN), Kawasaki disease (KD) and allergic granulomatous angiitis (AGA). Both PAN and AGA are systemic types of vasculitis and histologically show necrotizing pan-arteritis or pan-vasculitis involving the intima, media and adventitia with fibrinoid necrosis, while isolated eosinophilic coronary periarteritis (IECPA) presents localized eosinophilic periarterial inflammation without fibrinoid necrosis, in addition, eosinophilic inflammation is limited to adventitia and periadventitial soft tissue, many times this inflammation is observed with spontaneous coronary dissection of arteries (7).

The most common causes of death in athletes under 35 are structural heart diseases (Table 1). Hypertrophic cardiomyopathy is a disease of the heart due to mutations in genes encoding contractile proteins, with autosomal dominant inheritance.

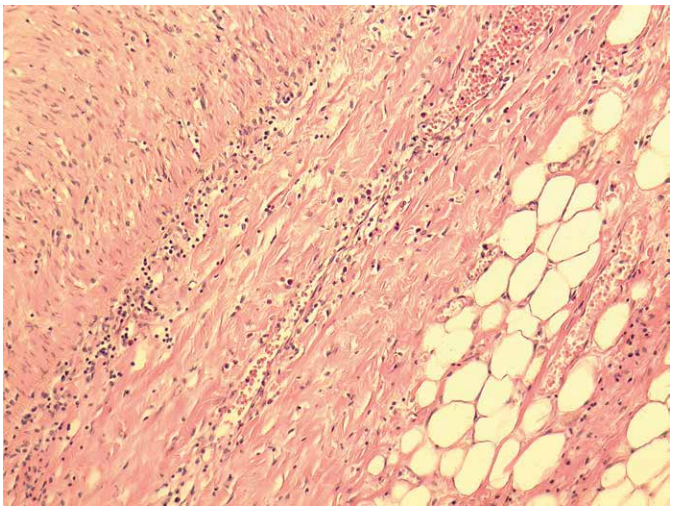

Figure 7. Histopathological finding at the anterior interventricular branch of the left coronary artery, with eosinophil infiltration in adventitia and periadventitial soft tissue (HE, 100x).

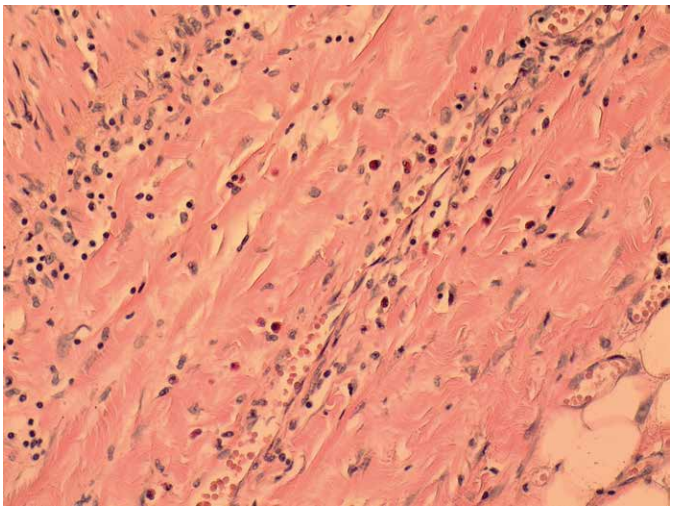

Figure 8. Detail histopathological finding at the anterior interventricular branch of the left coronary artery, with eosinophil infiltration in adventitia and periadventitial soft tissue (HE, 200x).

A common finding is left ventricular hypertrophy, which arose during the absence of excessive stress on the heart muscle. The histological picture is characterized by a chaotic arrangement of muscle cells. Sudden death is caused by ventricular tachycardia or fibrillation and occurs more often in dynamic sports (football, basketball) than in endurance sports (long-distance running, cycling).

This is probably due to the fact that subjects, due to the inability to increase cardiac output in the long term, do not perform well in endurance sports and therefore do not engage in them. More than 90% of people have an abnormal electrocardiograph (ECG), which, along with echocardiography, is the basis for diagnosis.

Typical ECG findings are voltage signs of left chamber hypertrophy, the presence of Q waves and negative T waves. In patients who are at high risk of death, a prophylactic implantation of a cardioverter defibrillator is required. Among risk factors are a positive family history of sudden death, syncope in history, significant muscle hypertrophy, significant pressure gradient in the left chamber outlet, dilated left atrium and ventricular tachycardia (3).

proLékaře.cz | 29.9.2026

People with hypertrophic cardiomyopathy and at high risk of sudden death cannot participate in performance sports even after the implantation of a cardioverter defibrillator. At autopsy the finding is significant hypertrophy of the heart muscle with reduced ventricular cavities, the left is usually more affected than the right.

The atria are also dilated and often hypertrophic, usually regurgitation occurs through the atrioventricular valves. A typical finding is a disproportionate involvement of the intraventricular septum and anterior wall when compared to the posterior wall of the left ventricle. In some cases, hypertrophy can occur even in completely atypical segments of the ventricle (4).

Histologically, in myocardial hypertrophy, a large disorganization of muscle fibres and myofibrillar architecture in cells can be seen. Predominantly, fibrosis can be found, forming visible scars. Areas of the disorganized zone interlace the hypertrophic muscle and otherwise normal cells. There is also an increased presence of interstitial connective tissue. The zones of disorganization affect approximately 5 or more percent of the myocardium. In more than 80% of patients, there is an abnormal finding in intramural coronary arteries with reduction of the lumen and thickening of the walls, found in intraventricular septal tissue (4).

Coarctation of the aorta is a common extracardiac congenital defect of the heart, characterized by a substantial narrowing of the aorta. It accounts for about 10% of all congenital heart defects. In boys, it occurs 2 times more often than in girls, it is the most common comorbidity in Turner syndrome. The narrowing of the isthmic part of the aorta occurs most often at the site of the tendrils of the ductus arteriosus.

Narrowing of the aorta to less than 40% of its physiological translucency is considered tight, with a lesser narrowing as mild aortic coarctation. The localization of aortic coarctation is, except for rare cases, in the aortic isthmus and, according to the relationship to the arterial duct or its ligament, is classified as preductal (infantile) and postductal (adult).

Infantile types tend to be more malignant, manifest quickly after birth and are more often associated with other congenital heart defects, what is often referred to as coarctation syndrome. The adult type occurs rarely, often detected accidentally during an examination for systemic hypertension. The survival time after surgery decreases significantly compared to the normal population (mainly those operated on after their 40ties) (4).

Wolf-Parkinson-White syndrome – ventricular preexcitation syndrome, is the most common syndrome of ventricular preexcitation. It is a cardiac arrhythmia in which there is a spread of impulse (waves of depolarization) from the atrium to the ventricles outside the AV node. The accessory path is formed by the so-called Kent's bundle (a pathological junction between the atria and ventricles).

The abnormal connection of ventricles to the atria (Kent's bundle) may be associated with other arrhythmias. Most often it is a paroxysmal supraventricular tachycardia, less often a permanent supraventricular tachycardia, rarely a ventricular tachycardia. Very rarely, WPW syndrome can result in ventricular fibrillation and sudden cardiac death.

According to prevailing opinions, sudden death is due to a pre-existing cardiovascular anomaly of a structural or functional (often genetic) nature, together with a high degree of physical exertion. Excessive leaching of catecholamines plays a role, but also by accompanying phenomena of physical activity, such as dehydration, electrolyte imbalance and overheating.

While in over 35-year old's the cause of death in sports is mostly unrecognized coronary heart disease, in adults under 35 years of age the causes are diverse (Table 1). The most common cause of sudden death in the subpopulation of young athletes is hypertrophic cardiomyopathy (one third of cases), arrhythmogenic cardiomyopathy of the right ventricle (a quarter of cases). About a third of sudden deaths in athletes remain etiologically unclear (2).

However, we should not forget the positive effects of sports and an active life style. People with regular physical activity live on average 7 years longer compared to individuals who do not participate in sport activities (5).

CONCLUSION

The issue of sudden death in sport is an integral and extremely important part of the field of forensic medicine, it is always actual and still demanding a multidisciplinary approach. The challenge for forensic medical centres lies in detecting supportive and prohibited substances, as the chances of detecting some substances are very limited to almost impossible due to the lab´s equipment.

Another question the forensic physicians has to answer, is the relationship (correlation) between influence by a foreign substance (changes due to substance use) and a morphologically detectable pathological process on the body of the deceased (changes due to underlying pathology).

CONFLICT OF INTEREST

The authors declare that there is no conflict of interest regarding the publication of this paper.

REFERENCES

1. **Mitro P.** Náhla srdcová smrť u mladých ľudí a športovcov. *Via pract* 2018; 15(2): 85-89.
2. **Chandra N, Bastiaenen R, Papadakis M, Sharma S.** Sudden cardiac death in young athletes: practical challenges and diagnostic dilemmas. *J Am Coll Cardiol* 2013; 61(10): 1027-1040.
3. **Elliott PM, Anastasakis A, Borger MA, Borggrefe M, et al.** Guidelines on diagnosis and management of hypertrophic cardiomyopathy: The Task Force for the Diagnosis and Management of Hypertrophic Cardiomyopathy of the European Society of Cardiology (ESC). *Eur Heart J* 2014; 35: 2733-2779.
4. **Ďuriš I, Hulín I, Bernadič M, et al.** Princípy internej medicíny. 1. vyd. Bratislava: SAP; 2001: 2951 s.
5. **Corrado D, Basso C, Rizzoli G, Schiavon M, Thiene G.** Does sports activity enhance the risk of sudden death in adolescents and young adults? *J Am Coll Cardiol* 2003; 42(11): 1959-1963.
6. **Šteiner I.** Kardiopatologie. 1. vyd. Praha: Galen; 2010: 97–98.
7. **Kajihara H, Tachiyama Y, Hirose T, et al.** Eosinophilic coronary periarteritis (vasospastic angina and sudden death), a new type of coronary arteritis: report of seven autopsy cases and a review of the literature. *Virchows Arch* 2013; 462: 239-248.