proLékaře.cz | 28.9.2026

The utility of sternum in creating a biological profile: A review and future directions

Katarína Hanzelyová, Filip Babiak, Ján Bajaj, Martin Janík, Ľubomír Straka

Ústav súdneho lekárstva a medicínskych expertíz, Jesseniova Lekárska Fakulta Univerzity Komenského, Martin

SUMMARY

This review delves into the forensic utility of the sternum in creating a biological profile, focusing on sex, stature, and age estimation. Emphasizing the sternum's significance in challenging scenarios, the study supports the combined length of the manubrium and sternal body as a crucial indicator in sex and stature estimation. However, it highlights the need for caution in applying findings across diverse populations and questions the reliability of Hyrtl's law. Age estimation, primarily based on morphological changes and ossification ages, is explored, with one study showing promise but requiring further validation. While acknowledging the sternum's advantages, the review underscores potential limitations and the absence of specific studies on ancestry estimation, leaving this aspect open for future research. In conclusion, the review provides a comprehensive overview of the sternum's forensic applications, urging continued research to enhance accuracy and applicability.

Keywords: sternum – sex estimation – stature estimation – age estimation – biological profile

Využitie hrudnej kosti pri vytváraní biologického profile: prehľadový článok

SÚHRN

Tento prehľadový článok sa zameriava na forenzný význam hrudnej kosti pri tvorbe biologického profilu, so zameraním na odhad pohlavia, telesnej výšky a veku. Jedným z významných zistení je výrazný prínos hrudnej kosti v situáciách, keď sa na mieste činu nájde nekompletná kostra. Poskytuje alternatívne nástroje pre pozitívnu identifikáciu jedinca. Významným rozmerom pri odhade telesnej výšky a pohlavie je práve kombinovaná dĺžka manubria a hrudného tela. Zdôrazňuje však potrebu opatrnosti pri uplatňovaní zistení v rôznych populáciách a spochybňuje spoľahlivosť Hyrtlovho zákona. Odhad veku je primárne založený na morfologických zmenách a osifikácii kostí avšak jedna štúdia, predkladá potenciálnu metódu na odhad veku ale vyžaduje ďalšie overenie. Aj keď sú výhody použitia hrudnej kosti zjavné, prehľad zdôrazňuje potenciálne obmedzenia a absenciu špecifických štúdií o odhade etnickej príslušnosti, čo ponecháva tento aspekt otvorený pre budúci výskum. Na záver, prehľad poskytuje komplexný prehľad forenzných aplikácií hrudnej kosti, čo nabáda k pokračujúcemu výskumu na zvýšenie presnosti a použiteľnosti v praxi.

Kľúčové slová: hrudná kosť – odhad pohlavia – odhad telesnej výšky – odhadu veku – biologický profil

Soud Lek 2024; 69(1): 6–9

One of the primary objectives of the anthropological assessment of the skeletal remains is the positive identification of individuals, a task that becomes challenging when dealing with incomplete skeletons. A precise biological profile, including the assessment of stature, biological sex, age at death, and ethnicity is essential for accurate identification. Understanding these components aids forensic anthropologists and contributes crucial information to criminal investigations and medico-legal contexts. The biological profile frequently contains information unique to each individual. Anthropological techniques commonly employed in the reconstruction of biological profiles might rely on either qualitative or quantitative morphoscopic observations, linked to descriptions obtained from morphometric data within the study sample (1-3).

Given that the entire skeleton is not always recovered at crime scenes, the examination of various bones and their characteristics becomes crucial for creating a comprehensive biological profile (4). As forensic techniques continue to advance, researchers and practitioners seek reliable skeletal indicators for accurate biological profiling.

In cases of intentional mutilation or dismemberment, the sternum can be found intact, given its relatively protected position in the body (5). Comprising the manubrium, body, and xiphoid process, the sternum is significant in estimating individual components of the biological profile (6). Numerous studies are devoted to the estimation of biological sex (7-9), stature (5,10,11,12), or age at death (8,13,14). This review aims to comprehensively explore the utilization of the sternum in biological profiling. Our exploration encompasses an array of databases, meticulously selected to encapsulate studies presenting both affirmative and critical perspectives on the utility of sternum-based estimations. By synthesizing findings primarily within the last 15 years, we aim to provide an up-to-date and nuanced understanding of the sternum's role in forensic anthropology. The inclusion criteria encompass forensic studies conducted in the last 15 years that specifically explore the sternum's role in estimating the biological profile components of sex, stature, age, and ancestry. Exclusion criteria involve non-forensic contexts, studies lacking empirical data, non-English publications, and those published more than 15 years ago, ensuring a focused and recent examination of sternum-related forensic research.

SEX ESTIMATION

Numerous studies have examined the utility of the sternum as a sex discriminator (7- 9). When identifying bone remnants,

✉ ***Correspondence address:***
RNDr. Filip Babiak
Ústav súdneho lekárstva a medicínskych ecpertíz JLF UK
Kollárova 10, 036 01 Martin
tel.: +421948727677
e-mail: filip.babiak@gmail.com

Received: December 19, 2023
Accepted: January 30, 2024

proLékaře.cz | 28.9.2026

obtaining precise reference values is crucial, given the variations in sternum measurements across populations and the skeleton (15). Accurate evaluation of specific sternal morphology becomes critical when differentiating between male and female. We examine these crucial metrics and their applicability to sex estimation in this section.

Key measurements encompass the following (15,16):

1. The length of the manubrium: the distance from the jugular notch to the mesoxiphoidal junction from the anterior prospect.
2. The length of the sternal body: the distance from manubriosternal to mesoxiphoidal junction from the anterior aspect.
3. Combined length of the manubrium and sternal body: the sum of the manubrium and sternal body lengths.
4. Total sternal length: the distance from the jugular notch to the apex of xiphoid process.
5. Width of the manubrium: the distance between the left and right first sternebra.
6. Width of the sternal body at the third sternebra: the direct distance between the left and right third sternebra.
7. Width of the sternal body at the fifth sternebra: the direct distance between the left and right fifth sternebra.
8. Sternal index: the length of the manubrium divided be the length of sternal body, multiplied by 100.

Consensus emerges from multiple studies (15-18) conducted across diverse populations, affirming that the most accurate sex estimation results are attained through the combined lengths of the manubrium and the sternal body. Employing discriminant analysis or devising simple regression formulas, the mentioned studies consistently yielded accuracy rates ranging between 84.5% and 86.1% (15-18).

In sex estimation from the sternum, sexual dimorphism has been taken into account, especially when using Hyrtl's law (19). According to Hyrtl's law, a female sternum's manubrium length must be greater than half of the sternal body's length, whereas a male sternal body must be at least twice as long as the manubrium (19- 21). However, some of the studies conducted on different populations did not confirm the accuracy of this law (7,22,23). Consequently, it is not recommended to rely on it for sex estimation in populations that were already studied. Further research is necessary to determine the reliability of Hyrtl's Law in other populations.

In the context of sex estimation using sternum measurements, it's crucial to acknowledge that population-specific variations in sternum morphology exist, emphasizing the importance of caution when generalizing findings from one population to another. Further research across diverse populations is essential to establish the role of sternum measurements in sex estimation with greater certainty.

STATURE ESTIMATION

Stature is a valuable piece of biological profile information, that may provide a valuable clue of the personal identification process. The sternum emerges as a valuable tool in stature estimation from skeletal remains. While the most accurate estimates often rely on long bone measurements, situations arise where intact long bones are absent at the site. In such cases, exploring alternative bones becomes imperative to provide relatively accurate estimations of stature (24). In challenging scenarios where only the thorax is recovered, the stature estimation of skeletal remains becomes a critical consideration, highlighting the unique value of the sternum. This is particularly pertinent in cases involving fresh or partially decomposed mutilated human remains, where the sternum's ease of removal and dissection, even in the presence of significant soft tissue, offers an invaluable alternative for accurate stature estimation (5).

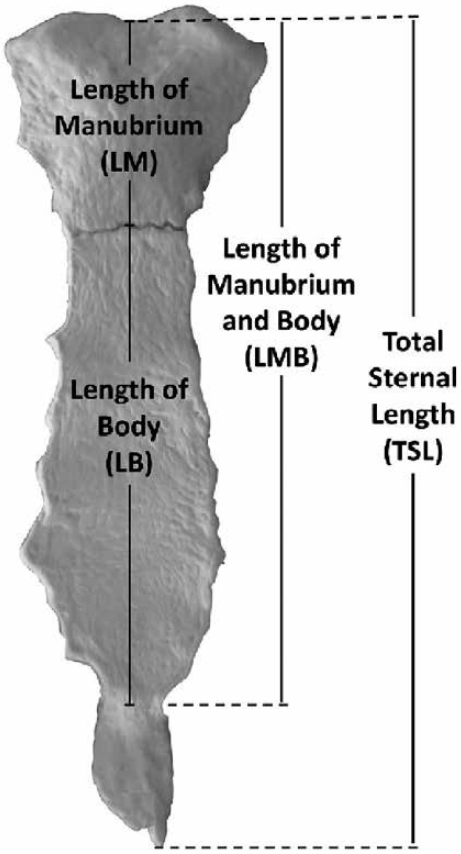

Fig. 1. Length measurements of sternum.

Multiple studies explored the correlation between the sternum and stature (5, 24-26). The common result was that there is a significant correlation between the length and width measurements and adult stature (5, 24-26). Measurements needed for stature estimation are the length of the manubrium, the length of the sternal body, the combined length of the manubrium and sternal body (27; fig. 1). Other measurements that might prove helpful are the width of the sternal body at the third and fifth sternabrae (24,27). Across studies, a common and noteworthy result emerges — the combined length of the manubrium and sternal body stands out as the most influential measurement in stature estimation (5, 24-26).

While the sternum proves valuable in stature estimation when long bones are absent, it is crucial to acknowledge potential limitations, such as variations across populations and challenges in standardization. Another consideration is the slight difference between the stature of living individuals and that of cadavers due to the compression of soft tissues in standing persons (27,28). Despite these challenges, the unique advantages of sternum-based stature estimation, particularly in cases involving fresh or partially decomposed remains, underscore its significance in forensic practice. Comparisons with other established methods may further elucidate both the strengths and limitations of this approach. Future research should delve into these nuances, exploring the reliability of stature estimation using the sternum across diverse populations.

AGE ESTIMATION

The age at death represents the third component of a biological profile. Long bones, the cranium, and pelvis are crucial in

proLékaře.cz | 28.9.2026

determining the age of an adult, while tooth eruption holds significance in assessing a child's age. Considering secular changes, which are alterations in skeletal traits distinguishing one population from another, is vital in age estimation techniques (21,29). Forensic professionals often resort to less sexually dimorphic skeletal features, such as the sternum, for age estimation, leading to valuable insights derived from dedicated research on the sternum (29).

Most of the methods developed for age-at-death estimation from the sternum are based on its morphological changes. Notably, the xiphoid process ossifies with the sternal body around the age of 40, and the manubrium ossifies with the sternal body around the age of 60 (21,30). Most of the studies primarily investigating the accuracy of age estimation based on the fusion of the mentioned joints reached a consistent conclusion. Ossification ages differ between females and males, and while general ossification age ranges are understood, adherence to these ranges is not universal. Whether in the context of morphological evaluation of skeletal remains or through advanced imaging techniques like CT or MRI, the sternum is not the optimal age indicator (14,21,29-31).

The study created by Vera et al. (32) on growth-related evolution of the manubrium in living adolescents and young adults using MRI provides valuable insights into the potential use of manubrium features for age estimation in male group aged 13 to 25 years. The study found statistically significant changes in manubrium volume and surface area, and the predictive model which includes shape, surface area, and subject height produced the lowest median age estimation error of 1.18 years. However, the standard error of estimate for this model was larger than two years, indicating that further research is needed to improve the accuracy of age estimation using this method. Additionally, the study was conducted on a specific population of male adolescents and young adults, and further research among different groups is necessary to validate the generalizability of the findings. Therefore, while this study provides a promising option for age estimation from the sternum, further research is needed to fully establish its accuracy and applicability across different populations (32,33).

ANCESTRY ESTIMATION

Ancestry constitutes the fourth component of the biological profile, typically assessed through cranial morphology and postcranial elements. While extensive research has been conducted on ancestry estimation, it's noteworthy that there is currently limited specific exploration into the use of the sternum for ancestry estimation. The sternum, as a postcranial element, has not been the primary focus of studies in this context. Consequently, further research is required to investigate the potential of the sternum as a reliable indicator for ancestry estimation in forensic anthropology (34).

CONCLUSION AND FUTURE DIRECTIONS

In conclusion, this review delves into the role of the sternum in forensic anthropology, focusing on its utility in sex estimation, stature estimation, and age estimation. The sternum emerges as a valuable tool in forensic investigations, particularly when dealing with incomplete or challenging skeletal remains. While numerous studies affirm its efficacy in sex and stature estimation, additional research is crucial to establishing standardized methods and enhancing accuracy, especially across diverse populations. Additionally, the review highlights the relatively unexplored realms of ancestry estimation from the sternum. As forensic techniques continue to evolve, the sternum's unique advantages in certain scenarios underscore its significance in contributing to a more accurate and comprehensive biological profile for positive identification in medico-legal contexts. As part of our commitment to advancing forensic anthropology, we are currently engaged in research focused on estimating the biological profile from fresh sternum. Our research involves meticulous measurements of key parameters mentioned in this review, aiming to create specific regression formulas tailored to the Slovak population. By conducting this in-depth research, we aim to contribute to the growing body of knowledge in forensic anthropology, providing insights that could enhance the accuracy and applicability of sternum-based estimations. Looking ahead, we anticipate that our ongoing research, along with collaborative efforts in the field, will pave the way for further advancements in forensic applications, offering valuable tools for positive identification in diverse populations.

CONFLICT OF INTEREST

The authors declare that there is no conflict of interest regarding the publication of this paper.

REFERENCES

1. **Franklin D, Blau S.** Physical and virtual sources of biological data in forensic anthropology: Considerations relative to practitioner and/or judicial requirements. In: **Obertová Z, Stewart A, Cattaneo C,** *eds*. Statistics and Probability in Forensic Anthropology. London, San Diego, Cambridge, Oxford: Academic Press; 2020: 17-45
2. **Austin D, King RE.** The Biological Profile of Unidentified Human Remains in a Forensic Context. *Acad Forensic Pathol* 2016; 6(3): 370-390.
3. **Krishan K, Kanchan T, Menezes RG, Ghosh A**. Forensic anthropology casework – essential methodological considerations in stature estimation. *J Forensic Nurs* 2012; 8(1): 45-50.
4. **İşcan MY, Steyn M, Krogman WM.** The Human Skeleton in Forensic Medicine. Springfield, Illinois, U.S.A Charles C Thomas Publisher; 2013: 189–243
5. **Marinho L, Almeida D, Santos A, Cardoso HFV.** Is the length of the sternum reliable for estimating adult stature? A pilot study using fresh sterna and a test of two methods using dry sterna. *Forensic Sci Int* 2012; 220(1): 292.e1-292.e4.
6. **Verna E, Piercecchi-Marti MD, Chaumoitre K, Bartoli C, Leonetti G, Adalian P.** Discrete Traits of the Sternum and Ribs: A Useful Contribution to Identification in Forensic Anthropology and Medicine. *J Forensic Sci* 2013; 58(3): 571-577.
7. **Bongiovanni R, Spradley MK.** Estimating sex of the human skeleton based on metrics of the sternum. *Forensic Sci Int* 2012; 219(1-3): 290.e1-290.e7.
8. **Peleg S, Pelleg Kallevag R, Dar G, Steinberg N, Masharawi Y, May H.** New methods for sex estimation using sternum and rib morphology. *Int J Leg Med* 2020;134(4): 1519-1530.
9. **Singh J, Pathak RK.** Sex and age related non-metric variation of the human sternum in a Northwest Indian postmortem sample: a pilot study. *Forensic Sci Int* 2013; 228(1-3): 181.e1-12.
10. **Menezes RG, Kanchan T, Kumar GP, et al.** Stature estimation from the length of the sternum in South Indian males: A preliminary study. *J Forensic Leg Med* 2009; 16(8): 441-443.
11. **Saraf A, Kanchan T, Krishan K, Ateriya N, Setia P.** Estimation of stature from sternum – Exploring the quadratic models. *J Forensic Leg Med* 2018; 58: 9-13.
12. **Singh J, Pathak RK, Chavali KH**. Skeletal height estimation from regression analysis of sternal lengths in a Northwest Indian population of Chandigarh region: A postmortem study. *Forensic Sci Int* 2011; 206(1-3): 211.e1-211.e8.

proLékaře.cz | 28.9.2026

13. **Bacci N, Nchabeleng EK, Billings BK.** Forensic age-at-death estimation from the sternum in a black South African population. *Forensic Sci Int* 2018; 282: 233.e1-233.e7.
14. **Chandrakanth HV, Kanchan T, Krishan K, Arun M, Pramod Kumar GN.** Estimation of age from human sternum: an autopsy study on a sample from South India. *Int J Leg Med* 2012; 126(6): 863-868.
15. **Dorado-Fernández E, Cáceres-Monllor DA, Carrillo-Rodríguez MF, Botella-López M, Murillo-González J.** The Sternum as a Sex Discriminator in a Contemporary Spanish Population. *Rom J Leg Med* 2021; 29(1): 96-104.
16. **Myint tun S, Das S, Ruengdit S, Singsuwan P, Mahakkanukrauh P**. Sex determination from different sternal measurements: A study in a Thai population. *J Anat Soc India* 2015; 64(2): 155-161.
17. **Yonguc GN, Kurtulus A, Bayazit O, et al.** Estimation of stature and sex from sternal lengths: an autopsy study. *Anat Sci Int* 2014; 90(2): 89-96.
18. **Franklin D, Flavel A, Kuliukas A, et al.** Estimation of sex from sternal measurements in a Western Australian population. *Forensic Sci Int* 2012; 217(1-3): 230.e1-230.e5.
19. **Hyrtl J.** Handbuch Der Topographischen Anatomie.; 1857.
20. **Dwight T.** Sternum as an Index of Sex, Height, and Age. *PubMed* 1890; 24(4): 527-535.
21. **Bruce JS.** Utility of sternum to estimate sex and age. Dissertation Thesis, Boston University, School of Medicine. 2011; 93.
22. **Jaiswal R.** Sternum as an index for determination of sex. *Int J Anat Res* 2019; 7(4.2): 7070-7079.
23. **Koşar Mİ, Uğuz Gençer C, Tetiker H, Yeniçeri İÖ, Çullu N.** Sex and stature estimation based on multidetector computed tomography imaging measurements of the sternum in Turkish population. *Forensic Imaging* 2022; 28: 200495.
24. **Jeamamornrat V, Monum T, Keereewan W, Mahakkanukrauh P.** Stature estimation using the sternum in a Thai population. *Anat Cell Biol* 2022; 55(2): 170-178.
25. **Yammine K, Assi C. Estimation of stature from sternal lengths. A correlation meta-analysis.** *Archives of Forensic Medicine and Criminology* 2017; 67(3): 166-177.
26. **Zohlupuii LB, Devi TM, Haricharan A, Memchoubi PH.** Estimation of Stature from the Length of the Sternum in the Ethnic Meitei Population– A Study in Medicolegal Autopsies. *J Indian Acad Forensic Med* 2023; 45(2): 137-140.
27. **Singh J, Pathak RK, Chavali KH.** Skeletal height estimation from regression analysis of sternal lengths in a Northwest Indian population of Chandigarh region: A postmortem study. *Forensic Sci Int* 2011; 206(1-3): 211.e1-211.e8.
28. **Trotter M, Gleser GC.** Estimation of stature from long bones of American Whites and Negroes. *Am J Phys Anthropol* 1952; 10(4): 463-514.
29. **Nema P, Dadu SK, Singh BK, Rastogi AK, Pendro TS.** An autopsy based study about bisexualvariation in the fusion of sternal body segments in the central India region (M.P.). *J Forensic Med Toxicol* 2018; 35(1): 57-57.
30. **Sahu MR, Tripathy PR, Mohanty MK, Padhi KS, Naveen A.** Age estimation from sternum of eastern Indian population: Autopsy based study. *Indian J Forensic Community Med* 2022; 9(2): 59-64.
31. **Raveendran R, Sasikala K, Sivasuthan S.** Age Determination from Sternum. *Med Legal Update* 2017;17(1): 196.
32. **Martínez Vera NP, Höller J, Widek T, Neumayer B, Ehammer T, Urschler M.** Forensic age estimation by morphometric analysis of the manubrium from 3D MR images. *Forensic Sci Int* 2017; 277: 21-29.
33. **Ubelaker DH.** New perspectives of forensic anthroplogy. *Fol Soc Med Leg Slov* 2019; 9(1): 16-19.
34. **Dunn RR, Spiros MC, Kamnikar KR, Plemons AM, Hefner JT.** Ancestry estimation in forensic anthropology: A review. *WIREs Forensic Sci* 2020; 2(4).