proLékaře.cz | 29.9.2026

A case of arrhythmogenic right ventricular cardiomyopathy (ARVC/D) in which tenascin C immunostaining made the assessment of myocardial remodeling possible

Takeshi Kondo

Division of Diagnostic Molecular Pathology, Department of Community Medicine and Social Healthcare Science, Kobe University Graduate School of Medicine

SUMMARY

Arrhythmogenic right ventricular cardiomyopathy/dysplasia (ARVC/D) is characterized by progressive fatty and fibrous replacement. A female in her 70's, suddenly found in cardiopulmonary arrest. The heart weighed 452 g and yellow discoloration was observed. Histological examination revealed the replacement of the right ventricular myocardium by adipose tissue and fibrosis. The cause of death was fatal arrhythmia caused by ARVC/D. Tenascin C staining was useful in evaluating myocardial remodeling.

Keywords: ARVC/D – tenascin C – arrhythmia

Případ arytmogenní pravostranné ventrikulární kardiomyopatie (ARVC/D) s využitím imunohistochemického vyšetření tenascinu C k posouzení remodelace myokardu

SOUHRN

Arytmogenní pravostranná komorová kardiomyopatie/dysplázie (ARVC/D) je progresívní genetická kardiomyopatie charakterizovaná progresívní tukovou a vazivovou přeměnou komorového myokardu. Tenascin C je protein extracelulární matrix, jde o jeden z proteinů akutní faze které jsou produkovány v místech lézí procházejícících tkáňovou rekonstrukcí. Je znám jako marker myokardiálního poškození a myokardiální remodelace. Případ: žena, věkově na počátku 7. dekády s anamnézou angina pectoris a asthma bronchiale. Vzhledem k nevolnosti požádala syna o odvoz do nemocnice. Syn zaparkoval automobil na placeném parkovišti poblíž ordinace jejich praktického lékaře. Když matku v autě oslovil, nereagovala a byla v bezvědomí. Při přijetí na pohotovost již byla přítomna kardiopulmonální zástava a z bezvědomí se matka již neprobrala. Pacientka byl 156 cm vysoká a hmotnost byla 63 kg. Hmotnost srdce byla 452 g a úsekovitě byl v myokardu pozorován žlutavý nádech. Byla přítomna mírná ateroskleróza věnčitých tepen, ale bez signifikantních stenóz. Histologické vyšetření prokázalo přeměnu myokardu pravé komory v tukovou a vazivovou tkáň. Nekróza ani známky akutní ischemické choroby srdeční nebyly pozorovány. Mikroskopicky byla diagnostikována ARVC/D a jako příčina smrti byla stanovena fatální ahythmie způsobená ARVC/D. V této kazuistice ARVC/D bylo využito imunohistochemického vyšetření tenascinu C ke zhodnocení remodelace myokardu.

Klíčová slova: ARVC/D – tenascin C – arytmie

Soud Lek 2014; 59(3): 24-25

Arrhythmogenic right ventricular cardiomyopathy/dysplasia (ARVC/D) is a progressive genetic cardiomyopathy characterized by progressive fatty and fibrous replacement of ventricular myocardium (1). ARVC/D is characterized pathologically by myocardial atrophy, fibrofatty replacement, fibrosis and ultimate thinning of the wall with chamber dilation and aneurysm formation (2). These changes consequently produce electrical instability precipitating ventricular tachycardia and sudden cardiac death (3). ARVC/D is a devastating disease given the fact that the first symptom is often sudden cardiac death (3).

✉ ***Correspondence address:***
Takeshi Kondo
Division of Diagnostic Molecular Pathology
Department of Community Medicine and Social Healthcare Science
Kobe University Graduate School of Medicine
7-5-1 Kusunoki-cho, Chuo-ku, Kobe 650-0017, Japan
email: kondo@med.kobe-u.ac.jp

Tenascin C is an extracellular matrix protein, which is one of the acute phase proteins expressed in diseased sites undergoing tissue reconstruction (4). It is expressed in the invasive portions of malignant tumors and has been established as a marker for myocardial injury and myocardial remodeling (4).

This is a case report of arrhythmogenic right ventricular cardiomyopathy (ARVC/D) for which tenascin C immunostaining was useful in evaluating myocardial remodeling.

CASE

A female in her early 70's had a history of angina pectoris and asthma. She felt physically sick and asked her son to take her to a hospital. He parked the car in a coin-operated parking space near their family doctor's office. When he called her name in the car, she did not respond and was unconscious. While being admitted to the emergency department, she was in cardiopulmonary arrest, never recovered her consciousness, and was confirmed dead at hospital. Administrative autopsy was performed the following day.

proLékaře.cz | 29.9.2026

AUTOPSY FINDINGS

The subject was 156 cm tall and weighed 63 kg. Xanthomous lesions were scattered over the face. The heart weighed 452 g and yellow discoloration was observed in some areas of myocardium (Fig. 1). Moderate coronary sclerosis was noted, but no significant stenosis was observed. Histological examination of the myocardium revealed the replacement of the right ventricular myocardium by adipose tissue and fibrosis (Fig. 2). No myocardial necrosis and no findings indicating acute ischemic heart disease as the cause of death were observed. ARVC/D was diagnosed with microscopic examination and the cause of death was determined to be fatal arrhythmia caused by ARVC/D.

Immunohistological examination with tenascin C was performed in order to assess myocardial remodeling. A primary antibody to tenascin C (BC-24, Abcam plc. Tokyo, Japan) that reflects tissue remodeling with high sensitivity was used. Conditions were set for a positive control (invasive ductal carcinoma of the breast), antigen retrieval was conducted with proteolytic enzymes, and the antigen was visualized using the polymer staining technique. Masson trichrome staining was also performed to evaluate fibrosis. Immunohistostaining with tenascin C revealed positive findings in the myocardial stroma (Fig. 3).

The left lung weighed 417 g while the right lung weighed 444 g. Macroscopic findings indicated the presence of chronic obstructive pulmonary disease accompanied by emphysema. Histological examination indicated organizing pneumonia. There was a moderate volume of sputum in the airway, but no findings indicated suffocation. The brain weighed 1258 g and no lesions such as hemorrhage were observed.

DISCUSSION

ARVD is associated with highly variable clinical presentation such as ventricular tachycardia, syncope, right ventricular dysfunction and sudden death (5). Although several theories have been proposed and different genetic variants have been described, the accurate etiopathogenesis of ARVD is still unknown (5).

While it has been previously reported that large-scale myocardial remodeling such as myocarditis or myocardial infarction can be detected, preliminary investigation has indicated that tenascin C positivity indicates focal fibrosis with no acute myocardial changes. In some cases, it was possible to detect minute fibrosis difficult to identify with HE staining (unpublished data). This staining may be useful for the detection of myocardial remodeling in progress and the evaluation of myocardial disease associated with remodeling (unpublished data).

Here, immunostaining with tenascin C made it possible to visualize myocardial remodeling in progress in the myocardium of an ARVD case, suggesting its usefulness as a tool for analyzing cases of arrhythmia. All pathomorphological changes (pathomorphome) in myocardium including immunohistochemistry should be etiothanatologically analyzed routinely

ACKNOWLEDGEMENTS

I thank Mr. Shuichi Matsuda for his excellent technical assistance. This work was supported in part by a Grant-in-Aid for Scientific Research from the Ministry of Education, Culture, Sports, Science and Technology, Japan (24790640 to T.K).

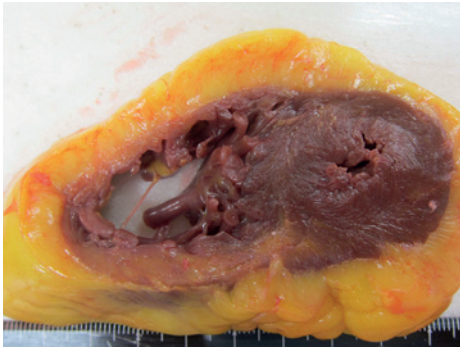

Fig. 1. Myocardium section. Yellow discoloration is apparent, centering on the right ventricle. No clear findings of infarction.

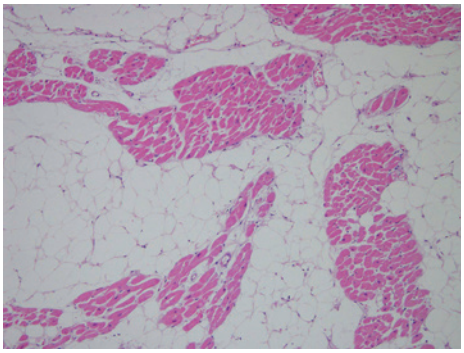

Fig. 2. Histology (hematoxylin and eosin staining) of the myocardium. Apparent replacement of myocardium by fat tissue. No myocardial necrosis.

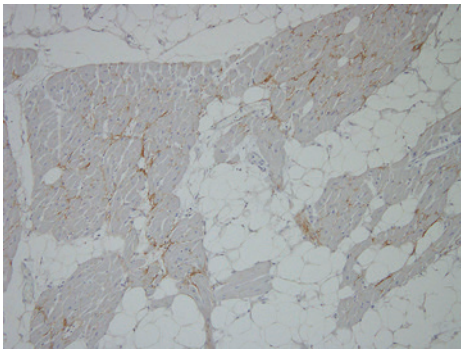

Fig. 3. Immunohistological staining with tenascin C. Positive findings observed in the myocardial stroma.

REFERENCES

1. **Iyer VR, Chin AJ.** Arrhythmogenic right ventricular cardiomyopathy/Dysplasia (ARVC/D). *Am J Med Genet C Semin Med Genet* 2013; 163(3): 185-197.
2. **Thiene G, Basso C, Danieli G, Rampazzo A, Corrado D, Nava A.** Arrhythmogenic right ventricular cardiomyopathy a still underrecognized clinic entity. *Trends Cardiovasc Med* 1997; 7(3): 84–90.
3. **Romero J, Mejia-Lopez E, Manrique C, Lucariello R.** Arrhythmogenic Right Ventricular Cardiomyopathy (ARVC/D): A Systematic Literature Review. *Clin Med Insights Cardiol* 2013; 7: 97-114.
4. **Imanaka-Yoshida K.** Tenascin-C in cardiovascular tissue remodeling: from development to inflammation and repair. *Circ J* 2012; 76(11): 2513-2520.
5. **Akan O, Cetin S, Eren B, Durak D, Türkmen N, Gündoğmuş UN.** Death due to Arrhythmogenic Right Ventricular Dysplasia: A case report. *Soud Lek* 2013; 58(3): 39-41.

OZNÁMENÍ

S radostí oznamujeme, že dne 19.6.2014 úspěšně obhájil habilitační práci s názvem: *„Sebevražda střelnou zbraní - soudnělékařská fenomenologie vybraných znaků“* člen naší redakční rady, místopředseda ČSSLST ČLS JEP a přednosta Ústavu soudního lékařství v Hradci Králové pan MUDr. Petr Hejna, Ph.D. MBA.

Naše srdečná gratulace.

Za redakční radu - Miroslav Hirt