

## Merkel Cells in Adnexal Neoplasias of Skin

Wollina U., Schrepel U.

Department of Dermatology, Hospital Dresden-Friedrichstadt, Academic Teaching Hospital of the Technical University Dresden, Dresden  
Chair: Prof. Uwe Wollina, MD

### Souhrn

#### Merkelovy buňky v adnexálních kožních nádorech

**Úvod:** Merkelovy buňky (MB) jsou neuroendokrinní buňky přítomné v kůži jak v bazální vrstvě epidermis, tak v zevní epitelové pochvě vlasového folikulu.

Imunohistochemické studie odhalily zvýšení jejich počtu v hyperplastických a nádorových kožních lézích. V této práci jsme zkoumali distribuci MB v nádorech kožních adnex a jejich možný vztah k proliferativní aktivitě nádorového epitelu.

**Materiál a metody:** Vyšetřili jsme 76 vzorků nádorů s folikulární diferenciací. Parafrinové a zmrazené řezy byly zpracovány imunohistochemicky metodou alkalická fosfatáza – anti-alkalická fosfatáza (APAAP) s použitím protilátek proti jednoduchým cytokeratinům identifikujících MB. Navíc byly použity protilátky proti MIB-1 a proliferujícímu nukleárnímu antigenu (PCNA) ke stanovení proliferativní aktivity nádorové tkáně.

**Výsledky:** Nádory s nejvyšší proliferativní aktivitou jako infundibulum, névus vlasového folikulu („hair follicle naevus“), trichofolikulom byly zároveň nádory s nejvyšším počtem MB. V naší studii měl trichoepitheliom zvýšenou proliferativní aktivitu, ale nebyl prokázán zvýšený počet MB. Počet MB v bazaliomu a trichofolikulomu odpovídal proliferativní aktivitě nádoru.

**Závěr:** Adnexální nádory s folikulární diferenciací často obsahují MB. MB jsou pravděpodobně zapojeny v kontrolních mechanismech proliferace. I když lze uvažovat o vlivu uvolňovaných neuropeptidů v lokální stimulaci proliferace, přesný mechanismus, kterým MB stimulují buněčné dělení, zatím nebyl objasněn.

**Klíčová slova:** adnexální nádory – folikulární diferenciacie – Merkelovy buňky – proliferativní aktivita

### Summary

#### Merkel Cells in Adnexal Neoplasias of Skin

**Introduction:** Merkel cells (MC) are neuroendocrine cells of skin present in both the epidermal basal layer and the outer root sheath of hair follicles. Immunohistochemical studies revealed an increase of their number in hyperplastic and neoplastic lesions of skin. In this paper, we investigated the distribution of MC among adnexal skin tumors and their possible relationship to proliferative activity of the tumor epithelium.

**Material and methods:** We investigated 76 tumor specimens with hair follicle differentiation. Paraffin-embedded tissue and cryo-preserved tissue samples were available for immunohistology using the alkaline phosphatase – anti-alkaline phosphatase (APAAP) technique with antibodies against simple-type cytokeratins to identify MC. In addition, antibodies against MIB-1 and proliferating cell nuclear antigen (PCNA) were applied to evaluate the proliferative activity of the tumors.

**Results:** The tumors with the highest proliferative activity like infundibular tumor, hair follicle nevus, trichofolliculoma were also the tumors with the highest number of MC. In our hands, the trichoepithelioma had an increased proliferative activity but not an increased number of MC. In basal cell carcinoma and trichofolliculoma MC were found in close proximity to proliferating tumor cells.

**Conclusion:** Skin adnexal tumors of hair follicle differentiation often contain MC. MC seem to be involved in proliferation control. Though one might speculate about release of neuropeptides from MC to stimulate local growth the exact mechanism(s) by which the proliferation can be stimulated by MC remains to be elucidated.

**Key word:** adnexal tumors of skin – hair follicle differentiation – Merkel cell – proliferative activity

## INTRODUCTION

Merkel cells (MC) are neuroendocrine cells present in the basal cell layer of the epidermis or within the hair follicle. The follicular are localized within the outer root sheath in the region of the nerve plexus and in the bulge region (Wulst) (14). MC develop intracellular neuroendocrine granula of 80 to 120 nm size and express simple-type cytokeratins 8, 18, and 20 (7, 16). MC are capable to synthesize and secrete a variety of different neuropeptides including substance P, vasoactive intestinal peptide or calcitonin gene related peptide (5, 28, 29).

MC themselves do not proliferate but can be generated from epidermal keratinocytes by transdifferentiation (3, 18, 19, 27, 31). Transdifferentiation stands for a change in the programme of differentiation of cells without a change in proliferative activity.

The normal MC density differs between 5/mm<sup>2</sup> on the glans penis to 103/ mm<sup>2</sup> on the finger pulp (11). An increase in the MC density has been reported from chronic actinic damaged skin (15), hypertrophic actinic keratoses (13), prurigo nodularis (17), and psoriasis plaques (29). Therefore, it has been speculated about a relationship between MC and proliferative activity of epithelial cells (13).

In the present paper we investigated different skin tumors with adnexal differentiation for presence of MC and their relationship to proliferative activity.

## MATERIAL AND METHODS

Of 78 adnexal skin tumors paraffin-embedded and/ or cryo-preserved material was available for this study (Table 1). Tissue sections of about 5 µm were stained with monoclonal antibodies against simple-type cytokeratins (CK20 against cytokeratin 20 from DAKO; Cam 5.2 against cytokeratins 8 and 18 from Becton Dickinson) and antibodies against antigens associated with prolifera-

**Table 1. Tumor specimens investigated**

Tumor type	n
Trichofolliculoma	10
Trichoepithelioma	13
Inverted follicular keratosis	9
Infundibular tumor	1
Nevoid bundle hair	1
Proliferating trichilemmal cyst	5
Hair follicle nevus	8
Nevus sebaceous	2
Pilomatrixoma	3
Basal cell carcinoma	26
solid type	24
morpheiform type	2
Total	78

tive activity (MIB-1 – DIANOVA, proliferation cell nuclear antigen – PCNA from MEDAC) on parallel sections. We used the alkaline phosphates-anti alkaline phosphatase (APAAP) technique developed with naphthol As-Mx phosphate according to Schaumburg-Lever (24). The MC density was calculated according to Moll et al. (15).

Statistical analysis: Mann-Whitney-U-test, correlations according to Pearson (22).

## RESULTS

Within the tumor parenchyma MC were identified in trichofolliculoma, trichoepithelioma, trichilemmal cyst and basal cell carcinoma. The MC density varied between 0.2 and 1.2/ mm<sup>2</sup>. In the tumor stroma MC were observed in all tumor entities at a density between 1.0 and 21.4/ mm<sup>2</sup>. The details are given in Table 2.

**Table 2. MC density within the tumor parenchyma (as measured by Cam 5.2-positive cells)**

Tumor type	MC density (MC/ mm <sup>2</sup> )
Trichofolliculoma	1.2
Trichoepithelioma	0.7
Inverted follicular keratosis	0.0
Infundibular tumor	0.0
Nevoid bundle hair	0.0
Proliferating trichilemmal cyst	1.0
Hair follicle nevus	0.0
Nevus sebaceous	0.0
Pilomatrixoma	0.0
Basal cell carcinoma	0.2

**Table 3. Proliferative activity of adnexal tumors**

Tumor type	Proliferative density/ mm <sup>2</sup>	
	MIB-1	PCNA
Trichofolliculoma	4.3	0.4
Trichoepithelioma	3.4	1.3
Inverted follicular keratosis	1.0	1.6
Infundibular tumor	7.5	0.0
Nevoid bundle hair	0.0	0.0
Proliferating trichilemmal cyst	0.5	0.0
Hair follicle nevus	4.8	0.0
Nevus sebaceous	0.0	0.0
Pilomatrixoma	0.0	0.0
Basal cell carcinoma	2.1	2.2

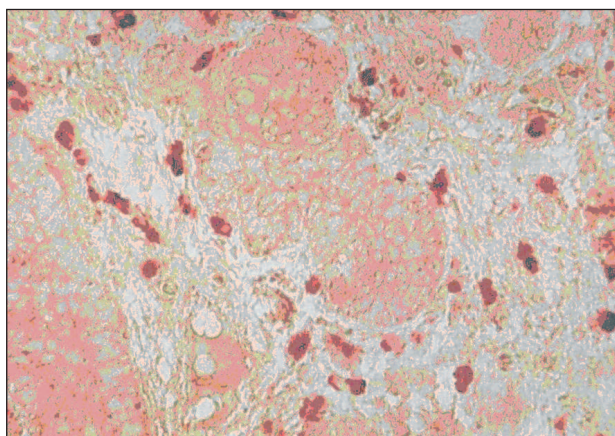
Proliferative activity was higher with MIB-1 than PCNA for either tumor parenchyma and stroma (Table 3). There was a positive correlation of the count of MIB-1 positive tumor cells and MC counts within the tumor parenchyma ( $p = 0.0018$ ).

Cam 5.2 but not CK20 also stained single cells within the tumor stroma. We observed a density of Cam 5.2-positive dermal cells between 1.0 mm<sup>-2</sup> (inverted follicular keratosis) to 21.4 mm<sup>-2</sup> (basal cell carcinoma) [Table 4;

Fig. 1]. Considering all adnexal tumor entities investigated there was a positive correlation between stromal Cam 5.2-positive cells and tumor cell proliferation as measured by MIB 1 but not PCNA ( $p = 0.0018$ ). This was not the case for basal cell carcinoma despite they had the highest number of dermal MC ( $p = 0.15$ ).

**Table 4. Cam 5.2-positive cell density within the tumor parenchyma**

Tumor type	MC density (MC/ mm <sup>2</sup> )
Trichofolliculoma	20.5
Trichoepithelioma	11.0
Inverted follicular keratosis	1.0
Infundibular tumor	15.0
Nevoid bundle hair	12.0
Proliferating trichilemmal cyst	1.5
Hair follicle nevus	16.8
Nevus sebaceous	13.0
Pilomatrixoma	9.0
Basal cell carcinoma	21.4



**Fig. 1. Demonstration of dermal Merkel cells beneath a basal cell carcinoma (APAAP staining with Cam 5.2; original magnification x 400)**

## DISCUSSION

In previous studies MC were identified in hair follicle tumors of human skin. By means of immunohistochemistry, MC have been identified in sebaceous nevus, trichofolliculoma, trichoepithelioma – especially of the desmoplastic type (20, 25), trichoblastoma (2), fibrous papules of the face (10), chondroid syringoma (23), morpheiform basal cell carcinoma (1), and lymphadenoma (12). Some authors conclude from their work that CK20-positive MC are absent in basal cell carcinomas but frequently found in trichoblastomas. Therefore this might be of value in differentiating both tumor types (25).

We observed MC within the tumor parenchyma of trichofolliculoma, trichoepithelioma and trichilemmal cysts and in a low density also within basal cell carcinomas (see Table 2).

Proliferative activity was calculated by immunostaining for two different proliferation-associated antigens, i.e. MIB-1 and PCNA. MIB-1 is a monoclonal antibody reacting with the Ki67-antigen that is expressed throughout the cell cycle with the exception of G0 and early G1 (4). PCNA is a co-protein of DNA polymerase  $\delta$  that is expressed in particular during late G1 and S phase (26). We observed a better reactivity of the tumor specimen with MIB-1 (see Table 3). The Pearson correlation suggests an association of MC density with proliferative active (MIB-1).

The density of dermal MC as measured by Cam 5.2 positivity was higher than that of MC within the tumor parenchyma (see Table 4). Dermal MC are well known to react with Cam 5.2 (8, 19). The different immunoreactivity of epidermal and dermal MC with CK20 cannot be explained from our study. Dermal MC density was correlated with tumor cell proliferation.

This might be explained by paracrine activity. Some of the neuropeptides found within MC, like substance P or VIP are stimulating for epidermal keratinocytes *in vitro* (9, 22, 30, 32).

Whether neuropeptides might also be a stimulus for adnexal tumor cells remains to be elucidated.

## REFERENCES

1. ABESAMIS-CUBILLAN, E., EI-SHABRAWI-CAELEN, L., LEBOIT, PE. Merkel cells and sclerosing epithelial neoplasms. *Am J Dermatopathol*, 2000, 22, p. 311–315.
2. COLLINA, G., EUSEBI, V., CAPELLA, C., ROSAI, J. Merkel cell differentiation in trichoblastoma. *Virchows Arch*, 1998, 433, p. 291–296.
3. COMPTON, CC., REGAUER, S., SEILER, GR., LANDRY, D. Human Merkel cell regeneration in skin derived from cultured keratinocyte grafts. *Lab Invest*, 1990, 62, p. 233–241.
4. GERDES, J., SCHWAB, U., LEMKE, H., STEIN, H. Production of a mouse monoclonal antibody reactive with a human nuclear antigen associated with cell proliferation. *Int J Cancer*, 1983, 31, p. 13–20.
5. HARTSCHUH, W., WEIHE, E., JANAIHARA, N. Immunohistochemical analysis of chromogranin A and multiple peptides in the mammalian Merkel cell: further evidence for its paraneural function. *Acta Histol Cytol*, 1989, 52, p. 423–431.
6. HARTSCHUH, W., SCHULZ, T. Merkel cells are integral constituents of desmoplastic trichoepithelioma: an immunohistochemical and electron microscopic study. *J Cutan Pathol*, 1995, 22, p. 413–421.
7. HASHIMOTO, K. Fine structure of Merkel cell in human oral mucosa. *J Invest Dermatol*, 1972; 58, p. 381–387.
8. HEENAN, PJ., COLE, JM., SPAGNOLO, DV. Primary cutaneous neuroendocrine carcinoma (Merkel cell tumor). An adnexal epithelial neoplasm. *Am J Dermatopathol*, 1990, 12, p. 7–16.
9. KAKURAI, M., FUJITA, N., MURATA, S., FURUKAWA, Y., DEMITSU, T., NAKAGAWA, H. Vasoactive intestinal

- peptide regulates its receptor expression and functions of human keratinocytes via type I vasoactive intestinal peptide receptors. *J Invest Dermatol*, 2001, 116, p. 743–749.
10. KANITAKIS, J., BOURCHANY, D., FAURE, M., CLAUDY, A. Merkel cells in hyperplastic and neoplastic lesions of the skin. *Dermatology*, 1998, 196, p. 208–212.
  11. LACOUR, JP., DUBOIS, D., PISANI, A., ORTONNE, JP. Anatomical mapping of Merkel cells in normal human adult epidermis. *Br J Dermatol*, 1991, 125, p. 535–542.
  12. MCNIFF, JM., EISEN, RN., GLUSAC, EJ. Immunohistochemical comparison of cutaneous lymphadenoma, trichoblastoma, and basal cell carcinoma: support for classification of lymphadenoma as a variant of trichoblastoma. *J Cutan Pathol*, 1999, 26, p. 119–124.
  13. MEROT, Y., MOOY, A. Merkel cell hyperplasia in hypertrophic varieties of actinic keratosis. *Dermatologica*, 1989, 178, p. 189–193.
  14. MOLL, I. Merkel cell distribution in human hair follicles of the fetal and adult scalp. *Cell Tissue Res*, 1994, 277, p. 131–138.
  15. MOLL, I., BLADT, U., JUNG, EG. Presence of Merkel cells in sun-exposed and not sun-exposed skin: a quantitative study. *Arch Dermatol Res*, 1990, 282, p. 213–216.
  16. MOLL, R., MOLL, I., FRANKE, W. Identification of Merkel cells in human skin by specific cytokeratin antibodies: changes of cell density and distribution in fetal and adult plantar epidermis. *Differentiation*, 1984, 28, p. 136–154.
  17. NAHASS, GT., PENNEYS, NS. Merkel cells and prurigo nodularis. *J Am Acad Dermatol*, 1994, 31, p. 86–88.
  18. NARISAWA, Y., HASHIMOTO, K. Immunohistochemical demonstration of nerve-Merkel cell complex in fetal human skin. *J Dermatol Sci*, 1991, 2, p. 361–370.
  19. NARISAWA, Y., HASHIMOTO, K., KOHDA, H. Merkel cells participate in the induction and alignment of epidermal ends of arrector pili muscles of human fetal skin. *Br J Dermatol*, 1996, 134, p. 494–498.
  20. OHNISHI, T., WATANABE, S. Incidence of cytokeratin 20 expressed in primitive follicular structure and secondary neoplastic proliferations of nevus sebaceous. *J Dermatol Sci*, 2003, 33, p. 17–21.
  21. PINCELLI, C., FANTINI, F., ROMUALDI, P., SEVIGNANI, C., LESA, G., BENASSI, L., GIANNETTI, A. Substance P is diminished and vasoactive intestinal peptide is augmented in psoriatic lesions and these peptides exert disparate effects on the proliferation of cultured human keratinocytes. *J Invest Dermatol*, 1992, 98, p. 421–427.
  22. SACHS, L. *Angewandte Statistik*, 7<sup>th</sup> Edition. Berlin – Heidelberg: Springer, 1992.
  23. SALAMA, ME., AZAM, M., MA, CK., ORMSBY, A., ZARBO, RJ., AMIN, MB., LEE, MW. Chondroid syringoma. Cytokeratin 20 immunolocalization of Merkel cells and reappraisal of apocrine-folliculo-sebaceous differentiation. *Arch Pathol Lab Med*, 2004, 128, p. 986–990.
  24. SCHAUMBURG-LEVER, G. The alkaline phosphatase anti-alkaline phosphatase technique in dermatopathology. *J Cutan Pathol*, 1987, 14, p. 6–9.
  25. SCHULZ, T., HARTSCHUH, W. Merkel cells are absent in basal cell carcinomas but frequently found in trichoblastomas. An immunohistochemical study. *J Cutan Pathol*, 1997, 24, p. 14–24.
  26. WASSEM, KH., LAKE, DP. Monoclonal antibody analysis of the proliferating cell nuclear antigen (PCNA). Structural conservation and the detection of a nucleolar form. *J Cell Sci*, 1990, 96, p. 121–129.
  27. WOLLINA, U. Diversity of epithelial skin tumors: thoughts and comments on some basic principles. *Rec Results Cancer Res*, 1993, 128, p. 153–178.
  28. WOLLINA, U., KARSTEN, U. Immunohistochemical demonstration of cytokeratin 19-positive basal cells in psoriatic plaques. *Arch Dermatol Res*, 1988, 280, p. 257–258.
  29. WOLLINA, U., MAHRLE, G. Epidermal Merkel cells in psoriatic lesions: Immunohistochemical investigations on neuroendocrine antigen expression. *J Dermatol Sci*, 1992, 3, 145–150.
  30. WOLLINA, U., BONNEKOH, B., KLINGER, R., WETZKER, R., MAHRLE, G. Vasoactive intestinal peptide (VIP) acting as a growth factor for human keratinocytes. *Neuroendocrinol Lett*, 1992, 14, p. 21–31.
  31. WOLLINA, U., BERGER, U. Neuropeptides and Merkel cells in tissue expansion. In: Altmeyer, P., Hoffmann, K., el-Gammal, S., Hutchinson, J (Editors). *Wound Healing and Skin Physiology*. Berlin-Heidelberg-New York: Springer, 1995, p. 367–380.
  32. WOLLINA, U., PROCHNAU, D., HOFFMANN, A., HIPLER, UC., WETZKER, R. Vasoactive intestinal peptide and epidermal growth factor: co-mitogens or inhibitors of keratinocyte proliferation in vitro? *Int J Mol Med*, 1998, 2, p. 725–730.

Došlo do redakce: 11. 12. 2005

Prof. Dr. Uwe Wollina  
 Department of Dermatology  
 Hospital Dresden-Friedrichstadt  
 Academic Teaching Hospital  
 of the Technical University  
 Friedrichstrasse 41  
 01067 Dresden, Germany  
 E-mail: wollina-uw@khd.fg.de