

# Non-surgical Treatment of a Tooth Associated with a Large Periapical Radiolucency Resembling Periapical Cyst

## (A Case Report)

*Sukumar S., Bednář P., Dřížhal I.*

Dental Clinic of the Faculty of Medicine of Charles University and  
Faculty Hospital in Hradec Králové

### Summary

The treatment of teeth associated with large periapical lesions require definitive skill in diagnosis and decision making. In this case report, a 41-year-old male with a large radiolucency in the periapical region of maxillary right lateral incisor is described. The radiolucency resembled a periapical "bay cyst". The periapical lesion followed necrosis of the pulp. Non-surgical root canal treatment was done. During the course of treatment sodium hypochlorite was used for irrigation and calcium hydroxide was used as the intracanal dressing. After obturation, the patient was instructed to come for evaluation, but he appeared only after 3 years. A radiograph taken at that time showed complete resolution of the lesion.

**Key words:** large periapical radiolucencies of endodontic origin - root canal therapy - true cysts - bay cysts

### Sukumar S., Bednář P., Dřížhal I.: Nechirurgická léčba zubu spojená s velkým periapikálním projasněním při RTG snímkování podobné periapikální cystě

**Souhrn:** Léčba zubů s rozsáhlým periapikálním nálezem vyžaduje značnou znalost diagnostiky a správnou úvahu o dalším léčebném postupu. V předložené kazuistice autoři demonstrují léčebný postup u 41letého muže, který se dostavil se rozsáhlým cystickým projasněním u zubu 12. Projasnění vzniklo na podkladě chronického periapikálního procesu. Autoři demonstrují postupné hojení cysty po endodontickém ošetření a upozorňují, že se to nemusí ve všech případech podařit. Endodontické ošetření provedli běžným způsobem. Komplikací byla neukázněnost pacienta, který nedodržel pravidelné kontroly, které zajistí sledování stavu a upozorní na případnou nutnost chirurgické intervence, pokud nedochází ke zmenšování nálezu. Pacient se dostavil až po 3 letech, kdy se zjistilo na rentgenogramu již vyhojení periapikálního procesu.

**Klíčová slova:** rozsáhlé periapikální projasnění odontogenního původu - ošetření kořenového kanálku - pravá cysta

*Prakt. zub. Lék., roč. 55, 2007, č. 5, s. 94–97.*

### INTRODUCTION

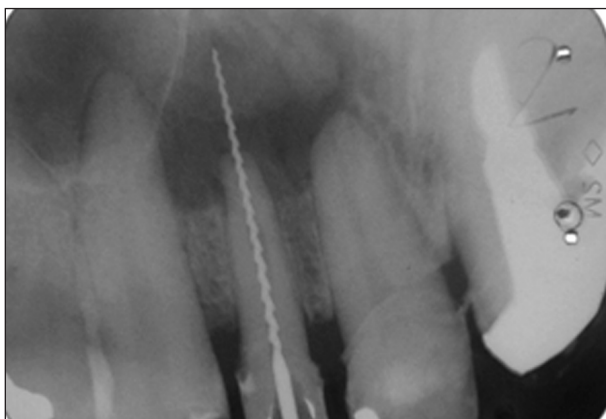
Periapical cysts are the most common cysts of the jaws. A periapical cyst is a periapical radiolucent lesion associated with a non-vital tooth consisting of an epithelium-lined cavity supported by a chronically-inflamed connective tissue wall [9]. Periapical pathologies are caused by combinations of bacteria, usually anaerobic, bacterial products and the host response to them. Periapical pathologies are transitional entities [4]. The periapical cyst usually develops from a pre-existing periapical epitheliated granuloma, which represents a focus of chronically-inflamed granulation

tissue in the bone at the apex of a non-vital tooth. The epithelium is derived from the cell rests of Malassez which remains in the granuloma [7]. If the granuloma or chronic apical periodontitis is not treated, the epithelium proliferates in an attempt to wall off the source of irritation. The result is a chronic inflammatory lesion that has epithelium lining the lumen, but the lumen has a direct communication with the root-canal system through the foramen. This situation is termed as 'bay cyst' [3] or periapical pocket cyst [6], which is not a true cyst because of its communication with the root-canal. The true cyst is the completion of the epithelial proliferative lesion.

## CASE REPORT

A 41 year old male patient was referred to the clinic with a large periapical radiolucency in the periapical region of tooth 12 (Fig 1). The patient alleged that some resective surgery was done in relation to that tooth. He did not have any other complaints.

On examination, there was no swelling, redness or sinus opening. The tooth was slightly sensitive to percussion. Radiographically, there was a large radiolucency of approximate size 12x10 mm involving the root apex of tooth 12 and extending to the periodontal areas of teeth 11 and 13. The root apex of 12 was wide open and the instrument tip is seen well beyond the apex. The lesion appeared to resemble a periapical „bay cyst” (Fig 1).



**Fig. 1. Radiograph bought by the patient, which shows a large radiolucent lesion involving the root apex of 12 and extending to the periodontal areas of 11 and 12.**

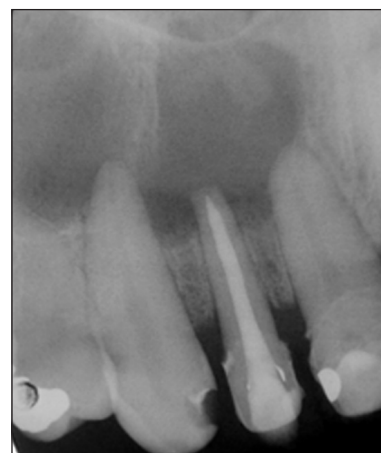Tests were done to prove the vitality of adjacent teeth. Tooth 11 was not responding clearly as it was restored with an acrylic crown. So a test cavity was prepared through the crown. The tooth was sensitive while cutting the dentine, thus proving the vitality. The test cavity was restored with composite resin.

After confirming vitality of the adjacent teeth, the mode of treatment for tooth 12 was decided. In spite of the large size of the radiolucency, root canal therapy was advised with follow-up until complete healing of the lesion. Access cavity was prepared, working length estimated as 19 mm and the canal enlarged by circumferential filing technique upto ISO 90 (Mailefer®, DENTSPLY, Germany). (Working length x-ray is not demonstrated in this article because of its poor quality). 2% sodium hypochlorite was used for irrigation. The canal was provisionally filled with calcium hydroxide (Calxyd®, SPOFA DENTAL, Czech Republic), with a lentulo filler, to enhance hea-

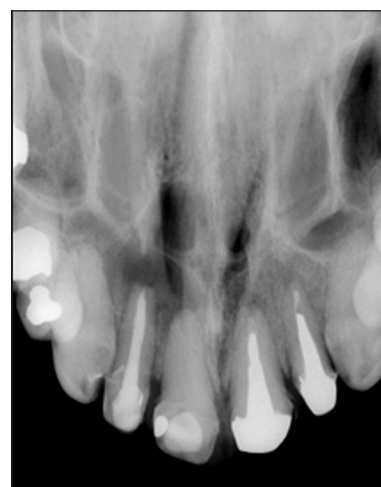
ling. Patient was instructed to come immediately if there is any complaint or else to come after one month for finishing the root canal treatment, and then sent back.

Patient came back after 5 days with a complaint that there was a feeling of pressure above the particular tooth and pus was coming out of his right nostril 2 days back, but the symptoms disappeared after that. He was sent back advising him to come immediately if the condition worsens.

He again appeared after 20 days with a complaint that when he wakes up in the morning, there was a feeling of fullness in the right maxillary sinus area and there was pus discharge after blowing the nose. On clinical examination, there was no obvious swelling. The upper right incisors were sensitive to percussion. On palpation, a bony defect was found on the vestibular area above the particular tooth which was about 6 mm in diameter. The area was anesthetised with 2 ml of 4% Supracaine injection (ZENTIVA, Czech Republic) and aspiration was attempted through

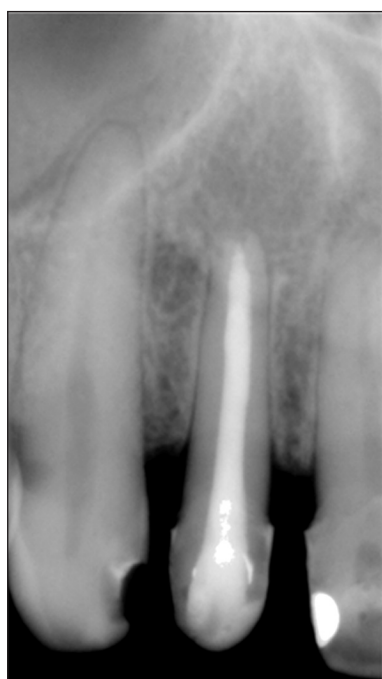

**Fig. 2. Radiograph taken immediately after obturation.**



**Fig. 3. Occlusal radiograph after obturation.**

the bony defect of the vestibular area in order to relieve the pressure. About 2 ml of blood and pus was obtained. The cleaning and shaping of root canal was completed and canal enlarged upto ISO 100 size, obturated with gutta percha (DiaDent®, DiaDent Group International, Korea) using lateral condensation and AH 26 (DeTrey®, DENTSPLY, Germany) as sealer and provisionally restored with composite resin (Esthet-X®, DENTSPLY, Germany) (Fig 2, Fig 3). Patient was informed about all possible complications and advised him to come immediately in case of any complaint or else to come after 6 months for radiographic evaluation of the healing of the lesion. But he came only after 3 years inspite of repeated calls from the clinic, as he was relieved of the symptoms after the treatment. A radiograph was taken in relation to that tooth. It showed complete resolution of the lesion (Fig 4).



**Fig. 4. Radiograph taken after three years, which shows complete resolution of the lesion.**

## DISCUSSION

As periapical cyst represents the most frequent cystic lesion of the maxilla, its correct diagnosis and adequate treatment are of considerable importance. Most periapical cysts are asymptomatic and are often discovered accidentally during routine dental radiographic examination. By definition, a nonvital pulp is necessary for the clinical diagnosis of a periapical cyst. The radiolucency associated with a periapical cyst is generally round to ovoid, with a narrow, opaque margin that may be continuous with the lamina dura of the involved tooth

[7]. But there is special difficulty in establishing the differential diagnosis of this lesion compared to chronic apical periodontitis or periapical granuloma, which also has the same clinical and radiographic features [8]. It could be differentiated by histopathological examination.

The periapical cyst could be successfully managed by extraction of the associated nonvital tooth and curettage of the epithelium in the apical zone. Alternatively, a root canal therapy may be performed in association with an apicoectomy to permit direct curettage of the lesion. The third and the most frequently used option involves performing a root canal treatment only and further follow-up till the complete resolution of the lesion [2, 7]. Since root canal therapy can directly affect the lumen of the 'bay cyst', the environmental change may bring about resolution of the lesion [3, 5]. But there are certain challenges to be faced by the Dentists if they opt for only root canal therapy. One of such is periapical true cysts which usually do not heal with non-surgical treatment [5]. Another problem is patient not returning for evaluation. If the radiolucent lesion is a granuloma, there are chances of developing small cyst inside the granuloma which may enlarge once the granuloma is fully cured.

Romero [8] suggested certain guidelines for the choice of treatment according to the size of the lesion. If the lesion is less than 5 mm in diameter, endodontic treatment and revision of patient at 6 months is recommended. If the lesion is of medium size (5 to 10 mm in diameter), endodontic treatment could be done and a short term revision program should be implemented (3 months), where the aim is not to verify any cure, but to ensure favorable evolution. For larger sized lesions (more than 10 mm in diameter), endodontic treatment along with a surgical approach is recommended.

In the past, some authors came up with the idea of bringing in certain manipulations in the root canal therapy especially for treating the cysts. One such method was described by Bhasker [1], who suggested that instrumentation slightly beyond the apical foramen produces a transient acute inflammation which may destroy the epithelial lining of radicular cysts and convert them into granulomas, thus leading to their resolution.

Follow-up is an important aspect of the treatment. If the patient fails to come for evaluation, the end result of the treatment cannot be made out. Sometimes the patient returns only when the situation worsens. There is a possibility of malignant transformation of the cells of the cyst capsule.

If there is a developing cyst inside a granuloma, after root canal treatment the granuloma slowly resolves creating a false impression that the lesion is getting healed. But once the granuloma resolves around the developing cyst, the cyst may start enlarging. This suggests the importance of evaluation of the lesion till it completely disappears.


## CONCLUSION

Treatment options to manage large periapical radiolucency of endodontic origin range from non-surgical root canal treatment to extraction. Root canal treatment removes the causative agents of the lesion. Majority of the cysts are resolved once the causative agents are removed, the bay cysts in particular. So it is advisable to perform root canal treatment first and then proper post-treatment evaluation to analyse adequate healing. Patient's co-operation is an important factor for proper follow-up. If the lesion doesn't respond to root canal treatment, then apical surgery could be carried out to permit direct curettage of the lesion or extraction of the associated tooth and curettage as a final resort.

## REFERENCES

1. **Bhasker, S. N.:** Nonsurgical resolution of radicular cysts. *Oral Surgery*, 34, 1972, s. 458-468.
2. **Caliskan, M. K.:** Prognosis of large cyst-like periapical lesions following non-surgical root-canal treatment: a clinical review. *International Endodontic Journal*, 37, 2004, s. 408-416.
3. **Cohen, S., Burns, R. C.:** Pathways of the pulp, St Louis, MO, USA, Mosby, 7th edn, 1998, s. 443-454.
4. **Lia, R. C. C., Garcia, J. M. Q., Souza-neto, M. D., Saquy, P. C., Marins, R. H., Zucollotto, W. G.:** Clinical, radiographic and histological evaluation of chronic periapical inflammatory Lesions. *Journal of Applied Oral Science*, 12, 2004, s. 117-120.
5. **Nair, P. N. R.:** New perspectives on radicular cysts: do they heal? *International Endodontic Journal*, 31, 1998, s. 155-160.
6. **Nair, P. N. R., Pajarola, G., Schroeder, H. E.:** Types and incidence of human periapical lesions obtained with extracted teeth. *Oral Surgery, Oral Medicine, Oral Pathology, Oral Radiology and Endodontics*, 81, 1996, s. 93-102.
7. **Regezi, J. A., Sciubba, J. J.:** Oral pathology: clinical pathologic correlations. Chapter 10, Philadelphia, USA: Saunders, 3rd edition, 1999, s. 288-291.
8. **Romero, D. G.:** Differential diagnosis and therapeutic approach to periapical cysts in daily dental practice. *Medicina Oral*, 7, 2002, s. 59-62.
9. **Sapp, J. P., Eversole, L. R., Wysoki, G. W.:** Contemporary oral and maxillofacial pathology. Chapter 3, St Louis, MO, USA: Mosby, 2nd edn, 2003, s. 83-91.

*MUDr. Sujith Sukumar*  
*Stomatologická klinika LF UK a FN*  
*Sokolská 581*  
*500 05 Hradec Králové*



## ORTODONTICKÝ PRŮVODCE PRAKTICKÉHO ZUBNÍHO LÉKAŘE

*Magdalena Kotová*

Včasné rozpoznání ortodontické vady je předpokladem volby a realizace nejvhodnějšího terapeutického postupu. Pro praktického stomatologa jsou „ortodontické diagnostické rozpaky“ častou překážkou např. pro sestavení plánu protetické rekonstrukce chrupu.

Text upozorňuje zejména na:

1. úskalí včasné diagnostiky ortodontických anomálií,
2. strategii začlenění ortodontické terapie do plánu komplexního stomatologického ošetření pacienta včetně využití implantátů,
3. často nenápadné symptomy signalizující odchylky ve vývoji stomatognátní oblasti.

Publikace, která je určena zejména praktickým zubním lékařům, je doplněna bohatou názornou obrazovou dokumentací – na 140 obrázků (z toho 47 perokreseb).

Vydalo nakladatelství Grada Publishing v roce 2006, B5, brožovaná vazba, 116 stran, cena 245,-Kč, 376,-Sk, ISBN 80-247-1305-5, kat. číslo 1516

Objednávku můžete poslat na adresu: Nakladatelské a tiskové středisko ČLS JEP, Sokolská 31, 120 26 Praha 2, fax: 224 266 226, e-mail: nts@cls.cz