

phic altered RPE are hypoautofluorescent, while there is an absence of autofluorescence in places of RPE atrophy. At the outset these are generally hyperautofluorescent if subretinal fluid is present, but they progressively become hypoautofluorescent upon the gradual degradation of the RPE cells, up to their complete atrophy. Studies have demonstrated a relatively good correlation between the findings on FAF and retinal sensitivity quantified by microperimetry and VA, and FAF may therefore be used in order to estimate the degree of functional changes in eyes with CSC, as well as for the prognosis of the change of BCVA in connection with the therapeutic intervention [117].

### Macular microperimetry

Macular microperimetry detects reduced macular sensitivity in patients with CSC, and may be a useful subjective examination method for evaluating response to photodynamic therapy. The results of clinical trials indicated that mere examination of VA alone may significantly underestimate changes to macular functions, which accompany successful treatment of CSC. Macular microperimetry has been demonstrated to be an appropriate method for precisely evaluating the sensitivity of the retina in patients treated with the aid of PDT or micropulse laser, in whom better sensitivity has been demonstrated in the central retinal region after therapy [117,118].

### Multifocal electroretinography

Multifocal electroretinography (mfERG) serves for objective evaluation of functional changes of the retina in patients with CSC. Improvement of BCVA and central retinal thickness following therapy with the aid of PDT was in correlation with response to mfERG; although after absorption of the subretinal fluid there was a significant improvement in the recording on mfERG, the original values are not generally attained [119,120].

### Laboratory examination

In the majority of cases, the results of laboratory examinations are not of any benefit for determination of the diagnosis. Nevertheless, in recent years a correlation has been stated with increased serum levels of plasminogen activator inhibitor 1 in patients with CSC [35]. Higher values of endogenous cortisol may also be identified, which is considered one of the main risk factors of the onset of CSC, or abnormal values of blood coagulation parameters (e.g. lower level of platelet derived growth factor) [79,121]. However, no laboratory test exists which is specific for the diagnosis of this pathology.

## THERAPY OF CSC

Even despite all the advances in diagnostics, examination and therapeutic options, the optimal approach and choice of adequate treatment of CSC remains contentious. This controversy is due to the fact that although the pathology has a substantial tendency towards spontaneous recovery, with an excellent prognosis of resulting VA, on the other

hand long-term retinal detachment may lead to pronounced irreversible anatomical and functional changes (Fig. 5). The principle of treatment is to induce reattachment of the neuroretina, to improve or preserve VA and to minimize the risk of recurrence. Upon selection of a suitable method of treatment it is always necessary to take into consideration the potential temporary course of the disease, the localization of the pathological leakage and the condition of the RPE.

### Conservative approach – observation and modification of risk factors

In the case of the acute phase of the pathology, especially if serous detachment of the neuroretina is caused by a specific source of leakage, spontaneous resorption of the SRF occurs in the majority of cases (80–90%) within 3 months of the onset of the disease [47,122]. As a result, in the acute phase (first 3 months of the pathology), the recommendation is rather to observe the condition and attempt to reduce risk factors. It is appropriate to reduce or completely discontinue corticoid therapy if the patient uses this therapy chronically, and to adjust the patient's lifestyle, minimizing stress stimuli, and if applicable also to administer conservative therapy. However, situations exist in which therapy should be applied earlier. These are for example when the patient has high demands for improvement of vision (drivers by occupation, graphic artists etc.), recurrent form of the disease or in the case that untreated CSC in the contralateral eye has led to a significant deterioration of vision.

### Medicamentous therapy

Although a range of studies have been conducted to examine the effect of orally administered pharmaceuticals, no causal medication exists at the present time. No positive influence has been demonstrated in the case of beta-blockers, anxiolytics, antidepressants, non-steroid antiphlogistic drugs, resorptive drugs, vasoprotectives or vitamin therapy [123]. Corticosteroids previously used as standard for the conservative treatment of CSC are no longer recommended whatsoever, since in the literature there are a whole range of studies indicating that general and parabolbar administration of corticoids may provoke the onset of CSC [35,66]. Long-term corticoid therapy is linked to prolonged presence of SRF and diffuse changes of the RPE, and in patients who for whatever reason are unable to reduce their dose of corticoids, we frequently struggle with a protracted, chronic pathology that responds to treatment only with difficulty. Care for these patients requires interdisciplinary cooperation, and the recommendation of an ophthalmologist for patients with CSC whose condition of health so permits is to discontinue long-term corticoid therapy or replace it with alternative treatment (e.g. biological therapy). Alkin et al. present the case of a positive effect of nepafenac 0.1% in the treatment of acute forms of CSC [124]. New observations have appeared in the literature attesting to the positive effect of mineralocorticoid receptor antagonists, especially eplerenone. According to recent results of clinical trials, eplerenone influences a number of pathophysiological pathways, thereby supporting the more rapid absorption of

fluid, and is more effective in chronic states [125,126]. In the case of extensive RPE atrophies, however, its effectiveness is limited [127]. Further prospective clinical trials are essential in order to confirm its safety and efficacy, and to determine which clinical forms of CSC would profit from treatment with eplerenone.

### Laser therapy

Conventional argon laser therapy has been used for several years in order to manage both the acute and chronic phase of CSC [16]. With regard to the large percentage of spontaneous resorption of SRF, the recommendation is to wait 3 months from the onset of the pathology before intervention [128]. If spontaneous reattachment of the neuroretina does not take place and the point of leakage is sufficiently distant from the center of the fovea (more than 500  $\mu\text{m}$ ), direct laser photocoagulation of the leaking point is indicated (hyperfluorescence according to FAG). If the hot-spot is less than 500  $\mu\text{m}$  from the center of the fovea, or if diffuse affliction of the RPE is already expressed, the recommendation is to select an alternative therapeutic approach [128]. Following laser coagulation of the hot-spot, in uncomplicated cases anatomical reattachment of the neuroretina usually takes place within 2 weeks of the performance of the procedure. Adjustment of central VA as a rule requires twice that amount of time. Photocoagulation usually reduces the period of duration of the pathology and accelerates resorption of the SRF, but has no influence on resulting VA [129].

The aim of laser photocoagulation is the scarring of the defective RPE through which fluid is penetrating into the subretinal space. Targeted point laser coagulation of the hot-spot is performed on the basis of prior fluorescein (or indocyanine green) angiography. The principle of the dual healing effect of the photocoagulation laser is a direct thermal effect, as well as secondary expansion of the RPE cells from the surrounding healthy tissue and healing of the RPE defect [130]. In the place of application of the laser beam, the thermal destruction of tissue and the adjacent neurosensory retina takes place, and absolute scotoma may appear in the place of treatment. Potential adverse effects of laser photocoagulation should be taken into consideration, especially if it is necessary to use a laser in close proximity to the fovea or in the papillomacular bundle. Further potential complications include accidental shot of the fovea, hemorrhage, fibrosis, secondarily occurring CNV, slow progressive enlargement of RPE atrophy of the original laser spot (enlargement of the laser spot may in time affect the fovea and cause irreversible loss of VA) [16].

A modality to a conventional laser is a subthreshold or micropulse laser. The principle of a micropulse laser is the division of the continual laser beam of a wavelength of 810 nm (or 577 nm) into individual micropulses separated by a pause, thus minimizing the generation of thermal energy that has a mutilating effect on the tissue in the treated and surrounding area. It supports the biological response of the tissue, which leads to a restoration of the integrity and physiological function of the RPE cells, with resorption of the SRF.

Subthreshold diode micropulse laser therapy may be a safe and effective therapeutic modality for cCSC in future [118].

### Photodynamic therapy – PDT

In addition to laser therapy, photodynamic therapy has also been used successfully in recent years. It was introduced into practice based on the idea that CSC primarily affects the choroid. PDT was originally used in the treatment of solid tumors, and later in the treatment of wet form ARMD [131]. Positive results of treatment of chronic form of CSC by photodynamic therapy with the use of the photosensitizing substance verteporfin were first published by Yannuzzi and Piccolino in 2003 [77,132]. Since that time, the safety and effectiveness of ICG-navigated PDT in the treatment of CSC has been confirmed by a series of clinical trials [11,13,135–136].

The principle of PDT consists in the intravenous administration of the photosensitizing substance verteporfin (Visudyne, Novartis AG, Bülach, Switzerland), and its activation through the use of laser light in red wavelengths. Because the induction of the photochemical reaction takes place intravenously, there is no thermal damage to the tissue during PDT. In the place of irradiation, PDT induces constriction of the choroidal vessels, leading to their modification, reduces choroidal perfusion, and as a consequence of these changes reduces choroidal exudation [137,138]. According to the conclusions of clinical trials, PDT enables more rapid resorption of the SRF in comparison with the group of patients who are treated with laser photocoagulation [132,139]. In order to determine the precise localization and extent of the lesion, the results of ICG (medium venous phase) are used, according to which the laser spot is targeted precisely at the zone(s) of hyperfluorescence during the treatment [94,140]. PDT may be applied in the standard dose and length of irradiation of the lesion, which is used in the treatment of wet form ARMD (parameters according to TAP study: laser beam with a wavelength of 689 nm applied for a period of 83 seconds in exposure of 600  $\text{mW}/\text{cm}^2$ , within 5 minutes of the end of intravenous infusion of verteporfin – in a dose of 6  $\text{mg}/\text{m}^2$ , energy 50  $\text{J}/\text{cm}^2$ ) [137]. With regard to the potential danger posed by standard PDT treatment (deterioration of VA, wider destruction of normal or already breached RPE with atrophic changes, potential choroidal ischemia, risk of development of secondary CNV), in recent years priority has been given to alternative dosing regimens of verteporfin and the used laser beam, known as “safety-enhanced” PDT. Either a reduced dose of radiation is used in “reduced (half)-fluence” (HF-PDT – 42 seconds, or half energy– 25  $\text{J}/\text{cm}^2$ ), or a reduced dose of verteporfin in “reduced (half)-dose” (HD-PDT, i.e. 3  $\text{mg}/\text{m}^2$  of Visudyne) [12,28,128,133,141].

The results of studies comparing “safety-enhanced” PDT and conventional PDT are comparable. While achieving a similar anatomical and functional effect, “safety-enhanced” PDT minimizes the harmful effect on the perfusion of the choriocapillaris and its atrophying influence on the RPE and thickness of the retina [12,133]. The authors Nicoló and Kim in their publications compared the functional and anatomical results in patients with cCSC treated using HF-PDT and HD-

-PDT. Both authors present findings that no statistically significant differences exist in the anatomical or functional results between these therapeutic modalities, Nicoló merely states more rapid absorption of SRF in the case of HD-PDT [10,141].

Thanks to its positive results and satisfactory safety profile as demonstrated by the clinical trials conducted to date, reduced PDT is considered the treatment of first choice, although it remains off-label in indication for CSC [142,143].

### Anti-VEGF therapy

With regard to the pathophysiology of the disease, the use of anti-VEGF agents is contentious in the treatment of CSC. A series of clinical trials have provided ambiguous results of the effect of anti-VEGF agents in the treatment of CSC [18,144,145]. The pathology itself is not associated with a higher level of VEGF in the vitreous, and the effect of anti-VEGF treatment for CSC without the presence of CNV has not been demonstrated overall [146]. However, a different situation applies in complicated cases of secondary CNV upon a background of CSC. In the last 5 years especially, when thanks to advances in multimodal imaging (OCT-A) it has become possible to demonstrate CNV associated with CSC pathology with far greater sensitivity and specificity, the use of anti-VEGF agents in these cases has gained ever-increasing significance, and in the most severe conditions in combination with PDT [147]. Previous clinical trials have demonstrated an anatomical and functional effect of bevacizumab, ranibizumab and aflibercept in the treatment of CNV associated with CSC [146,148,149]. However, only limited data exists documenting the safety and efficacy of combined PDT and anti-VEGF treatment. Asahi demonstrated positive results of combined therapy with HD-PDT + aflibercept in patients who were unresponsive to conventional tre-

atment (laser photocoagulation, monotherapy with PDT, monotherapy with anti-VEGF), and recorded greater success above all in eyes complicated by CNV [150].

Ranibizumab is the only registered pharmaceutical in the Czech Republic that may be used in the treatment of rare forms of CNV, thus also those upon a background of CSC.

### Other therapeutic alternatives

Despite the fact that no causal medicamentous therapy exists in the treatment of CSC, a series of smaller clinical trials have demonstrated positive results in the treatment of CSC upon the use of finasteride (dihydrotestosterone synthesis inhibitor) in a dose of 5mg per day or acetylsalicylic acid acting against choroidal vascular congestion, ischemia and inflammatory changes accompanying CSC [28]. Good results may also be attained by eradicating infection of *Helicobacter pylori* in indicated cases and treatment of obstructive sleep apnea as potential risk factors triggering this disease [28,35].

## CONCLUSION

Today's technical advances in the diagnosis and treatment of CSC in combination with our own clinical experiences represent a substantial improvement in the prognosis for our patients with CSC, for whom it is necessary to ensure not only correct diagnosis of the pathology based upon multimodal imaging, but above all correct setting and timing of adequate treatment. From our results to date it also ensues that treatment of chronic forms of CSC should be commenced in the early stages in order for us to attain the best possible anatomical and functional results, before irreversible changes are expressed such as DRPE or complicating CNV.

## REFERENCES

1. Atlas of Macular Diseases: Gass JDM. Stereoscopic Diagnosis and Treatment. 4th edition: Mosby, 1997.1061,52-70. ISBN: 978-0815134169.
2. Haimovici R, Rumelt S, Melby J. Endocrine abnormalities in patients with central serous chorioretinopathy. *Ophthalmology*. 2003;110(4):698-703.
3. Spaide RF, Campeas L, Haas A, et al. Central serous chorioretinopathy in younger and older adults. *Ophthalmology*. 1996;103(12):2070-2079.
4. Imamura Y, Fujiwara T, Margolis R, Spaide RF. Enhanced depth imaging optical coherence tomography of the choroid in central serous chorioretinopathy. *Retina*. 2009;29(10):1469-1473.
5. Leaver P, Williams C. Argon laser photocoagulation in the treatment of central serous retinopathy. *Br J Ophthalmol*. 1979;63(10):674-677.
6. Pikkil J, Beiran I, Ophir A, Miller B. Acetazolamide for central serous retinopathy. *Ophthalmology*. 2002;109(9):1723-1725.
7. Golshahi A, Klingmuller D, Holz FG, Nicole ER. Ketoconazole in the treatment of central serous chorioretinopathy: a pilot study. *Acta Ophthalmol*. 2010;88(5):576-581.
8. Chan WM, Lam DS, Lai TY, Tam BSM, Liu DTL, Chan CKM. Choroidal vascular remodelling in central serous chorioretinopathy after indocyanine green guided photodynamic therapy with verteporfin: a novel treatment at the primary disease level. *Br J Ophthalmol*. 2003;87(12):1453-1458.
9. Huang WC, Chen WL, Tsai YY, et al. Intravitreal bevacizumab for treatment of chronic central serous chorioretinopathy. *Eye (Lond)*. 2009;23(2):488-489.
10. Kim YK, Ryoo NK, Woo SJ, Park KH. Comparison of visual and anatomical outcomes of half-fluence and half-dose photodynamic therapy in eyes with chronic central serous chorioretinopathy. *Graefes Arch Clin Exp Ophthalmol*. 2015;253(12):2063-2073.
11. Karakus SH, Basarir B, Pinarci EY, et al. Long-term results of half-dose photodynamic therapy for chronic central serous chorioretinopathy with contrast sensitivity changes. *Eye (Lond)*. 2013;27(5):612-620.
12. Reibaldi M, Cardascia N, Longo A, et al. Standard-fluence versus low-fluence photodynamic therapy in chronic central serous chorioretinopathy: a nonrandomized clinical trial. *Am J Ophthalmol*. 2010;149(2):307-315 e2.
13. Alkin Z, Perente I, Ozkaya A, et al. Comparison of efficacy between low-fluence and half-dose verteporfin photodynamic therapy for chronic central serous chorioretinopathy. *Clin Ophthalmol*. 2014;8:685-690.
14. Chan WM, Lai TY, Lai RY, et al. Safety enhanced photodynamic therapy for chronic central serous chorioretinopathy: one-year results of a prospective study. *Retina*. 2008;28(1):85-93.
15. Uetani R, Ito Y, Oiwa K, et al. Half-dose vs one-third-dose photodynamic therapy for chronic central serous chorioretinopathy. *Eye (Lond)*. 2012;26(5):640-649.
16. L'Esperance FA. *Ophthalmic lasers: Photocoagulation, photoradiation, and surgery*. second edition edition, St. Louis, Missouri (USA): The C.V. Mosby Company, 1983, p.606. ISBN: 978-0801628238.

17. Lim JI, Glassman AR, Aiello LP, et al. Collaborative retrospective macula society study of photodynamic therapy for chronic central serous chorioretinopathy. *Ophthalmology*. 2014;121(5):1073-1078.
18. Lim SJ, Roh MI, Kwon OW, Woong OH. Intravitreal bevacizumab injection for central serous chorioretinopathy. *Retina*. 2010;30(1):100-106.
19. von Graefe A, Kurzere A. Notizen und casaistische Mittheilungen vermischen Inhalts: VI. Ueber zentrale recidivirende retinitis. *Albrecht von Graefes Arch Klin Exp Ophthalmol*. 1866;12:211-215.
20. Bennet G. Central serous retinopathy. *Br J Ophthalmol*. 1955;39:605-618.
21. Maumenee AE. Macular Diseases: Clinical Manifestations. *Trans Am Acad Ophthalmol Otolaryngol*. 1965;69:605-613.
22. Gass JDM. Pathogenesis of disciform detachment of the neuroepithelium: II. Idiopathic central serous choroidopathy. *Am J Ophthalmol*. 1967;63:587-615.
23. Ryan SJ. *Retina*. Volume II, 4th edition, Baltimore (USA): Elsevier Mosby, 2006. 1889, 1135-1161. ISBN: 9780323025980.
24. Gallego-Pinazo R, Dolz-Marco R, Gomez-Ulla F, Mrejen S, Freund KB. Pachychoroid diseases of the macula. *Med Hypothesis Discov Innov Ophthalmol*. 2014;3(4):111-115.
25. Lehmann M, Bousquet E, Beydoun T, et al. Pachychoroid: an inherited condition? *Retina*. 2015;35(1):10-16.
26. How AC, Koh AH. Angiographic characteristics of acute central serous chorioretinopathy in an Asian population. *Ann Acad Med Singapore*. 2006;35(2):77-79.
27. Kunavisarut P, Pathanapitoon K, van Schooneveld M, Rothova A. Chronic central serous chorioretinopathy associated with serous retinal detachment in a series of Asian patients. *Ocul Immunol Inflamm*. 2009;17(4):269-277.
28. Colucciello M. Update on Central Serous Chorioretinopathy: Among other findings, reduce-fluence and low-dose PDT look promising. *Retinal Physician*. 2012;42-47,75-76.
29. Kitzmann AS, Pulido JS, Diehl NN, Hodge DO, Burke JJ. The incidence of central serous chorioretinopathy in Olmsted County, Minnesota, 1980-2002. *Ophthalmology*. 2008;115(1):169-173.
30. Spaide RF, Hall L, Haas A, et al. Indocyanine green videoangiography of older patients with central serous chorioretinopathy. *Retina*. 1996;16(3):203-213.
31. Bouzas EA, Scott MH, Mastorakos G, Chrousos GP, MD; Kaiser-Kupfer MI. Central serous chorioretinopathy in endogenous hypercortisolism. *Arch Ophthalmol*. 1993;111(9):1229-1233.
32. Bouzas EA, Karadimas P, Pournaras CJ. Central serous chorioretinopathy and glucocorticoids. *Surv Ophthalmol*. 2002;47(5):431-448.
33. Harada T, Harada K. Six cases of central serous choroidopathy induced by systemic corticosteroid therapy. *Doc Ophthalmol*. 1985;60(1):37-44.
34. Chung H, Kim KH, Kim JG, Lee SY, Yoon YH. Retinal complications in patients with solid organ or bone marrow transplantations. *Transplantation*. 2007;83(6):694-699.
35. Haimovici R, Koh S, Gagnon DR, et al. Risk factors for central serous chorioretinopathy: a case-control study. *Ophthalmology*. 2004;111(2):244-249.
36. Horniker E. Su di unaforma di retinite central di originevasoneurotica. *Ann Ottalmol*. 1927;55:830-840.
37. Yannuzzi LA. Type A behavior and central serous chorioretinopathy. *Trans Am Ophthalmol Soc*. 1986;84:799-845.
38. Aliferis K, Petropoulos IK, Farpour B, et al. Should central serous chorioretinopathy be added to the list of ocular side effects of phosphodiesterase 5 inhibitors? *Ophthalmologica*. 2012;227(2):85-89.
39. Michael JC, Pak J, Pulido J, de Venecia G. Central serous chorioretinopathy associated with administration of sympathomimetic agents. *Am J Ophthalmol*. 2003;136(1):182-185.
40. Mateo-Montoya A, Mauget-Fayse M. *Helicobacter pylori* as a risk factor for central serous chorioretinopathy: Literature review. *World J Gastrointest Pathophysiol*. 2014;5(3):355-358.
41. Misiuk-Hojlo M, Michalowska M, Turno-Krecicka A. *Helicobacter pylori* - a risk factor for the development of the central serous chorioretinopathy. *Klin Oczna*. 2009;111(1-3):30-32.
42. Tittl MK, Spaide RF, Wong D, et al. Systemic findings associated with central serous chorioretinopathy. *Am J Ophthalmol*. 1999;128(1):63-68.
43. Moschos MM, Gazouli M, Gatziofay Z, et al. Prevalence of the Complement Factor H and Gstm1 Genes Polymorphisms in Patients with Central Serous Chorioretinopathy. *Retina*. 2016;36(2):402-407.
44. Miki A, Kondo N, Yanagisawa S, Bessho H, Honda S, Negi A. Common variants in the complement factor H gene confer genetic susceptibility to central serous chorioretinopathy. *Ophthalmology*. 2014;121(5):1067-1072.
45. de Jong EK, Breukink MB, Schellevis RL, et al. Chronic central serous chorioretinopathy is associated with genetic variants implicated in age-related macular degeneration. *Ophthalmology*. 2015;122(3):562-570.
46. Schellevis RL, Van Dijk EHC, Breukink MB, et al. Role of the complement system in chronic central serous chorioretinopathy: a genome-wide association study. *JAMA Ophthalmol*. 2018;136(10):1128-1136.
47. Yannuzzi LA. Central serous chorioretinopathy: a personal perspective. *Am J Ophthalmol*. 2010;149(3):361-363.
48. Schachat APW, C.P.; Hinton, D.R. *Ryan's Retina*. Volume II, 6th edition edition: Elsevier, 2018. 2976. ISBN: 978-0-323-40197-5.
49. Ooto S, Hangai M, Sakamoto A, et al. High-resolution imaging of resolved central serous chorioretinopathy using adaptive optics scanning laser ophthalmoscopy. *Ophthalmology*. 2010;117(9):1800-1809, 1809 e1-2.
50. Yap EY, Robertson DM. The long-term outcome of central serous chorioretinopathy. *Arch Ophthalmol*. 1996;114(6):689-692.
51. Spaide RF, Goldbaum M, Wong DW, Tang KC, Iida, T. Serous detachment of the retina. *Retina*. 2003;23(6):820-846; quiz 895-896.
52. Prunte C, Flammer J. Choroidal capillary and venous congestion in central serous chorioretinopathy. *Am J Ophthalmol*. 1996;121(1):26-34.
53. Guyer DR, Yannuzzi LA, Slakter JS, Slakter JS, Sorenson JA, Orlock D. Digital indocyanine green videoangiography of central serous chorioretinopathy. *Arch Ophthalmol*. 1994;112(8):1057-1062.
54. Spitznas M. Pathogenesis of central serous retinopathy: a new working hypothesis. *Graefes Arch Clin Exp Ophthalmol*. 1986;224(4):321-324.
55. Slakter JS, Yannuzzi LA, Guyer DR, Sorenson JA, Orlock DA. Indocyanine-green angiography. *Current Opinion in Ophthalmology*. 1995;6(3):25-32.
56. Hayashi K, Hasegawa Y, Tokoro T. Indocyanine green angiography of central serous chorioretinopathy. *Int Ophthalmol*. 1986;9(1):37-41.
57. Tomasso L, Benatti L, Rabiolo A, et al. Retinal vessels functionality in eyes with central serous chorioretinopathy. *Br J Ophthalmol*. 2018;102(2):210-214.
58. Tittl M, Maar N, Polska E, Weigert G, Stur M. Choroidal hemodynamic changes during isometric exercise in patients with inactive central serous chorioretinopathy. *Invest Ophthalmol Vis Sci*. 2005;46(12):4717-4721.
59. Cheung CMG, Lee WK, Koizumi H, Dansingani K, Lai TYY, Freund KB. Pachychoroid disease. *Eye Lond Engl*. 2019;33(1):14-33. doi: 10.1038/s41433-018-0158-4
60. Negi A, Marmor MF. Mechanisms of subretinal fluid resorption in the cat eye. *Invest Ophthalmol Vis Sci*. 1986;27(11):1560-1563.
61. Wang C, Cao G-F, Jiang Q, Yao J. TNF- $\alpha$  promotes human retinal pigment epithelial (RPE) cell migration by inducing matrix metalloproteinase 9 (MMP-9) expression through activation of Akt/mTORC1 signaling. *Biochem Biophys Res Commun*. 2012;425(1):33-38.
62. Wakakura M, Ishikawa S. Central serous chorioretinopathy complicating systemic corticosteroid treatment. *Br J Ophthalmol*. 1984;68(5):329-331.
63. Polak BC, Baarsma GS, Snyers B. Diffuse retinal pigment epitheliopathy complicating systemic corticosteroid treatment. *Br J Ophthalmol*. 1995;79(10):922-925.
64. Haimovici R, Gragoudas ES, Duker JS, Sjaarda RN, Elliott D. Central serous chorioretinopathy associated with inhaled or intranasal corticosteroids. *Ophthalmology*. 1997;104(10):1653-1660.
65. Garg SP, Dada T, Talwar D, Biswas NR. Endogenous cortisol profile in patients with central serous chorioretinopathy. *Br J Ophthalmol*. 1997;81(11):962-964.
66. Carvalho-Recchia CA, Yannuzzi LA, Negrao S, et al. Corticosteroids and central serous chorioretinopathy. *Ophthalmology*. 2002;109(10):1834-1837.
67. Jampol LM, Weinreb R, Yannuzzi L. Involvement of corticosteroids and catecholamines in the pathogenesis of central serous chorioretinopathy: a rationale for new treatment strategies. *Ophthalmology*. 2002;109(10):1765-1766.
68. Godel V, Blumenthal M, Regenbogen L. Retrobulbar neuritis and central serous chorioretinopathy. *J Pediatr Ophthalmol*. 1977;14(5):296-298.
69. Chaine G, Haouat M, Menard-Molcard C, et al. [Central serous

- chorioretinopathy and systemic steroid therapy]. *J Fr Ophtalmol*. 2001;24(2):139-146.
70. Bouzas EA, Moret P, Pournaras CJ. Central serous chorioretinopathy complicating solar retinopathy treated with glucocorticoids. *Graefes Arch Clin Exp Ophthalmol*. 1999;237(2):166-168.
71. Gass JD, Slamovits TL, Fuller DG, Gieser RG, Lean JS. Posterior chorioretinopathy and retinal detachment after organ transplantation. *Arch Ophthalmol*. 1992;110(12):1717-1722.
72. Hadcock JR, Malbon CC. Regulation of beta-adrenergic receptors by „permissive“ hormones: glucocorticoids increase steady-state levels of receptor mRNA. *Proc Natl Acad Sci USA*. 1988;85(22):8415-8419.
73. Sakaue M, Hoffman BB. Glucocorticoids induce transcription and expression of the alpha 1B adrenergic receptor gene in DTT1 MF-2 smooth muscle cells. *J Clin Invest*. 1991;88(2):385-389.
74. Makara GB, Haller J. Non-genomic effects of glucocorticoids in the neural system. Evidence, mechanisms and implications. *Prog Neurobiol*. 2001;65(4):367-390.
75. Yoshioka H, Katsume Y, Akune H. Experimental central serous chorioretinopathy in monkey eyes: fluorescein angiographic findings. *Ophthalmologica*. 1982;185(3):168-178.
76. Iida T, Yannuzzi LA, Spaide RF, Borodoker N, Carvalho CA, Negrão S. Cystoid macular degeneration in chronic central serous chorioretinopathy. *Retina*. 2003;23(1):1-7.
77. Piccolino FC, Eandi CM, Ventre L, Rigault De La Longrais, RC. Grignolo, FM. Photodynamic therapy for chronic central serous chorioretinopathy. *Retina*. 2003;23(6):752-763.
78. Piccolino FC, de la Longrais RR, Ravera G, et al. The foveal photoreceptor layer and visual acuity loss in central serous chorioretinopathy. *Am J Ophthalmol*. 2005;139(1):87-99.
79. Daruich A, Matet A, Dirani A, et al. Central serous chorioretinopathy: recent findings and new physiopathology hypothesis. *Prog Retin Eye Res*. 2015;48:82-118.
80. Chhablani J. Central serous chorioretinopathy. Elsevier Science, 2019.27-34. ISBN: 9780128168004.
81. Baran NV, Gurlu VP, Esgin H. Long-term macular function in eyes with central serous chorioretinopathy. *Clin Exp Ophthalmol*. 2005;33(4):369-372.
82. Aggio FB, Roisman L, Melo GB, Lavinsky D, Cardillo JA, Farah ME. Clinical factors related to visual outcome in central serous chorioretinopathy. *Retina*. 2010;30(7):1128-1134.
83. Maruko I, Iida T, Sekiryu T, Saito M. Morphologic changes in the outer layer of the detached retina in rhegmatogenous retinal detachment and central serous chorioretinopathy. *Am J Ophthalmol*. 2009;147(3):489-494 e1.
84. Yannuzzi LA, Slakter JS, Kaufman SR, Gupta K. Laser treatment of diffuse retinal pigment epitheliopathy. *Eur J Ophthalmol*. 1992;2(3):103-114.
85. Stefaniotou M, Vourda E, Katsanos A, Aspiotis M. Multifocal central serous chorioretinopathy associated with steroids in a patient with myasthenia gravis. *Case Rep Ophthalmol*. 2013;4:1-6.
86. Quaranta-El Maftouhi M, El Maftouhi A, Eandi CM. Chronic central serous chorioretinopathy imaged by optical coherence tomographic angiography. *Am J Ophthalmol*. 2015;160(3):581-587 e1.
87. Bousquet E, Bonnin S, Mrejen S, Krivosic V, Tadayoni R, Gaudric A. Optical Coherence Tomography Angiography of Flat Irregular Pigment Epithelium Detachment in Chronic Central Serous Chorioretinopathy. *Retina*. 2018;38(3):629-638.
88. Bonini Filho MA, de Carlo TE, Ferrara D, et al. Association of Choroidal Neovascularization and Central Serous Chorioretinopathy With Optical Coherence Tomography Angiography. *JAMA Ophthalmol*. 2015;133(8):899-906.
89. Costanzo E, Cohen SY, Miere A, et al. Optical Coherence Tomography Angiography in Central Serous Chorioretinopathy. *J Ophthalmol*. 2015;2015:134783.
90. Balaratnasingam C, Freund KB, Tan AM, Sarraf D, Jampol LM, Yannuzzi LA. Bullous variant of central serous chorioretinopathy: expansion of phenotypic features using multimethod imaging. *Ophthalmology*. 2016;123(7):1541-1552.
91. Yannuzzi LA, Shakin JL, Fisher YL, Altomonte MA. Peripheral retinal detachments and retinal pigment epithelial atrophic tracts secondary to central serous pigment epitheliopathy. *Ophthalmology*. 1984;91(12):1554-1572.
92. Coscas G. Atlas of Indocyanine Green Angiography: Fluorescein Angiography, ICG Angiography and OCT Correlations. Paris: Elsevier SAS, 2005. 383, 203-225. ISBN: 2-84299-729-8.
93. Holz FG. Fluorescence Angiography in Ophthalmology: Fluorescein Angiography, Indocyanine Green Angiography, Fundus Autofluorescence. Springer-Verlag Berlin Heidelberg, 2008. 224, 118-121. ISBN: 978-3-540-78359-6.
94. Piccolino FC, Borgia L. Central serous chorioretinopathy and indocyanine green angiography. *Retina*. 1994;14(3):231-242.
95. Stanga PE, Lim JH, Hamilton P. Indocyanine green angiography in chorioretinal diseases: an evidenced-based update. *Ophthalmology*. 2003;110(1):15-21.
96. Yannuzzi LA. Indocyanine green angiography: a perspective on use in the clinical setting. *Am J Ophthalmol*. 2011;151(1):745751. e1.
97. Iida T, Hagimura N, Sato T, Kishi S. Evaluation of central serous chorioretinopathy with optical coherence tomography. *Am J Ophthalmol*. 2000;129(1):16-20.
98. Ahlers C, Geitzenauer W, Stock G, Golbaz I, Schmidt-Erfurth U, Prunte C. Alterations of intraretinal layers in acute central serous chorioretinopathy. *Acta Ophthalmol*. 2009;87(5):511-516.
99. Yang L, Jonas JB, Wei W. Optical coherence tomography-assisted enhanced depth imaging of central serous chorioretinopathy. *Invest Ophthalmol Vis Sci*. 2013;54(7):4659-4665.
100. Shin YU, Lee BR. Retro-mode imaging for retinal pigment epithelium alterations in central serous chorioretinopathy. *Am J Ophthalmol*. 2012;154(1):155-163.
101. Kon Y, Iida T, Maruko I, Saito M. The optical coherence tomography-ophthalmoscope for examination of central serous chorioretinopathy with precipitates. *Retina*. 2008;28(6):864-869.
102. Yalcinbayir O, Gelissen O, Akova-Budak B, et al. Correlation of spectral domain optical coherence tomography findings and visual acuity in central serous chorioretinopathy. *Retina*. 2014;34(4):705-712.
103. Iacono P, Battaglia PM, Papayannis A, La Spina C, Varano M, Bandello F. Acute central serous chorioretinopathy: a correlation study between fundus autofluorescence and spectral-domain OCT. *Graefes Arch Clin Exp Ophthalmol*. 2015;253(11):1889-1897.
104. Landa G, Barnett JA, Garcia PM, Tai KW, Rosen RB. Quantitative and qualitative spectral domain optical coherence tomography analysis of subretinal deposits in patients with acute central serous retinopathy. *Ophthalmologica*. 2013;230(2):62-68.
105. Yang L, Jonas JB, Wei W. Choroidal vessel diameter in central serous chorioretinopathy. *Acta Ophthalmol*. 2013;91(5):e358-62.
106. Spaide RF, Koizumi H, Pozzoni MC. Enhanced depth imaging spectral-domain optical coherence tomography. *Am J Ophthalmol*. 2008;146(4):496-500.
107. Jirarattanasopa P, Ooto S, Tsujikawa A, Hirata M, Matsumoto A, Yoshimura N. Assessment of macular choroidal thickness by optical coherence tomography and angiographic changes in central serous chorioretinopathy. *Ophthalmology*. 2012;119(8):1666-1678.
108. Teussink MM, Breukink MB, van Grinsven MJ, Hoyng CB, Klevering BJ. OCT angiography compared to fluorescein and indocyanine green angiography in chronic central serous chorioretinopathy. *Invest Ophthalmol Vis Sci*. 2015;56:5229-5237.
109. Chan SY, Wang Q, Wei WB, Jonas JB. Optical Coherence Tomographic Angiography in Central Serous Chorioretinopathy. *Retina*. 2016;36(11):2051-2058.
110. Rabiolo A, Zucchiatti I, Marchese A, et al. Multimodal retinal imaging in central serous chorioretinopathy treated with oral eplerenone or photodynamic therapy. *Eye (Lond)*. 2018;32(1):55-66.
111. Pichi F, Morara M, Veronesi C, Ciardella AP. The overlapping spectrum of flat irregular pigment epithelial detachment investigated by optical coherence tomography angiography. *Int Ophthalmol*. 2018;38(3):975-983.
112. Kim SK, Kim SW, Oh J, Huh K. Near-infrared and short-wavelength autofluorescence in resolved central serous chorioretinopathy: association with outer retinal layer abnormalities. *Am J Ophthalmol*. 2013;156(1):157-164 e2.
113. Zhang P, Wang HY, Zhang ZF, et al. Fundus autofluorescence in central serous chorioretinopathy: association with spectral-domain optical coherence tomography and fluorescein angiography. *Int J Ophthalmol*. 2015;8(5):1003-1007.
114. Framme C, Walter A, Gabler B, Roeder J, Sachs HG, Gabel VP. Fundus autofluorescence in acute and chronic-recurrent central serous chorioretinopathy. *Acta Ophthalmol Scand*. 2005;83(2):161-167.
115. Holz FG, Bindewald-Wittich A, Fleckenstein M, Scholl HPN, Steffen Schmitz-Valckenberg-Fam-Study Group. Progression of geographic atrophy and impact of fundus autofluorescence patterns in age-related macular degeneration. *Am J Ophthalmol*. 2007;143(3):463-472.
116. Maruko I, Iida T, Ojima A, Sekiryu T. Subretinal dot-like precipitates and yellow material in central serous serous chorioretinopathy.

- Retina. 2011;31(4):759-765.
117. Ehrlich R, Mawer NP, Mody CH, Brand CS, Squirrel D. Visual function following photodynamic therapy for central serous chorioretinopathy: a comparison of automated macular microperimetry versus best-corrected visual acuity. *Clin Exp Ophthalmol*. 2012;40(1):e32-39.
118. Maia A. A New Treatment for Chronic Central Serous Retinopathy: Micropulse yellow laser resolves leakage and retinal detachment without scarring or retinal damage. *Retina Today*. 2010;2:62-64.
119. Yip YW, Ngai JW, Fok AC, et al. Correlation between functional and anatomical assessments by multifocal electroretinography and optical coherence tomography in central serous chorioretinopathy. *Doc Ophthalmol*. 2010;120(2):193-200.
120. Lai TY, Lai RY, Ngai JW, Chan WM, Li H, Lam DSC. First and second-order kernel multifocal electroretinography abnormalities in acute central serous chorioretinopathy. *Doc Ophthalmol*. 2008;116(1):29-40.
121. Caccavale A, Romanazzi F, Imparato M, et al. Central serous chorioretinopathy: a pathogenetic model. *Clin Ophthalmol*. 2011;5:239-243.
122. Klein ML, Van Buskirk EM, Friedman E, Gragoudas ES, Chandra SR. Experience with nontreatment of central serous choroidopathy. *Arch Ophthalmol*. 1974;91(4):247-250.
123. Chrapek O, Rehak J. Léčba centrální serózní chorioretinopatie-naše zkušenosti. [Treatment of central serous chorioretinopathy-personal experience]. *Cesk Slov Oftalmol*. 2002;58(1):51-56. Czech.
124. Alkin Z, Osmanbasoglu OA, Ozkaya A, Karatas G, Yazici AT, Demirok A. Topical nepafenac in treatment of acute central serous chorioretinopathy. *Med Hypothesis Discov Innov Ophthalmol*. 2013;2(4):96-101.
125. Schwartz R, Habot-Wilner Z, Martinez MR, et al. Eplerenone for chronic central serous chorioretinopathy-a randomized controlled prospective study. *Acta Ophthalmol*. 2017;95(7):e610-e618.
126. Rahimy E, Pitcher JD, 3rd, Hsu J, et al. A Randomized Double-Blind Placebo-Control Pilot Study of Eplerenone for the Treatment of Central Serous Chorioretinopathy (Ecselsior). *Retina*. 2018;38(5):962-969.
127. Cakir B, Fischer F, Ehlen C, et al. Clinical experience with eplerenone to treat chronic central serous chorioretinopathy. *Graefes Arch Clin Exp Ophthalmol*. 2016;254(11):2151-2157.
128. Boscia F. When to treat and when not to treat patient with central serous retinopathy. *Retina Today*. [online], April 2010. Available from: <https://retinatoday.com/articles/2010-apr/when-to-treat-and-not-to-treat-patients-with-central-serous-retinopathy>
129. Gilbert CM, Owens SL, Smith PD, Fine SL. Long-term follow-up of central serous chorioretinopathy. *Br J Ophthalmol*. 1984;68(11):815-820.
130. Gass JD. Pathogenesis of disciform detachment of the neuroepithelium. *Am J Ophthalmol*. 1967;63(3 Suppl):1-139.
131. Dougherty TJ, Gomer CJ, Henderson BW, et al. Photodynamic therapy. *J Natl Cancer Inst*. 1998;90(12):889-905.
132. Yannuzzi LA, Slakter JS, Gross NE, et al. Indocyanine green angiography-guided photodynamic therapy for treatment of chronic central serous chorioretinopathy: a pilot study. *Retina*. 2003;23(3):288-298.
133. Koss M. Treating Chronic Central Serous Chorioretinopathy: The goal is a treatment with increased Access and decreased effects. *Retina Today*. 2013;8:68-70.
134. Lai TY, Chan WM, Li H, Lai RYK, Liu DTL, Lam DSC. Safety enhanced photodynamic therapy with half dose verteporfin for chronic central serous chorioretinopathy: a short term pilot study. *Br J Ophthalmol*. 2006;90(7):869-874.
135. Fujita K, Imamura Y, Shinoda K, Hashizume K, Mizota A, Yuzawa M. One-year outcomes with half-dose verteporfin photodynamic therapy for chronic central serous chorioretinopathy. *Ophthalmology*. 2015;122(3):555-561.
136. Tseng CC, Chen SN. Long-term efficacy of half-dose photodynamic therapy on chronic central serous chorioretinopathy. *Br J Ophthalmol*. 2015;99(8):1070-1077.
137. Schmidt-Erfurth U, Hasan T. Mechanisms of action of photodynamic therapy with verteporfin for the treatment of age-related macular degeneration. *Surv Ophthalmol*. 2000;45(3):195-214.
138. Schmidt-Erfurth U, Laqua H, Schlotzer-Schrehard U, Viestenz A, Naumann GOH. Histopathological changes following photodynamic therapy in human eyes. *Arch Ophthalmol*. 2002;120(6):835-844.
139. Maier M, Valet V, Feucht N, Lohmann CP. Therapieoption bei chronischer Chorioretinopathia centralis serosa [Therapy options for chronic central serous chorioretinopathy]. *Ophthalmologie*. 2011;108(11):1027-1031. German.
140. Stanga PE, Lim JJ, Hamilton P. Indocyanine green angiography in chorioretinal diseases: indications and interpretation: an evidence-based update. *Ophthalmology*. 2003;110(1):15-21; quiz 22-3.
141. Nicolo M, Eandi CM, Alovici C, et al. Half-fluence versus half-dose photodynamic therapy in chronic central serous chorioretinopathy. *Am J Ophthalmol*. 2014;157(5):1033-1037.
142. van Dijk EHC, Fauser S, Breukink MB, Downes SM, Hoyng CB, Boon CJF. Half-dose photodynamic therapy versus high-density sub-threshold micropulse laser treatment in patients with chronic central serous chorioretinopathy: the PLACE trial. *Ophthalmology*. 2018;125(10):1547-1555.
143. Manethová K, Ernest J, Hrevuš M, Jirásková N. Assessment of the Efficacy of Photodynamic Therapy in Patients with Chronic Central Serous Chorioretinopathy. *Cesk Slov Oftalmol*. 2019;75(6):298-308. doi:10.31348/2019/6/2
144. Bae SH, Heo J, Kim C, Park TK, Moon SW, Chung H. Low-fluence photodynamic therapy versus ranibizumab for chronic central serous chorioretinopathy: one-year results of a randomized trial. *Ophthalmology*. 2014;121(2):558-565.
145. Chan WM, Lai TY, Liu DT, Lam DSC. Intravitreal bevacizumab (avastin) for choroidal neovascularization secondary to central serous chorioretinopathy, secondary to punctate inner choroidopathy, or of idiopathic origin. *Am J Ophthalmol*. 2007;143(6):977-983.
146. Lim JW, Kim MU, Shin MC. Aqueous humor and plasma levels of vascular endothelial growth factor and interleukin-8 in patients with central serous chorioretinopathy. *Retina*. 2010;30(9):1465-1471.
147. Myslík Manethová K, Ernest J. Retrospective analysis of the presence of choroidal neovascularisation using optical coherence tomography angiography in the treatment of chronic central serous chorioretinopathy with the aid of photodynamic therapy. *Cesk Slov Oftalmol*. 2021;77(3):122-131. doi: 10.31348/2021/14
148. Konstantinidis L, Mantel I, Zografos L, Ambresin A. Intravitreal ranibizumab in the treatment of choroidal neovascularization associated with idiopathic central serous chorioretinopathy. *Eur J Ophthalmol*. 2010;20(5):955-958.
149. Broadhead GK, Chang A. Intravitreal aflibercept for choroidal neovascularisation complicating chronic central serous chorioretinopathy. *Graefes Arch Clin Exp Ophthalmol*. 2015;253(6):979-981.
150. Asahi MG, Chon AT, Gallemore E, Gallemore RP. Photodynamic therapy combined with antivascular endothelial growth factor treatment for recalcitrant chronic central serous chorioretinopathy. *Clin Ophthalmol*. 2017;11:2051-2056.

# THERAPY FOR VITREOUS SEEDING CAUSED BY RETINOBLASTOMA. A REVIEW

Kodetová M.<sup>1</sup>, Švojgr K.<sup>2</sup>, Širc J.<sup>3</sup>, Vaněček J.<sup>1</sup>, Pochop P.<sup>1</sup>

<sup>1</sup> Department of Ophthalmology, 2nd Faculty of Medicine, Charles University and Motol University Hospital, Prague, Czech Republic

<sup>2</sup> Department of Pediatric Hematology and Oncology, 2nd Faculty of Medicine, Charles University and Motol University Hospital, Prague, Czech Republic

<sup>3</sup> Institute of Macromolecular Chemistry, Academy of Sciences of the Czech Republic, Prague, Czech Republic

*The authors of the study declare that no conflict of interests exists in the compilation, theme and subsequent publication of this professional article, and that it is not supported by any pharmaceuticals company. The study has not been submitted to in any other journal or published elsewhere.*

Received: March 20, 2023

Accepted: May 3, 2023

Available on-line: July 30, 2023



MUDr. Martina Kodetová  
Oční klinika dětí a dospělých 2. LF  
UK a FN Motol Praha  
V Úvalu 84  
150 06 Praha 5  
E-mail: martina.kodetova@fnmotol.cz

## SUMMARY

Retinoblastoma is the most common primary malignant intraocular tumor in children. Seeding, specifically the dispersion of the tumor into the adjacent compartments, represents a major parameter determining the degree of retinoblastoma according to the International Classification of Retinoblastoma. In this article we focused on vitreous seeding, one of the main limiting factors in the successful "eye preservation treatment" of retinoblastoma. This article presents an overview of the history of vitreous seeding of retinoblastoma, established treatment procedures and new-research modalities. The introduction of systemic chemotherapy in the treatment of retinoblastoma at the end of the 1990s represented a significant breakthrough, which enabled the progressive abandonment of radiotherapy with its attendant side effects. However, the attained concentrations of chemotherapeutics in the vitreous space during systemic chemotherapy are not sufficient for the treatment of vitreous seeding, and the toxic effects of systemic chemotherapy are not negligible. A significant change came with the advent of chemotherapy in situ, with the targeted administration of chemotherapeutic drugs, namely intra-arterial and intravitreal injections, contributing to the definitive eradication of external radiotherapy and a reduction of systemic chemotherapy. Although vitreous seeding remains the most common reason for the failure of intra-arterial chemotherapy, this technique has significantly influenced the original treatment regimen of children with retinoblastoma. However, intravitreal chemotherapy has made the greatest contribution to increasing the probability of preservation of the eyeball and visual functions in patients with advanced findings. Novel local drug delivery modalities, gene therapy, oncolytic viruses and immunotherapy from several ongoing preclinical and clinical trials may represent promising approaches in the treatment of vitreous retinoblastoma seeding, though no clinical trials have yet been completed for routine use.

**Key words:** retinoblastoma, vitreous seeding, eye preservation treatment, intravitreal chemotherapy

Čes. a slov. Oftal., 79, 2023, No. x, p. x–x

## INTRODUCTION

Retinoblastoma (Rb) is the most common malignant intraocular tumor in childhood age, with an incidence of 1 in 13844 born children in European countries [1], while in the Czech Republic it is diagnosed on average in 6 to 7 children annually [2]. According to heredity, the pathology is divided into two forms. Hereditary Rb (approximately 40% of cases), characterized by embryonic mutation of the retinoblastoma (Rb1) gene, is usually diagnosed in children at around the age of one year, and the finding may be either bilateral or multifocal, though in 10–15% of cases is only unilateral. The non-hereditary form of Rb mostly afflicts only one eyeball, forms one lesion, and appears more frequently in older children between 1 and 3 years of

age. These patients have a mutated Rb1 gene only in the tumor tissue [3]. The growth of Rb begins with a small, semi-transparent lesion in the sensory part of the retina, after which it progressively takes on a whitish coloring, and a dilated afferent and efferent vessel appears. Upon further growth the tumor leaves the retina, and an exophytic or endophytic image of growth may occur. A very rare form of Rb is diffuse growth of Rb [4,5]. Localized intraocular Rb is divided into groups A to E based on the advanced stage of the pathology according to the ICRB (International Classification of Retinoblastoma), which helps determine the probability of preserving the eyeball, as well as of preserving visual functions [2,6], Table 1. Rb seeding constitutes the dispersion of tumor particles into the adjacent compartments, and is the main parameter for determining

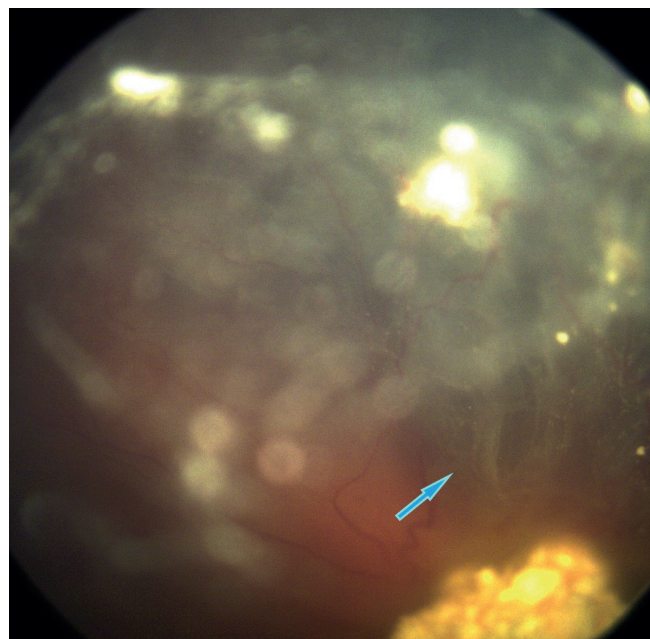
the degree of Rb according to the ICRB (groups C, D and E). Seeding of intraocular Rb may occur into 4 different anatomical localities (Table 2) [7].

In this article we have focused on vitreous seeding. On the basis of morphology, vitreous seeding is divided into 3 groups: dust (Fig. 1), spheres (Fig. 2) and clouds (Fig. 3) [7,8]. These three types differ not only in their morphology, but also in their response to treatment [8]. Vitreous seeding is one of the main limiting factors in the successful "eye-preservation treatment" of retinoblastoma.

## THERAPY FOR VITREOUS SEEDING

### History

Historically the first recorded treatment of Rb was enucleation of the eyeball. This therapy was proposed a life-preserving procedure by James Wardrop in 1809 [9]. Almost one hundred years later this was followed by external radiotherapy, which represented the first possibility of eye-preservation treatment, thanks to Hilgartner's demonstration of the radiosensitivity of Rb in 1903 [10]. However, in addition to ocular complications (cataract, irradiation retinopathy, vitreous hemorrhage, glaucoma), external radiotherapy also increases the later effects of the pathology, which are local effects in connection with orbital growth defect, endocrinopathy, secondary brain tumors, post-radiation sarcomas, and in the case of hereditary retinoblastoma the procedure above all increases the risk of secondary malignancies [9]. In recent decades, conservative therapy of retinoblastoma has experienced rapid development. The introduction of systemic chemotherapy (the currently used protocol of six cycles of VEC – Vincristine, Etoposide, Carboplatin) and focal therapy (cryotherapy, transpupillary thermotherapy and brachytherapy) at the end of the 1990s enabled the progressive abandonment of external radiotherapy. The risks of systemic chemotherapy include the onset of secondary leukemias and myelodysplastic syndrome potentiated by eto-



**Figure 1.** Classification of vitreous seeds: **dust**

**Table 2.** Four distinct anatomic sites of intra-ocular retinoblastoma [7]

1.	tumor dispersion into the vitreous gel following endophytic disruption of ILM and hyaloid at tumor apex
2.	tumor suspension spreading into the retro-hyaloidal space secondary to endophytic disruption of the ILM at tumor base alone, and partial or complete posterior or vitreous detachment
3.	tumor suspension into the subretinal space created by exophytic growth
4.	tumor suspension into the aqueous fluid of the posterior and anterior chambers secondary to disruption of the anterior hyaloid

ILM – internal limiting membrane

**Table 1.** International Classification of Retinoblastoma (ICRB) [6]

Group	Quick reference	Specific features
A	Small tumor	Rb $\leq 3$ mm in size
B	Large tumor Macula Juxtapapillary Subretinal fluid	Rb $> 3$ mm in size or Macular Rb location ( $\leq 3$ mm to foveola) Juxtapapillary Rb location ( $\leq 1.5$ mm to disc) Clear subretinal fluid ( $\leq 3$ mm from margin)
C	Focal seeds	Subretinal seeds $\leq 3$ mm from Rb Vitreous seeds $\leq 3$ mm from Rb Both subretinal and vitreous seeds $\leq 3$ mm from Rb
D	Diffuse seeds	Subretinal seeds $> 3$ mm from Rb Vitreous seeds $> 3$ mm from Rb Both subretinal and vitreous seeds $> 3$ mm from Rb
E	Extensive Rb	Extensive Rb occupying $> 50\%$ of globe or Neovascular glaucoma Opaque media from hemorrhage in anterior chamber, vitreous, or subretinal space Invasion of postlaminar optic nerve, choroid ( $> 2$ mm), sclera, orbit, anterior chamber

*Rb - Retinoblastoma*