

# INTRAOCULAR LYMPHOMA WITH RETROBULBAR INFILTRATION. A CASE REPORT

Jurenová D.<sup>1</sup>, Plesníková P.<sup>1</sup>, Lysková D.<sup>1</sup>, Babál P.<sup>2</sup>, Kobzová D.<sup>2</sup>, Furdová A.<sup>1</sup>

<sup>1</sup>Department of Ophthalmology, Faculty of Medicine, Comenius University and University Hospital Bratislava, Slovakia

<sup>2</sup>Institute of Pathological Anatomy, Faculty of Medicine, Comenius University and University Hospital Bratislava, Slovakia

*The authors of the study declare that no conflict of interest exists in the compilation, theme and subsequent publication of this professional communication, and that it is not supported by any pharmaceutical company.*

Received: 22 December 2020

Accepted: 31 August 2021

Available on-line: 25 November 2021



MUDr. Denisa Jurenová

Ružinovská 6

Nemocnica Ružinov

821 01 Bratislava

E-mail: deniska+ocne@jurenova.sk

## INTRAOCULAR LYMPHOMA WITH RETROBULBAR INFILTRATION. A CASE REPORT

Subjective and objective symptoms following intraocular lymphoma could lead to a misdiagnosing at the beginning of disease what is the cause for delay of an effective treatment. The most common manifestation of lymphoma is an inflammatory disease affecting uvea. A multidisciplinary approach to the diagnosis is required. Suspicion based on the ophthalmologic examinations has to be verified by histology. We present a case report of a 78-year-old patient examined at our clinic with progressive loss of vision on the left eye in 6 months, suspected of retinal detachment. Objectively the visual acuity was counting fingers in front of the left eye. Intraocular pressure changed from normotensive into hypertensive values during regular examinations. We realised imaging exams, ultrasonography and magnetic resonance, which proved intraocular tumour with retrobulbar infiltration and retinal detachment. The patient was indicated for enucleation which enabled assignment of a histologic type of intraocular lymphoma B-Non-Hodgkin lymphoma from marginal zone B-cells. We sent the patient to a haematologist-oncologist for managing of the following treatment and we prescribed individual prosthesis to the patient after the enucleation. The patient remains in observation, no surgical treatment, chemotherapy or radiotherapy have been used for 23 months after the enucleation. The enucleation was both a diagnostic and treatment modality.

**Key words:** intraocular lymphoma, B-Non-Hodgkin lymphoma, enucleation, intraocular tumours

Čes. a slov. Oftal., 77, 2021, No. 6, p. 306–312

## INTRODUCTION

Intraocular lymphoma is a relatively rare group of malignancies that can be divided into primary and secondary intraocular lymphomas. Primary intraocular lymphoma affecting the vitreoretinal interface is a subset of primary lymphomas of the central nervous system (CNS), with malignant cells occurring only intraocularly without their entrapment in the CNS, but in the later stages, concomitant CNS involvement is often present. Vitreoretinal lymphomas are predominantly aggressive. Primary uveal lymphoma is more often indolent, morphologically, immunophenotypically and genotypically similar to extranodal lymphomas from marginal zone B-cells. Secondary intraocular lymphoma occurs as a secondary ocular metastasis in patients with systemic leukemic or lymphoma disease [1]. Most intraocular lymphomas are non-Hodgkin's lymphomas from B-lymphocytes, but T-cell lymphomas also rarely occur. Diag-

nosis is a demanding process, because lymphomas can present with masking symptoms which, in the case of a differential diagnosis, can lead to the establishment of an incorrect diagnosis and delay in the introduction of effective treatment [2].

## EPIDEMIOLOGY

Primary intraocular lymphoma is a rare disease whose epidemiology is not exactly known, as most of the available records are related to primary CNS lymphoma. The incidence of intraocular lymphomas has been increasing in recent years. It was initially associated with an increase in the number of immunocompromised and immunodeficient patients, but the increase in cases also occurs in immunocompetent patients, which may be related to extended life expectancy and better diagnosis of the disease [2,3]. Intraocular lymphomas represent 1.86 % of ocular malignancies [2,4]. The average age for

diagnosis of the disease is the 5th and 6th decade [5], although very rare cases in children and adolescents have been reported [6,7,8]. Some studies report that women are affected more often than men, in a 2:1 ratio, without racial preference [9,10,11,12].

## CLINICAL MANIFESTATION

Subjective symptoms of patients with intraocular lymphoma include eye pain, red eye, eyelid oedema, blurry vision, floaters, foreign body sensation, photophobia. Some patients may be asymptomatic, and the tumour is detected during random examination [12,13,14]. Objectively we can find infection of the bulbus, cells and precipitates in the anterior chamber, hyphema, hypopyon, iris neovascularisation, vitreous inflammation, vitreous haemorrhage, retinal haemorrhage or exudate, retinitis, oedema of the optic nerve disc, vasculitis, secondary glaucoma. A pathognomonic symptom for intraocular lymphoma is the finding of orange-yellow cream subretinal infiltrations, which may be isolated or multiple. Infiltrates under the retinal pigment epithelium have the typical appearance of "leopard skin". After regression of chorioretinal infiltrates, scarring and atrophy of the retinal pigment epithelium occurs. Patients with presentation of inflammatory disease used to be initially treated with corticosteroids. In the beginning, the treatment appears to be successful; the objective finding improves, which is explained by the suppression of reactive lymphocytes, but the effect is only intermittent, and the inflammatory disease subsequently becomes resistant to corticosteroid treatment. In some patients, treatment with systemic immunomodulators such as methotrexate, azathioprine, cyclosporine, cyclophosphamide is carried out, with similar effects as in corticosteroids [13,15].

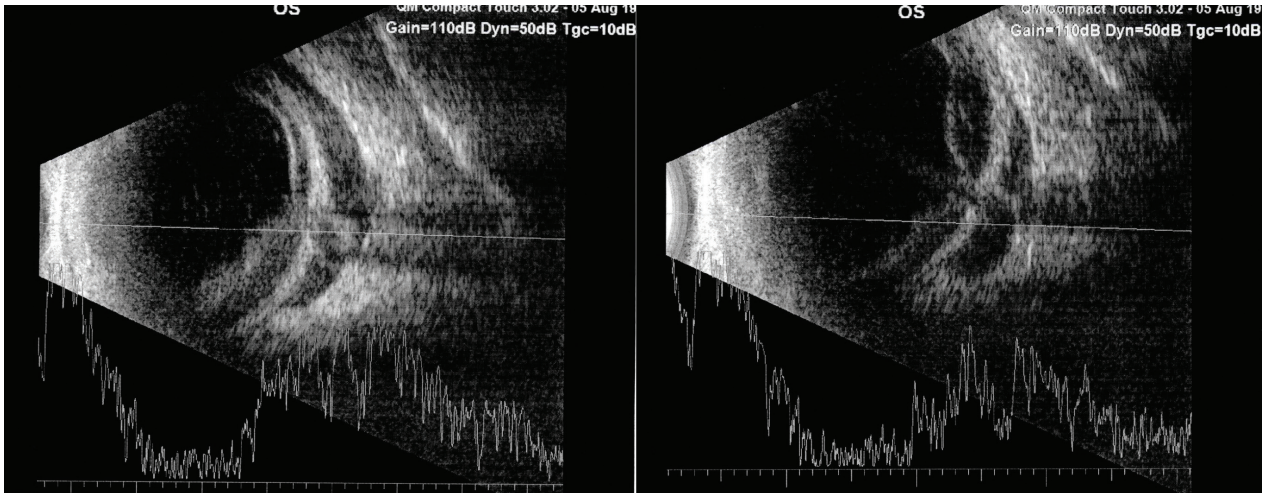
Primary vitreoretinal lymphoma tends to manifest as vitreous inflammatory retinal changes, including changes in the pigment epithelium without anterior segment involvement, although anterior ventricular precipitates and uveitis may rarely occur. Other rare manifestations of vitreoretinal lymphoma, such as vasculitis, hyphema, hypopyon, secondary glaucoma, optic nerve disc oedema, are mentioned above [1,13]. Primary vitreoretinal lymphoma is usually bilateral in 64–83% of cases, although in the beginning the finding is mostly unilateral. Primary vitreoretinal lymphoma has a faster progression of the finding; 42–92% of cases develop lymphoma of the central nervous system in the period of 8–29 months [3]. Concomitant CNS infiltration forms neurological symptoms, such as behavioural and cognitive function changes, seizures, hemiparesis, aphasia, and cephalgia, with nausea in intracranial hypertension [3,16].

Primary uveal lymphoma is most often presented by a decrease in central visual acuity or increased intraocular pressure. Uveal lymphoma is predominantly a unilateral uveal disease, mainly in the form of yellow choroidal infiltrates, diffuse thickening of the uveal tract and often with the finding of secondary retinal detachment.

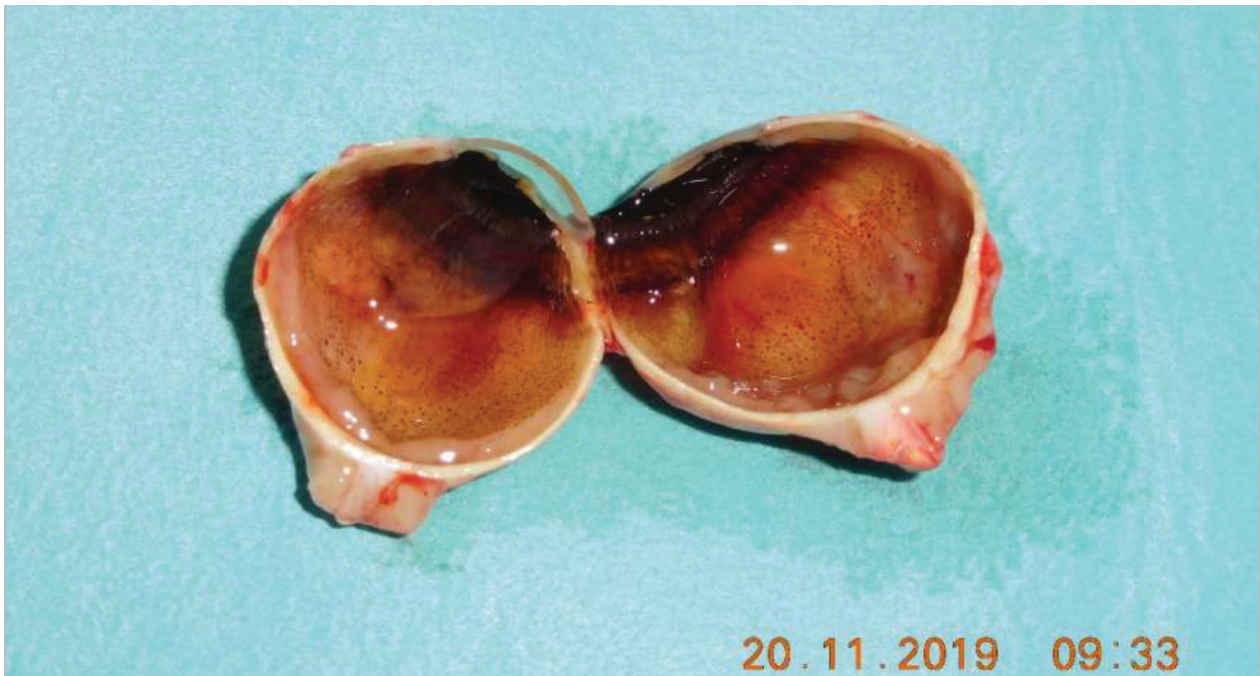Inflammatory involvement of the anterior segment is common in lymphoma of the iris and ciliary body, along with high intraocular pressure or iris rubeosis [1]. Uveal lymphoma usually remains stable without significant progression on the fundus. Primary uveal lymphoma is more often accompanied by extrabulbar infiltration, when protrusion or diplopia may present; subconjunctival and episcleral overgrowth is manifested by pink salmon patches [3].

## CASE REPORT

A 78-year-old female patient was referred to our clinic, with progressive loss of vision over 6 months, with suspected retinal detachment in the left eye. Monoclonal IgG gammopathy and adenocarcinoma, for which hysterectomy with radiotherapy were performed, are significant in the past medical history. Oncological disease occurred in the family. The patient's father had lung cancer and her mother had leukaemia. Objectively, the central visual acuity was at the level of counting fingers in front of the left eye. Intraocular pressure changed from normotonic to hypertonic values during follow-up, and normalisation did not occur, despite the use of antiglaucomatic therapy. Imaging examinations of the patient were performed, which showed an intraocular tumour with suspected extraocular spread. On ultrasound examination of the left eye (Figure 1), the retinal detachment was visible in all quadrants, choroid detachment, optic nerve disc overlapped by tumour, optic nerve dilatation, and negative echo at a thickness of 5 mm. Magnetic resonance imaging showed irregular thickening of the left bulbus wall, a thickened choroid to a thickness of 2.8 mm, the presence of retrobulbar infiltration around the optic nerve disc and the initial part of the optic nerve measuring 14x5.5 mm, and the image of retinal detachment. The brain parenchyma was intact on magnetic resonance imaging. Examination by optical coherence tomography could not be performed; the patient did not fix with the left eye. Fluorescein angiography was not performed for the distinct finding of a tumorous intraocular lesion with involvement of the initial section of the optic nerve on ultrasonography and magnetic resonance imaging. Computed tomography of the chest and ultrasonography of the abdomen did not show the spread of the disease. In the patient diagnosed with malignant choroid tumour, we also considered the development of secondary metastasis, in addition to lymphoma, as the patient was treated for adenocarcinoma in the past. Because of the intraocular finding of the tumour with involvement of the initial part of the optic nerve, we proceeded to enucleation of the left bulbus with histologisation. Macroscopically on the enucleated bulbus (Figure 2), a grey-beige, relatively solid mass in the range of 2x1 cm with a circular overgrowth around the optic nerve up to a distance of 0.5 cm behind the bulbus was visible intraocularly. Histologically (Figure 3) the finding on the posterior



**Figure 1.** Ultrasonographic examination of the left eye: retinal and choroidal detachment, optic nerve disc overlapped by the tumour, negative echo at 5mm depth



**Figure 2.** Bulbus after the enucleation: intrabulbar mass 2x1cm with circular overgrowing around the optic nerve

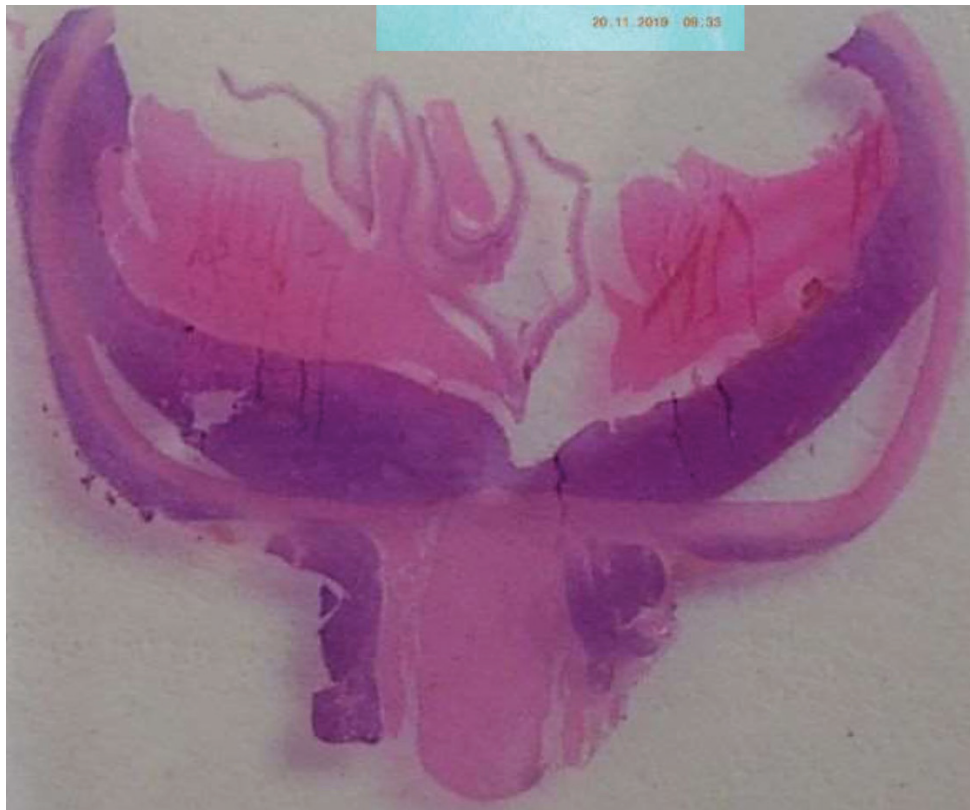wall of the bulbus under the choroid was described as a solid infiltration of small lymphocytes, with a round or slightly folded nuclear membrane, lumpy chromatin, central nucleus, small amount of cytoplasm, with formation of germ / proliferative centres; mitotic activity was low. The same infiltration was in the retrobulbar tissue around the optic nerve.

Immunophenotype: CD3+ small lymphocytes (equally CD5+ and CD43+), CD10+ only germ / proliferative centres, CD20+, CD21+ only in germ centres, CD23+ predominantly in germ centres, present IgM membrane+, cyclinD1-, Ki67+, MUM1+.

Morphologically and phenotypically with evidence of clonal restriction, the outcome is the infiltration of CD20 + small cell B-Non-Hodgkin's lymphoma from the spec-

trum of marginal zone B-cell lymphomas as a secondary malignancy in the patient with previously verified adenocarcinoma.

The patient was free of complications after enucleation, healing per primam, prescribed an individual prosthesis. The patient was sent to a haematologist-oncologist for further consideration. No additional surgical treatment, chemotherapy or radiotherapy was required. 15 months after enucleation, the patient remains in the dispensarisation of the ophthalmologist and haematologist-oncologist. The haematologist-oncologist indicates, apart from control laboratory parameters, regular ultrasonography of the abdomen and an X-ray of the chest, which have not shown the presence of dissemination of the disease. 10 months after



**Figure 3.** Histological finding: the tumour on the posterior wall of the bulbus under the choroidea and a retrobulbar infiltration around the optic nerve

enucleation, the haematologist-oncologist indicated a positron emission tomography examination with computed tomography, which was negative for lymphoma disease. Ophthalmological examinations are performed at half-yearly intervals, with simultaneous monitoring of the right eye for possible development of bilateral lymphoma. The right eye remains without signs of lymphoma. Intraocular localisation of lymphoma with retrobulbar infiltration around the optic nerve remains the only detected localisation of primary intraocular lymphoma. Enucleation was used as a diagnostic as well as a treatment modality.

## DISCUSSION

Intraocular lymphoma is a rare disease, and therefore its diagnosis from the development of the initial symptoms can take months [17,18,19]. The most common disease that may initially mask intraocular lymphoma and delay diagnosis is posterior uveitis of unknown aetiology. Uveitis is a relatively common condition, and the atypical course of uveitis is more common than lymphoma [20]. Differential diagnosis should differentiate between chronic uveitis unresponsive to steroid therapy, endophthalmitis, herpetic and cytomegalovirus chorioretinitis, chorioretinitis in toxoplasmosis, tuberculosis and syphilis, non-infectious uveitis in sarcoidosis, acute retinal necrosis, arterial and venous retinal occlusion, vasculitis, optic neuritis, white dot syndrome,

systemic Hodgkin's or Non-Hodgkin's lymphoma, reactive lymphoid hyperplasia [21,22,23]. The rare finding of a solitary intraocular mass should be differentiated from amelanotic melanoma and secondary metastasis [24]. Detailed ophthalmological examinations have a positive prediction of 88.9% and a negative predictive value of 85% [25]. Diagnosis of intraocular lymphoma requires a multidisciplinary approach. An ophthalmologist suspects intraocular lymphoma, based on ophthalmological examinations, such as central visual acuity, intraocular pressure, slit lamp examination using a Hruby or Volk lens, fundus photography, ultrasonography, optical coherence tomography (OCT), fluorescein angiography. Hyperreflective infiltrates at the level of retinal pigment epithelium may be present on OCT, although lymphoma may affect all layers of the retina. Fluorescein angiography detects the finding of hyperfluorescence or hypofluorescence. Active subretinal infiltrates are detected as hyperfluorescent lesions; hypofluorescent parts are usually sections in which malignant cells are no longer present [26]. Fluorescein angiography highlights the spotted sign of leopard skin [2]. Imaging examination, magnetic resonance, computed tomography or positron emission tomography are performed for tumour visualisation and possible CNS involvement. If malignant lymphoma cells are detected in cerebrospinal fluid collected by lumbar puncture, no further diagnostic procedures are required [27]. The suspicion of intraocular lymphoma is verified by cyto-

logical or histological examination with immunohistochemical analysis. Samples can be taken by thin-needle aspiration biopsy of the vitreous cavity or by pars plana vitrectomy, although the result is often false-negative due to insufficient capture of malignant cells [2]. The vitreous cavity contains reactive T-lymphocytes, necrotic cells, debris, fibrin, which impedes the identification of malignant cells [28]. Pars plana vitrectomy usually improves visual acuity, after removal of the content of the vitreous cavity, but at the same time there may be an iatrogenic spread of malignant lymphoma cells into the epibulbar space [29]. Retinal and subretinal infiltrates require sampling by retinotomy via an intraocular or transscleral approach [22]. In cases where the affected eye does not fulfil its function, or where it is not possible to choose conservative treatment, enucleation of the bulbus is performed [30]. Immunohistochemical examination, flow cytometry and molecular analysis detect the type of intraocular lymphoma, which determines the subsequent treatment [27]. Standard treatment guidelines for primary intraocular lymphoma are not exactly defined due to the rarity of the disease. Management depends on the stage of the disease, the presence of CNS involvement and the general condition of the patient, on the basis of which is elected between intravitreal chemotherapy, systemic chemotherapy, radiotherapy, surgery and their combinations, in collaboration with a haematologist-oncologist [2,3,12]. External radiotherapy with application of 30–45 Gy to the tumour lesion is one of the treatment modalities. The disadvantage is that radiotherapy cannot be repeatedly applied in the case of relapse. Ophthalmological side-effects of radiotherapy include radiation retinopathy, optic neuropathy, cataract, dry eye syndrome, corneal epithelial defects [23]. Isolated radiotherapy is no longer considered a standard treatment for primary intraocular lymphoma [31], but has its place in combination with systemic chemotherapy [27]. In systemic chemotherapy, the haematologist-oncologist chooses between methotrexate, vincristine, rituxan, thiotepa, procarbazine, dexamethasone and carboplatin, ara-C for intravenous administration [9]. Methotrexate, optionally in combination with ara-C, may be administered intrathecally in primary intraocular lymphoma of the

central nervous system [32]. Alternatively, a combination of intrathecal administration with intravenous chemotherapy is possible [33]. Chemotherapeutics can be applied locally intravitreally. Following intravitreal administration, the cytotoxic level of methotrexate remains intraocularly for 5 days [34], therefore methotrexate is administered 1–2 times per week [35]. Adverse effects of intravitreal methotrexate administration include cataract progression, optic neuropathy, corneal epitheliopathy [21], vitreous haemorrhage, maculopathy, endophthalmitis [31]. Intravitreal administration of rituximab, a monoclonal antibody against CD20, has been used effectively, in combination with other treatment modalities in smaller studies [36,37,38]. Intensive chemotherapy followed by autologous stem cell transplantation appear to be useful in patients with refractory and recurrent primary intraocular lymphoma [39,40]. Surgical treatment, enucleation of the bulbus, is used if visual functions are no longer preserved, in a painful eye, in conditions without previous therapeutic effect, or if it was not possible to establish an accurate diagnosis by previous samples [41,42,43,44]. Primary vitreoretinal lymphomas tend to be radiosensitive; intravitreal administration of methotrexate and rituximab, systemic chemotherapy, or intrathecal administration of chemotherapeutics is used. Early initiation of treatment is crucial for high aggressivity of vitreoretinal lymphomas [27]. The prognosis of primary uveal lymphomas is positive; systemic dissemination of uveal lymphoma is rare. Radiotherapy, chemotherapy, rituximab immunotherapy, as well as surgical treatment are effective for uveal lymphoma [45].

## CONCLUSION

The indication for isolated surgical treatment, enucleation, is a rare treatment option for lymphoma disease, as lymphoma rarely occurs as primary intraocular lymphoma. Proper evaluation of the symptoms and the results of the examinations are crucial in the context of the relatively extensive differential diagnosis of intraocular lymphoma. To obtain an accurate histological diagnosis and subsequent adequate therapy, it is necessary to choose a multidisciplinary approach.

## LITERATURE

- Coupland SE, Damato B. Understanding intraocular lymphomas. *Clin Exp Ophthalmol*. 2008 Aug;36(6):564-578. doi: 10.1111/j.1442-9071.2008.01843.x
- Tang L-J, Gu C-L, Zhang P. Intraocular lymphoma. *Int J Ophthalmol*. 2017;10(8):1301-1307. doi: 10.18240/ijo.2017.08.19
- Sagoo MS, Mehta H, Swampillai AJ, et al. Primary intraocular lymphoma. *Surv Ophthalmol*. 2014 Sep-Oct;59(5):503-516. doi: 10.1016/j.survophthal.2013.12.001
- Reddy EK, Bhatia P, Evans RG. Primary orbital lymphomas. *Int J Radiat Oncol Biol Phys*. 1988 Nov;15(5):1239-1241. doi: 10.1016/0360-3016(88)90210-6
- Cho B-J, Yu HG. Risk factors for intraocular involvement in patients with primary central nervous system lymphoma. *J Neurooncol*. 2014 Dec;120(3):523-529. doi: 10.1007/s11060-014-1581-4
- Sobrin L, Dubovy SR, Davis JL, Murray TG. Isolated, bilateral intraocular lymphoma in a 15-year-old girl. *Retina*. 2005 Apr-May;25(3):370-373. doi: 10.1097/00006982-200504000-00021
- Wender A. Primary B-Cell Lymphoma of the Eyes and Brain in a 3-Year-Old Boy. *Arch Ophthalmol*. 1994 Apr;112(4):450-451. doi: 10.1001/archophth.1994.01090160024009
- Chan S. Iris lymphoma in a pediatric cardiac transplant recipient. *Clinicopathologic findings*. *Ophthalmology*. 2000 Aug;107(8):1479-1482. doi: 10.1016/s0161-6420(00)00172-x
- Berenbom A, Davila RM, Lin H-S, Harbour JW. Treatment outcomes for primary intraocular lymphoma: implications for external

- beam radiotherapy. *Eye*. 2007 Sep;21(9):1198-1201. doi: 10.1038/sj.eye.6702437
10. Buettner H, Bolling JP. Intravitreal Large-Cell Lymphoma. *Mayo Clin Proc*. 1993 Oct;68(10):1011-1015. doi: 10.1016/s0025-6196(12)62276-9
  11. Peterson K, Gordon KB, Heinemann MH, DeAngelis LM. The clinical spectrum of ocular lymphoma. *Cancer*. 1993 Aug;72(3):843-849. doi: 10.1002/1097-0142(19930801)72:3<843: aid-cncr2820720333>3.0.co;2-#
  12. Furdová A, Marková A, Kapitanová K, Zahorjanová P. Treatment results in patients with lymphoma disease in the orbital region. *Cesk Slov Oftalmol*. 2017;73(5-6):211-217. Available from: <http://www.cs-ophthalmology.cz/en/journal/articles/32>
  13. Melson MR, Mukai S. Intraocular Lymphoma. *Int Ophthalmol Clin*. 2006;46(2):69-77. doi: 10.1097/00004397-200604620-00008
  14. Whitcup SM, de Smet MD, Rubin BI, et al. Intraocular lymphoma. Clinical and histopathologic diagnosis. *Ophthalmology*. 1993 Sep;100(9):1399-1406. doi: 10.1016/s0161-6420(93)31469-7
  15. Chan C-C, Buggage RR, Nussenblatt RB. Intraocular lymphoma. *Curr Opin Ophthalmol*. 2002 Dec;13(6):411-418. doi: 10.1097/00055735-200212000-00012
  16. Coupland SE, Heimann H, Bechrakis NE. Primary intraocular lymphoma: a review of the clinical, histopathological and molecular biological features. *Graefes Arch Clin Exp Ophthalmol*. 2004 Nov;42(11):901-913. doi: 10.1007/s00417-004-0973-0
  17. Cassoux N, Merle-Beral H, Leblond V, et al. Ocular and central nervous system lymphoma: clinical features and diagnosis. *Ocul Immunol Inflamm*. 2000 Dec;8(4):243-250. doi: 10.1076/ocii.8.4.243.6463
  18. Grimm SA, Pulido JS, Jahnke K, et al. Primary intraocular lymphoma: an International Primary Central Nervous System Lymphoma Collaborative Group Report. *Ann Oncol*. 2007 Nov;18(11):1851-1855. doi: 10.1093/annonc/mdm340
  19. Hoffman PM, McKelvie P, Hall AJ, Stawell RJ, Santamaria JD. Intraocular lymphoma: a series of 14 patients with clinicopathological features and treatment outcomes. *Eye*. 2003 May;17(4):513-521. doi: 10.1038/sj.eye.6700378
  20. Batis V, Shuttleworth J, Shuttleworth G, Williams GS. Diagnostic dilemma of ocular lymphoma. *BMJ Case Rep*. 2019 Jun;12(6):e229513. doi: 10.1136/bcr-2019-229513
  21. Vosganian GS, Boisot S, Hartmann KI, et al. Primary intraocular lymphoma: a review. *J Neurooncol*. 2011 Nov;105(2):127-134. doi: 10.1007/s11060-011-0618-1
  22. Bardenstein DS. Intraocular Lymphoma: Intraocular lymphoma is the most elusive intraocular tumor to diagnose. *Cancer Control*. 1998;5(4):317-325. doi: 10.1177/107327489800500403
  23. Choi JY, Kafkala C, Foster CS. Primary Intraocular Lymphoma: A Review. *Semin Ophthalmol*. 2006;21(3):125-133. doi: 10.1080/08820530500350498
  24. Dean JM, Novak MA, Chan CC, Green WR. Tumor detachments of the retinal pigment epithelium in ocular/ central nervous system lymphoma. *Retina*. 1996;16(1):47-56. doi: 10.1097/00006982-199616010-00009
  25. Fardeau C, Lee CPL, Merle-Béral H, et al. Retinal Fluorescein, Indocyanine Green Angiography, and Optic Coherence Tomography in Non-Hodgkin Primary Intraocular Lymphoma. *Am J Ophthalmol*. 2009;147(5):886-894.e1. doi: 10.1016/j.ajo.2008.12.025
  26. Garweg JG, Wanner D, Sarra G-M, et al. The diagnostic yield of vitrectomy specimen analysis in chronic idiopathic endogenous uveitis. *Eur J Ophthalmol*. 2006;16(4):588-594. doi: 10.1177/112067210601600414
  27. Chan C-C, Wallace DJ. Intraocular lymphoma: update on diagnosis and management. *Cancer Control*. 2004;11(5):285-295. doi: 10.1177/107327480401100502
  28. Coupland SE, Bechrakis NE, Anastassiou G, et al. Evaluation of vitrectomy specimens and chorioretinal biopsies in the diagnosis of primary intraocular lymphoma in patients with Masquerade syndrome. *Graefes Arch Clin Exp Ophthalmol*. 2003 Oct;241(10):860-870. doi: 10.1007/s00417-003-0749-y
  29. Cursiefen C, Holbach LM, Lafaut B, Heimann K, Kirchner T, Naumann GO. Oculocerebral Non-Hodgkin's Lymphoma With Uveal Involvement Development of an Epibulbar Tumor After Vitrectomy. *Arch Ophthalmol*. 2000;118(10):1437-1440. doi:10.1001/archophth.118.10.1437
  30. Trudeau M, Shepherd FA, Blackstein ME, Gospodarowicz M, Fitzpatrick P, Moffatt KP. Intraocular lymphoma: report of three cases and review of the literature. *Am J Clin Oncol*. 1988;11(2):126-130.
  31. Faia LJ, Chan C-C. Primary intraocular lymphoma. *Arch Pathol Lab Med*. 2009;133(8):1228-1232. doi: 10.1043/1543-2165-133.8.1228
  32. Mason JO, Fischer DH. Intrathecal chemotherapy for recurrent central nervous system intraocular lymphoma. *Ophthalmology*. 2003;110(6):1241-1244. doi: 10.1016/S0161-6420(03)00268-9
  33. Sandor V, Stark-Vancs V, Pearson D, et al. Phase II trial of chemotherapy alone for primary CNS and intraocular lymphoma. *J Clin Oncol*. 1998 Sep;16(9):3000-3006. doi: 10.1200/JCO.1998.16.9.3000
  34. de Smet MD, Vancs VS, Kohler D, Solomon D, Chan CC. Intravitreal chemotherapy for the treatment of recurrent intraocular lymphoma. *Br J Ophthalmol*. 1999 Apr;83(4):448-451. doi: 10.1136/bjo.83.4.448
  35. Sou R, Ohguro N, Maeda T, Saishin Y, Tano Y. Treatment of primary intraocular lymphoma with intravitreal methotrexate. *Jpn J Ophthalmol*. 2008;52(3):167-174. doi: 10.1007/s10384-008-0519-9
  36. Itty S, Pulido JS. Rituximab for Intraocular Lymphoma: Retina. 2009 Feb;29(2):129-132. doi: 10.1097/IAE.0b013e318192f574
  37. Kitzmann AS, Pulido JS, Mohney BG, et al. Intraocular use of rituximab. *Eye*. 2007 Dec;21(12):1524-1527. doi: 10.1038/sj.eye.6702804
  38. Ohguro N, Hashida N, Tano Y. Effect of Intravitreal Rituximab Injections in Patients With Recurrent Ocular Lesions Associated With Central Nervous System Lymphoma. *Arch Ophthalmol*. 2008;126(7):1002-1003. doi: 10.1001/archophth.126.7.1002
  39. Soussain C, Hoang-Xuan K, Levy V. Chimiothérapie intensive avec support hématopoïétique chez 22 patients ayant un lymphome primitif du système nerveux central ou un lymphome intraoculaire réfractaire ou en rechute : mise à jour des résultats [Results of intensive chemotherapy followed by hematopoietic stem-cell rescue in 22 patients with refractory or recurrent primary CNS lymphoma or intraocular lymphoma]. *Bull Cancer*. 2004 Feb;91(2):189-192. French.
  40. Abrey LE, Moskowicz CH, Mason WP, et al. Intensive Methotrexate and Cytarabine Followed by High-Dose Chemotherapy With Autologous Stem-Cell Rescue in Patients With Newly Diagnosed Primary CNS Lymphoma: An Intent-to-Treat Analysis. *J Clin Oncol*. 2003 Nov;21(22):4151-4156. doi: 10.1200/JCO.2003.05.024
  41. Chow PP-C, Ho SL, Lai WW, Au WY. Enucleation of painful blind eye for refractory intraocular lymphoma after dose-limiting chemotherapy and radiotherapy. *Ann Hematol*. 2012;91(10):1657-1658. doi: <https://doi.org/10.1007/s00277-012-1452-z>
  42. Albadri ST, Pulido JS, Macon WR, Garcia JJ, Salomao DR. Histologic findings in vitreoretinal lymphoma: learning from enucleation specimens. *Retina*. 2020 Feb;40(2):391-398. doi: 10.1097/IAE.0000000000002676
  43. Burnier SV, Burnier MN. Linfoma sistêmico de células B com manifestação ocular e extensão extraocular [Systemic B-cell lymphoma with ocular manifestation and extraocular extension]. *Arq Bras Oftalmol*. 1997;60(6). doi: 10.5935/0004-2749.19970015
  44. Sood AB, Yeh S, Mendoza P, Grossniklaus HE. Histopathologic Diagnosis of Atypical Primary Vitreoretinal Lymphoma following Enucleation. *Ocul Oncol Pathol*. 2016;2(4):242-245. doi: 10.1159/000446605
  45. Aronow ME, Portell CA, Sweetenham JW, Singh AD. Uveal Lymphoma: Clinical Features, Diagnostic Studies, Treatment Selection, and Outcomes. *Ophthalmology*. 2014;121(1):334-41. doi: <https://doi.org/10.1016/j.ophtha.2013.09.004>