

# PARANEOPLASTIC OPTIC NEUROPATHY AS AN INITIAL CLINICAL MANIFESTATION OF SMALL CELL LUNG CANCER. A CASE REPORT

Akbulut E., Bayraktar H., Tugcu B.

Department of Ophthalmology, Faculty of Medicine, Bezmialem Vakif University, Istanbul, Turkey

**Declarations:**

*There was no funding for this study. The authors declare that they have no conflict of interest.*

Received: 1 February 2021

Accepted: 26 July 2021



First author: Ersin Akbulut, MD.

Corresponding Author:

Betül Tugcu MD., Prof.

Department of Ophthalmology,  
Faculty of Medicine, Bezmialem  
Vakif University

Adnan Menderes (Vatan) Avenue,  
Fatih

34093 Istanbul

E-mail: betultugcu@gmail.com

## SUMMARY

Paraneoplastic optic neuropathy (PON) is a very rare condition. In this study, a case of PON is presented, with the first complaint by the patient being painless vision loss in one eye. In the follow-up of our case, optic neuropathy developed in the fellow eye. Electromyography examination performed due to diffuse body pain and motor loss in the left extremity was compatible with peripheral sensorimotor polyneuropathy. Lung biopsy was planned due to the EMG result and lymphadenopathy detection in thorax computed tomography (CT). The biopsy result of the patient was reported as nonspecific hyperplasia. As the patient's complaints increased, a paraneoplastic antibody panel was requested and CV2 / CRMP5 antibody was found to be positive. Thereupon, as a result of the repeated biopsy, our patient was diagnosed with small cell lung cancer. We think that paraneoplastic optic neuropathy should be considered in the differential diagnosis in patients of advanced age, smokers, painless subacute vision loss, optic disc swelling, and research in this direction should be insisted on, as in our case.

**Keywords:** paraneoplastic optic neuropathy, small cell lung cancer, CV2/CRMP5 antibodies

*Čes. a slov. Oftal., 77, 2021, No. 6, p. 302–305*

## INTRODUCTION

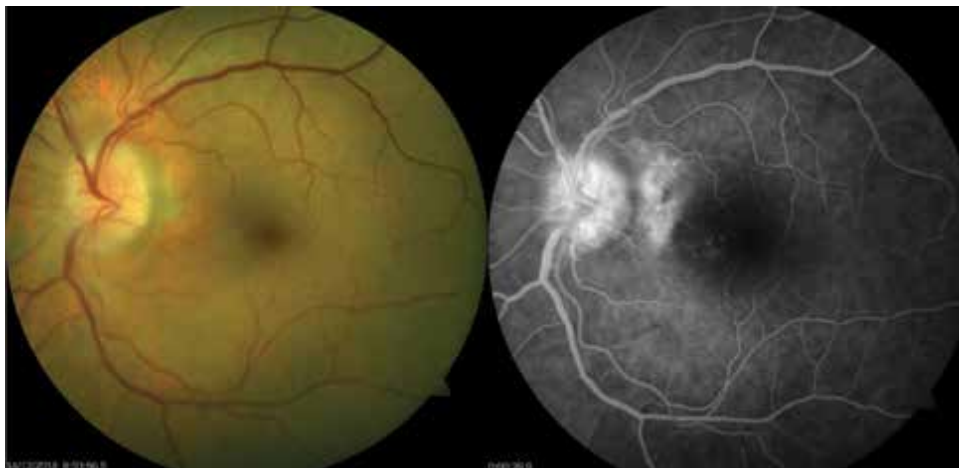Paraneoplastic syndrome is a set of symptoms and signs observed due to tissue damage caused by a tumour in a location other than its primary location or metastasis [1]. Although its exact prevalence is unknown, it is accepted that paraneoplastic findings accompany 10% of cancer patients [2]. Paraneoplastic ocular involvement is a rare entity that should be kept in mind in unexplained clinical situations, as these findings are often considered as a precursor to malignancy and can be a guide for early diagnosis [1,3].

Paraneoplastic optic neuropathy is one of the rarest forms among paraneoplastic syndromes [4]. In this article, we discuss our patient with small cell lung cancer (SCLC) associated with CV2/CRMP5 antibody positive

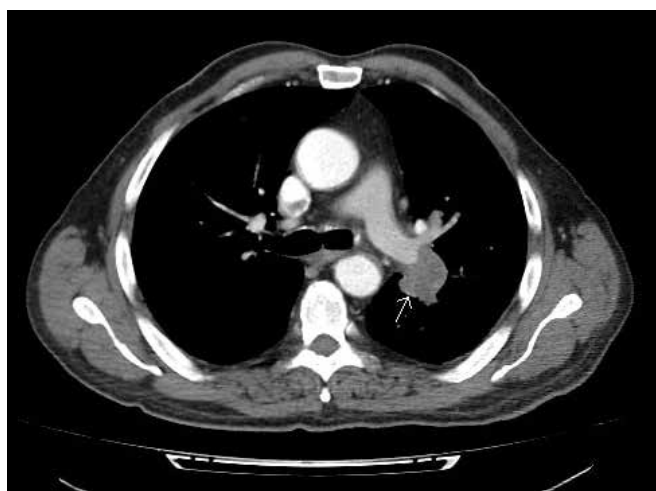paraneoplastic optic neuropathy. In the literature, optic neuropathy was observed as low as 7% in CV2/CRMP5 antibody-positive associated paraneoplastic syndrome [5]. Rarely, optic neuropathy may be the first sign of malignancy, as in our case. In addition, our case was complicated by insufficient biopsy and imaging reports and emphasises the fact that paraneoplastic syndrome should be considered in unexplained symptoms.

## CASE REPORT

Our case, a 65-year-old male, was admitted to our clinic with a complaint of blurred vision in the right eye for 1 week. The patient had no known history of



**Figure 1.** Swelling in the left optic disc in the fundus photo (left image). Hyperfluorescence appearance at the head of the optic disc in the left eye in fundus fluorescein angiography (right image)



**Figure 2.** Lymph node in the hilar area 30\*24mm (marked with a white arrow)

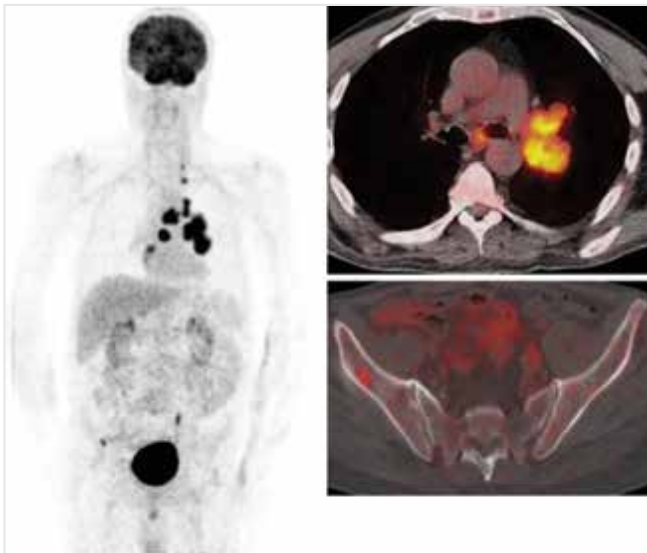
chronic disease, other than hypertension, and he was a smoker.

In the examination of the patient, who had painless visual loss in one eye, his visual acuity was 0.05 in the right and 1.0 in the left eye. A relative afferent pupillary defect was observed on the right side. Colour perception was normal. While anterior segment examination was bilaterally normal, funduscopy revealed optic disc swelling and oedema in the right eye. The visual field test could not be evaluated, due to low reliability caused by a lack of cooperation by the patient incompatibility. Routine examinations and imaging were ordered after 100 mg acetylsalicylic acid 1x1, methylprednisolone-16mg 1x5, topical coenzyme-Q10 2x1 were started as treatment. Serology was normal, orbital MRI showed contrast enhancement in the right optic nerve. Although there was no visual improvement while under treatment, oedema and swelling in the right optic disc were decreased. In addition, atrophy in the tem-

poral part of the optic nerve in the right eye started at 2 months. Complaints of widespread body pain and imbalance started in the 2nd month in the follow-up, and optic disc swelling was found in the left eye. Visual acuity was 0.05 in the right eye and 1.0 in the left eye. In fundus fluorescein angiography, there was leakage that started in the early phase at the head of the optic disc in the left eye, and permanent hyperfluorescence staining on the retinal artery and vein walls originating from the disc head (Figure 1). Because the patient did not respond to steroid treatment, and optic neuropathy developed in the fellow eye within 2 months, he was hospitalised in the Ophthalmology ward for further examination.

The patient was examined neurologically due to diffuse body pain and motor loss in the left lower extremity. The electromyography examination was compatible with peripheral sensorimotor polyneuropathy. Thorax-computed tomography (CT) was ordered for the patient, because peripheral sensory polyneuropathy could be a paraneoplastic finding. Lymphadenopathy (LAP) was determined as a result (Figure 2). The patient was examined by a pulmonologist in terms of malignancy. A biopsy was taken by a thoracic surgeon with mediastinoscopy. The biopsy result was reported as nonspecific hyperplasia. The patient was discharged after the biopsy result.

In the follow-up of the patient ++ anterior chamber cell and vitritis were observed. In addition, the patient's widespread muscle pain increased, and foot drop developed on the left side. A paraneoplastic autoantibody panel was requested for the patient, with a suspicion of paraneoplastic syndrome. As a result, CV2/CRMP5 antibody was found to be positive. Thereupon, fluorodeoxyglucose-positron emission tomography (PET-CT) was requested for the patient. As a result, increased FDG uptake was observed in the hilar region (Figure 3). The patient was examined again by the pulmonologist, and a biopsy was

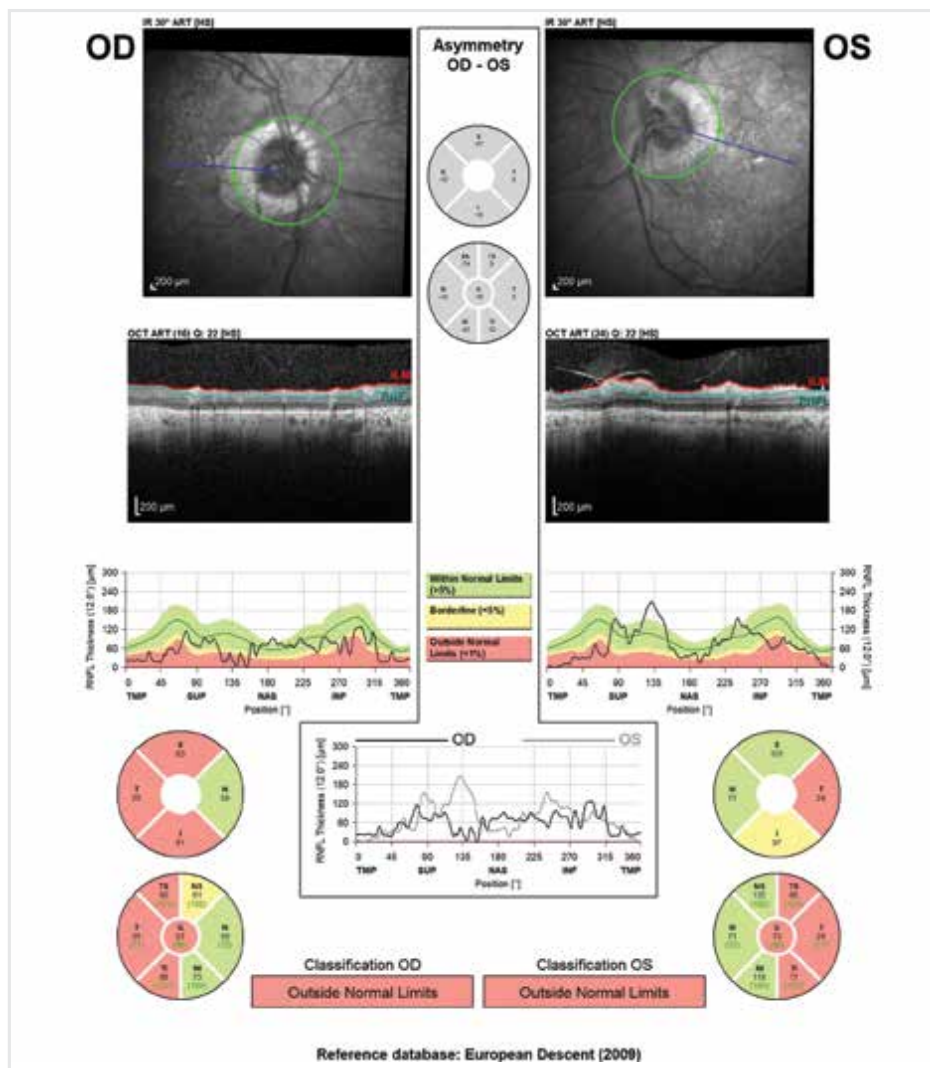


**Figure 3.** Mass lesion, 38\*27mm in size, showing left lung on fluorodeoxyglucose (FDG)-positron emission tomography (PET) imaging (SUVmax: 10)

planned with VATS (video-assisted thoracoscopic surgery). As a result of the biopsy, the patient was diagnosed with small cell lung cancer. Chemotherapy treatment was started. In this process, the progression to optic atrophy started 4 months after the first oedema was detected in the right optic nerve. In the OCT-RNFL follow-up of the left eye, exactly the same process was observed in the right eye. That is, temporal thinning occurred in the RNFL at 2 months and progression to optic atrophy at 4 months. After 6 months of chemotherapy treatment, the patient died. Visual acuity was 0.05 in the right and 0.7 in the left eye, and bilateral optic atrophy was observed in the last examination (Figure 4).

## DISCUSSION

Paraneoplastic optic neuropathy (PON) is one of the rarest paraneoplastic syndromes. In the literature, ophthalmic involvement affecting vision as paraneoplas-



**Figure 4.** Bilateral significant reduction in retinal nerve fiber layer, especially in the temporal quadrant

tic neurological syndrome (PNS) has been reported as 0.01% [1,6]. Paraneoplastic eye involvement has been reported most commonly as cancer-related retinopathy (CAR) and melanoma-associated retinopathy (MAR), and PON is rarely observed [4]. PON was first reported by Pillay et al. in 1984 [7]. In the study performed by Malik et al. in 1992, reactive serum antibodies were detected in the neuronal and glial cytoplasm of a 63-year-old patient with SCLC, who developed bilateral subacute vision loss. This is the first study reporting that paraneoplastic optic neuropathy develops on an immunological basis [8].

CV2/CRMP5 is a neuronal antigen that was first defined as a paraneoplastic marker by Honnorat et al. in 1996 [9]. CRMP (collapsin response-mediating proteins) is an important protein that plays a regulatory role in the neurogenesis stage [10]. In particular, the CRMP-5 subtype is found in retina, optic nerve, central and peripheral neurons. Studies have shown that CRMP neuronal antigen is excessively produced in the cytoplasm of tumour cells in small cell lung cancer [5,11]. Cross-reaction between the protein in the tumour cell and the CRMP-5 antigen in healthy neuronal tissue is an accepted approach to explain the pathogenesis of paraneoplastic symptoms [2]. In addition, the widespread presence of this protein in peripheral neurons in the body also explains other non-specific neurological findings [3].

In 2001, Yu et al. evaluated 116 anti-CRMP5 seropositive patients. In the study, 47% of the patients had peripheral neuropathy, 31% autonomic neuropathy, 26% cerebellar ataxia, 25% subacute dementia, 17% cranial neuropathy (10% loss of smell and taste, 7% optic neuropathy). In addition, lung cancer, especially

the small cell subtype, was detected in 77% of these patients [5].

In another study on this subject, Cross et al. in 2003 included 172 CRMP5-IgG seropositive patients. Optic neuritis was reported in 16 of the patients included in the study. The age distribution of 16 patients was between 52 and 74 years, and all of them were smokers. The visual acuities of the patients ranged between 20/20 and 20/400, and cells were observed in the vitreous of 9 patients [11]. In the study, SCLC was detected in the vast majority (11/16) of the patients, as in other studies [5,11].

## CONCLUSION

The case discussed in our article is that of a paraneoplastic optic neuropathy patient, accompanied by peripheral neuropathy, as in other cases presented in the literature. Our case differs in those cells were observed in the anterior chamber and vitreous during follow-up. Another feature that makes our case different were the inadequate biopsy and imaging results. Despite the limited number of patients with PON reported in the literature, advanced age, smoking, painless subacute vision loss, optic disc oedema are common features [12]. Paraneoplastic optic neuropathy should be considered in patients presenting with this clinical picture and, as in our case, it is necessary to insist on research in this direction. We think that the CV2/CRMP5 antibody test may guide the differential diagnosis of patients presenting with the clinical picture described above, thus providing early diagnosis of malignancy and preventing mortality.

## LITERATURE

- Darnell RB, Posner JB. Paraneoplastic syndromes affecting the nervous system. *Semin Oncol.* 2006;33(3):270-298. doi: 10.1053/j.seminoncol.2006.03.008
- Rahimy E, Sarraf D. Paraneoplastic and non-paraneoplastic retinopathy and optic neuropathy: evaluation and management. *Surv Ophthalmol.* 2013;58(5):430-458. doi: 10.1016/j.survophthal.2012.09.001
- Voltz R. Paraneoplastic neurological syndromes: an update on diagnosis, pathogenesis, and therapy. *Lancet Neurol.* 2002;1(5):294-305. doi: 10.1016/s1474-4422(02)00135-7.
- Damek DM. Paraneoplastic Retinopathy/Optic Neuropathy. *Curr Treat Options Neurol.* 2005;7(1):57-67. doi: 10.1007/s11940-005-0007-1
- Yu Z, Kryzer TJ, Griesmann GE, Kim K, Benarroch EE, Lennon VA. CRMP-5 neuronal autoantibody: marker of lung cancer and thymoma-related autoimmunity. *Ann Neurol.* 2001;49(2):146-154.
- Darnell RB, Posner JB. Paraneoplastic syndromes involving the nervous system. *N Engl J Med.* 2003;349(16):1543-1554. doi: 10.1056/NEJMra023009
- Pillay N, Gilbert JJ, Ebers GC, Brown JD. Internuclear ophthalmoplegia and "optic neuritis": paraneoplastic effects of bronchial carcinoma. *Neurology.* 1984;34(6):788-791. doi: 10.1212/wnl.34.6.788
- Malik S, Furlan AJ, Sweeney PJ, Kosmorsky GS, Wong M. Optic neuropathy: a rare paraneoplastic syndrome. *J Clin Neuroophthalmol.* 1992;12(3):137-141.
- Honnorat J, Antoine JC, Derrington E, Aguera M, Belin MF. Antibodies to a subpopulation of glial cells and a 66 kDa developmental protein in patients with paraneoplastic neurological syndromes. *Journal of Neurology, Neurosurgery & Psychiatry.* 1996;61(3):270-278. doi: 10.1136/jnnp.61.3.270
- Chan JW. Paraneoplastic retinopathies and optic neuropathies. *Surv Ophthalmol.* 2003;48(1):12-38. doi: 10.1016/s0039-6257(02)00416-2
- Cross SA, Salomao DR, Parisi JE, et al. Paraneoplastic autoimmune optic neuritis with retinitis defined by CRMP-5-IgG. *Ann Neurol.* 2003;54(1):38-50. doi: 10.1002/ana.10587
- Nakajima M, Uchibori A, Ogawa Y, et al. CV2/CRMP5-antibody-related Paraneoplastic Optic Neuropathy Associated with Small-cell Lung Cancer. *Intern Med.* 2018;57(11):1645-1649. doi: 10.2169/internalmedicine.9736-17