

# AMNIOTIC MEMBRANE TRANSPLANTATION AT THE DEPARTMENT OF OPHTHALMOLOGY, UNIVERSITY HOSPITAL BRNO

Zemanová M.<sup>1</sup>, Pacasová R.<sup>2</sup>, Šustáčková J.<sup>1</sup>, Vlková E.<sup>1</sup>

<sup>1</sup>Department of Ophthalmology, University Hospital and Faculty of Medicine, Masaryk University, Brno

<sup>2</sup>Department of Transfusion and Tissue Medicine, University Hospital, Brno

*The authors of the study declare that no conflict of interests exists in the compilation, theme and subsequent publication of this professional communication, and that it is not supported by any pharmaceuticals company. The study has not been submitted to any other journal or printed elsewhere.*

Received: 28 October 2020

Accepted: 16 January 2021

Available on-line: 1 May 2021



MUDr. Markéta Zemanová, Ph.D.  
Oční klinika Fakultní nemocnice  
a Lékařské fakulty Masarykovy  
Univerzity Brno  
Jihlavská 20  
625 00 Brno  
E-mail: zem.marketa@centrum.cz

## SUMMARY

**Background:** The aim of the work is a discussion of amniotic membrane transplantation at the Eye Clinic of the University Hospital Brno and a retrospective evaluation of a group of patients for the period 2014–2019 who were treated for various indications.

**Methods:** Retrospective evaluation of the number and effectiveness of individual types of amniotic membrane in a group of patients after amniotic membrane transplantation (AMT) for various indications. A total of 134 patients were included in the study group, of which 68 were men and 66 were women. The median age was 70 years. The total number of amniotic membrane transplants performed during the selected six years was 139, with half the distribution using frozen (69 eyes) and lyophilized amniotic membrane (70 eyes). The AMT technique was chosen based on the initial finding and diagnosis. The type of amniotic membrane used (lyophilized vs. frozen) depended on the urgency of the procedure.

**Results:** The number of amniotic membrane transplantations was evaluated in a group of 134 patients (139 eyes) and their effectiveness in individual diagnoses was demonstrated. During the follow-up period, more transplantations of amniotic membranes were performed during hospitalization than in the outpatient department, both types of membranes (frozen and lyophilized). Amniotic membrane transplantation during hospitalization was performed in 89 eyes, in the outpatient mode in 50 eyes. Indications for amniotic membrane transplantation included microperforation and corneal perforation (30 eyes), non-healing corneal defects (21 eyes), descemetocoele (19 eyes), neurotrophic defects (16 eyes), ablation of pterygium (12 eyes) and corneal lysis (11 eyes). Other conditions (conjunctival lesions, fornix reconstruction, burns, peripheral ulcerative keratitis, ocular cicatricial pemphigoid and keratectomy) were represented in smaller numbers. Despite the very diverse group of indications and the advanced age of the patients, a very good efficacy of the performed amniotic membrane transplantations was found. Some patients died during the follow-up period, so the limitation of work is short and unequal follow-up period.

**Conclusion:** The success of the procedure depends not only on the correct timing, indication and technique of transplantation, but also on patient compliance and well-functioning cooperation of regional ophthalmologists.

**Key words:** amniotic membrane, amniotic membrane transplantation, ocular surface, inlay technique, onlay technique

Čes. a slov. Oftal., 77, 2021, No.2, p. 62–71

## INTRODUCTION

The amniotic membrane is a source of stem cells, and has excellent regenerative properties. Transplantation of an amniotic membrane has been used for more than a decade in the field of ophthalmology. This concerns allogenic transplantation. Today this ranks among very effective and safe types of eye surgery, for the treatment of various pathologies of the ocular surface, for regeneration of otherwise non-healing corneal defects and in reconstructions of the ocular surface. In clinical practice it is used in order to support epithelialisation of the cornea, for coverage of loss defects following surgical excisions, and for alleviation of inflammatory changes of the ocular surface.

The aim of this study is to present a discussion of amniotic membrane transplantation at the Department of Ophthalmology at the University Hospital in Brno, and a retrospective evaluation of a cohort of patients over a 6 year period (2014–2019), who were operated on due to various different indications.

## AMNIOTIC MEMBRANE

### History, present and future

The human amniotic membrane has been used in medicine for over one hundred years, for the purpose of healing wounds. Its role in the last few decades has been extended into several fields of medicine (ophthalmology, stomatolo-

gy, podiatry, diabetology, gynaecology, plastic surgery, neurosurgery, urology, abdominal surgery and orthopaedics). The amniotic membrane is used across medical disciplines for covering and treating acute and chronic wounds, in reconstructive operations, for the prevention of adhesion and support of healing. The first use of an amniotic membrane (hereinafter referred to as AM) is documented in the Johns Hopkins publication from 1910, in which Davis attempted to use the lining of an amniotic sac as a skin graft. Although he did not demonstrate favourable results, he recognised that the material could be highly useful and should be the subject of further examination and development of the correct technique of use. In 1913, two doctors performing skin transplantations independently, stated slightly different techniques of the use of the AM, and their results were highly successful ("the amniotic membrane is essentially an embryonic offshoot of the skin"). The use of the AM thus spread across disciplines, and it was used as a matrix upon which healthy tissue could grow, or as a barrier for cicatricial tissue and adhesion [1]. In the field of ophthalmology, a live foetal membrane incorporating both embryonic layers (amnion and chorion) was first used by De Rotthem in 1940 in the reconstruction of a conjunctiva (patients with symblepharon and following chemical burns). However, the success rate of this procedure was very low. In the same year, Brown used a rabbit's peritoneum as a temporary patch for burns of the ocular surface. The idea of covering the ocular surface was then modified by Sorsby in 1946 and 1947 by the use of a human amniotic membrane [2]. Sorsby successfully used an AM in patients following chemical burns. After this, there is a complete lack of publications on the use of AM in ophthalmology until the beginning of the 1990s. At the annual research congress of the Bascom Palmer Eye Institute in 1992, the ophthalmologist Batlle presented the results of the use of an AM as an allogenic transplant for plastic surgery of the conjunctiva in a cohort of his patients. The advantages of the use of this tissue stimulated Tseng's interest in the procedure. In 1997 Tseng founded the Bio-Tissue company, producing a unique cryo-conserved amniotic membrane preparation (Prokera), which is reinforced in a special ring. Other companies offer lyophilised AMs, which are applied to the cornea with the aid of a contact lens. With regard to the methods of conservation, it is possible to store these membranes for years. Research and development of the possibilities of the use of AM is continually progressing [1]. Discoveries include AM extracts (AME), AME eye drops (AMEED) or drops from cytokine extract, which have now been successfully used on patients with dry eye syndrome or following chemical burns [3]. However, to date there is an insufficient amount of clinical trials with these preparations. Regenerative Network International launched human amniotic fluid (HAF) drops on the market for the treatment of dry eye syndrome. The future of the AM in ophthalmology lies in the development of extracts and eye drops for pathologies of the anterior segment of the eye [1].

**In the Czech Republic,** the history of amniotic membrane use dates back only as far as the end of the 1990s. Specially at the Department of Ophthalmology at the


University Hospital in Brno, an amniotic membrane produced by a local tissue bank was first used in 2002. Since 2003, amniotic membrane transplantation has been covered by health insurance under its own code.

### Definition and histology

The amniotic membrane is of human origin (allogenic). After transplantation it is immunologically inert. It concerns the innermost layer of the placenta a thin, transparent, avascular membrane encasing the placenta and passing onto the foetus, which it thereby protects. The amniotic sac surrounding the foetus is composed of two main layers: the amnion (inner layer in contact with the amniotic fluid) and the chorion (outer layer in contact with the maternal cells). The amniotic membrane is a part of the amnion, and is composed of one layer of epithelial cells, a strong basal membrane and an avascular stromal matrix with a large quantity of collagen (Fig. 1). The apical surface of the amniotic cells has several microscopic protrusions (microvilli), and on the basal side the projections of the cells extend into the basal membrane. The connections of the epithelial cells to the basal membrane are mediated by hemidesmosomes. The nucleus is often large and homogeneous, with intensive intercellular and transcellular transport. The thickness of the AM is 0.02 – 0.5 mm. The AM contains pluripotent cells, highly organised collagen, laminin, antifibrotic and anti-inflammatory cellular signalling proteins (cytokines), immunomodulators, growth factors and matrix proteins. The AM has anti-inflammatory, anti-angiogenic, immunomodulatory, antibacterial, angiomodulatory and anti-cicatricial effects. The effects of the AM are ensured by the presence of growth factors supporting healing, which have been isolated from the epithelium and from the stroma. These include epidermal growth factor (EGF), hepatocyte growth factor (HGF), basic fibroblast growth factor (bFGF) and transforming growth factor TGF). Structural proteins (laminin, collagen type VII) in the basal membrane of the AM explain the epitheliotropic effects. Collagen type I, III, IV and V is a source for regeneration of the cornea. Thanks to neurotrophic substances, the AM is ideal for reconstruction of the epithelium of the ocular surface. Inhibition of transforming growth factor protein (TGF- $\beta$ ) in corneal and conjunctival fibroblasts in vitro explains the effect in the treatment of various cicatricial disorders of the ocular surface. In ophthalmology, the AM is used for reconstruction of the ocular surface following surgical procedures, for supporting healing or as protection against lysis (melting) of the cornea. Anti-inflammatory cytokines (e.g. IL-10) are released in the epithelium and stroma, and modulate inflammatory processes. Thanks to this, the AM plays a role in the healing of acute chemical burns of the cornea. At the same time, the AM has an immunomodulatory effect, and as a result rejection of tissue in transplantation is observed only very rarely in clinical practice [3,4,5].

### Preparation, processing and storage

The amniotic membrane is procured in an aseptic manner in birth by Caesarian section, in which selection of the membrane is performed only in uncomplicated ca-



**Fig1.** Transmission electron microscopy of amnion [4]

Apical border of amniotic epithelial cells contains a large number of microvilli. Cytoplasm contains numerous vesicles. Basal cell processes (pedicels) extend into basement membrane. Underlying connective tissue has a homogeneous structure.

ses, usually in planned sections. In the case of the mother's consent for donating the placenta after birth for medical purposes or further research, samples of the mother's blood are taken before birth for a serological examination of monitored blood-transmitted infections (hepatitis B, C, HIV infection, syphilis). After surgical birth, the placenta is removed by the doctor, after the removal of the child from the womb. Following its removal, the placenta is usually examined with regard to its integrity, and then liquidated as biological waste (this concerns tissue removed from the body for other reasons). If the mother consents to donating the placenta for further processing and preparation of products for medical purposes or other research, the placenta is placed in sterile wrapping and a protective transport container, and transported to a tissue facility for treatment (e.g. the National Tissue and Cells Centre in Brno, and other facilities of the same type e.g. in Jihlava or Prague). Transport takes place at a temperature of +2 to +8 °C, immediately after wrapping, so that the placenta can be processed within 24 hours of its removal from the mother. Processing is performed within a grade A cleanroom according to the requirements of good manufacturing practice (GMP). The amniotic membrane is prepared from the placenta. During processing, a physiological solution, antibiotic (gentamicin) and antiseptic staining (crystal violet) are used. The AM is placed on a carrier (Sanatyl 20) and conserved. The final product is packaged and indicated according to the approved specifications. The placenta is obtained from live donors in accordance with the requirements of the Czech legislation, specifically Act no. 285/2002 Coll. (Transplantation Act), Act no. 296/2008 Coll. (Human Tissues and Cells Act) and Decree no. 422/2008 Coll. (on safeguarding the quality and safety of human cells and tissues), all as amended by the later prescriptions. Persons who represent a heal-

th risk for the recipient of the tissue product (patient) are excluded from donating. A blood sample is taken from all donors in order to examine for signs of infection with HIV type 1 and 2 (HIV 1 and 2 Ag/Ab), hepatitis B virus (HBsAg, HBc total Ab), hepatitis C virus (HCV Ab), HTLV type I and II (HTVL 1 and 2 Ab) and *Treponema pallidum* (syphilis), both at the time of sampling of the tissue and once again after the elapse of at least 180 days since the initial sampling. The manufactured products (amniotic membranes) are released for distribution and use for patients only in the case of negative results of all the above examinations from both blood samples. Despite the careful selection of donors and the conducted laboratory examinations, **adverse reactions** include the transmission of causative agents of infectious diseases. It is also possible to expect a local immune reaction, even despite the reduction of the immunogenic properties of the tissue by means of its processing. It is the duty of healthcare staff who suspect an adverse reaction or record an adverse event to report such occurrences [6,7].

### Types of amniotic membrane

**Lyophilised amniotic membrane.** This type is an amniotic membrane of human origin, allogenic, sterile, lyophilised, placed on a carrier (Sanatyl 20), in which the amniotic part adjoins the carrier. After preparation, the tissue is stretched onto the Sanatyl 20 and conserved by lyophilisation (freeze-dried), residual moisture is ≤ 6 %. The final product of the amniotic membrane is individually sterile packaged into an aluminium or paper foil wrapping, which is placed in a secondary foil packaging. This is indicated with a final label and then inserted into a paper package. A lyophilised amniotic membrane can be stored at room temperature in a dry place for a period of 5 years from the date of processing of the tissue (expiry is stated on the final product label) [6].

**Frozen amniotic membrane.** This type is an amniotic membrane of human origin, allogenic, sterile, deep frozen. In processing the amniotic membrane is dehydrated, cleaned and stretched onto a carrier. A graft is formed by a piece of amniotic membrane on a carrier, which is inserted into a solution of 50 % glycerol and 50 g/l of human albumin in a ratio of 1:2, in a glass bottle closed with a stopper (primary package). The bottle with the graft is packaged together with a package leaflet, return form and report on postoperative complications in a box indicated with a purple label and frozen at a temperature of -80°C. A frozen amniotic membrane contains residues of the antibiotic gentamicin. It can be stored at a temperature of -20°C and lower for a period of 1 month, or at a temperature of -80°C and lower for a period of 2 years from the date of processing of the tissue (expiry is stated on the final product label) [7].

### Preparation of tissue for use

The tissue is taken from the transit thermo-box together with the accompanying documentation, the outer protective packaging is removed and the integrity of

the wrapping is checked. In the case of a frozen amniotic membrane, after removal from the box and inspection of the integrity of the wrapping it is necessary to leave the graft to defrost at room temperature for a period of 15 – 20 minutes. If the wrapping is intact, the secondary wrapping is opened and the tissue in the primary wrapping is placed aseptically onto a sterile field. Further handling is performed only in sterile environment. The primary wrapping is opened, the tissue is removed and placed on the wound. The doctor performs sterile removal of the carrier, and applies this side of the tissue to the defect. It is possible to hydrate the tissue before application. If the tissue is not used within two hours of unwrapping, sterility and hydration must be ensured in a physiological solution at a temperature of +2 to +8 °C. The hydrated tissue must be used within 24 hours or liquidated. The unwrapped tissue cannot be repackaged, refrozen or stored a second time [6,7].

### INDICATIONS for amniotic membrane transplantation

Amniotic membranes are used for therapy of the ocular surface. Indications for amniotic membrane transplantation (AMT) cover conditions in which there is a risk of corneal scarring, pathologies limiting regeneration of the nerves (e.g. neurotrophic keratitis), severe forms of dry eye syndrome in which conservative therapy fails, and other pathologies of the ocular surface [1]. Before the transplantation itself, it is necessary to select a suitable patient and to ensure appropriate indication of the patient for surgery (with regard to time, diagnosis and therapy). The amniotic membrane is used either as a layer for covering the ocular surface (here the main role is re-epithelialisation of the surface) or as a graft, which has the potential to integrate into the ocular surface. Before the actual procedure, it is essential to perform a calculation examination for bacteriology, to conduct a diagnosis of

viruses on PCR and to perform a cultivation examination for yeasts and fungi, and if applicable also an examination for chlamydia. Only when the swabs are sterile is it suitable to indicate AMT. In the case of danger of or already certain corneal perforation, the practice is not to wait for the results of the swabs and to treat the defects as soon as possible. This concerns an indication for acute suturing of the amniotic membrane to the defect (Table 1).

### Reconstruction of corneal surface

Persistent defects of the epithelium and ulceration are one of the most common indications for AMT, in which AM is used as a substitute of the basal membrane. A multilayer technique is used for the treatment of deep corneal ulcers, descemetoceles and small corneal perforations. Indications for reconstruction of the corneal surface are presented in table 2. Calcification of the ocular surface is sometimes observed as a postoperative complication [8]. An example of the use of an amniotic membrane in the case of a non-healing epithelial defect is illustrated in fig. 2.

### Acute chemical injuries to the eye

Chemical burns of a severe degree lead to complete erosion of the cornea, ischemia of blood vessels in the region of the limbus and in the conjunctiva, and to destruction of limbal stem cells. The role of AMT is to avert necrosis and to achieve rapid epithelialisation of the cornea. Timely AMT improves functional results and reduces the formation and progression of symblepharon [8]. The use of an amniotic membrane in the case of acute chemical burn is documented by fig. 3.

### Replacement of limbal epithelium

A deficit of limbal stem cells is characterised by the formation of fibrovascular tissue (pannus) on the surface of the cornea, increased sensitivity to dazzling (photo-

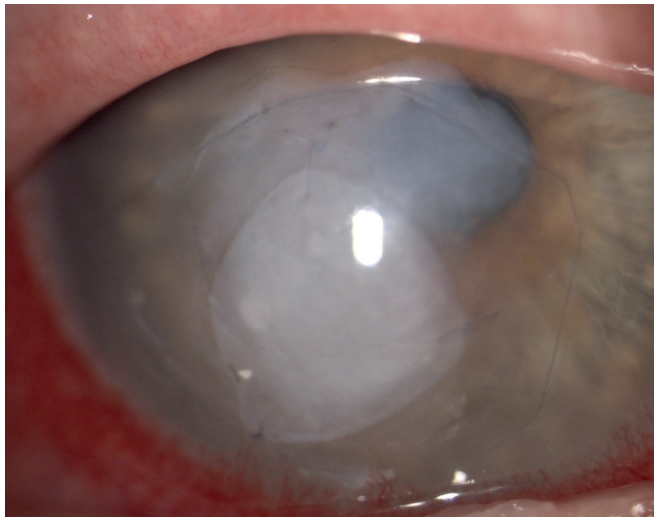
**Table 1.** Amniotic membrane to defect [8]

Amniotic membrane to defect	
Bacterial keratitis, corneal ulcer	Corneal perforation (imminens)
Herpetic keratitis	Microperforation
Acanthamoeba	Corneal lysis
Peripheral ulcerative keratitis	Exposure keratitis
Mooren's ulcer	Neurotrophic keratitis

**Table 2.** Indications for corneal surface reconstruction [8]

Reconstruction of corneal surface
Persistent epithelial defect with stromal ulceration
Acute chemical burns
Conditions after removal of epithelial or subepithelial lesions: band keratopathy, scars, tumors, pterygium
Painful bullous keratopathy
Partial or complete limbal stem cell deficiency





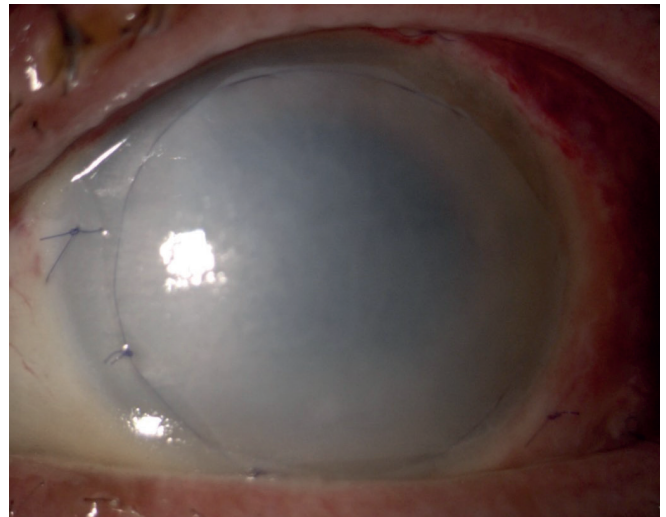
**Fig. 2.** Use of amniotic membrane in case of non-healing defect of corneal epithelium

phobia) and loss of sight [8]. Loss of limbal cells occurs following chemical and thermal injuries, in the case of keratopathy and in long-term wearers of contact lenses, following numerous surgical procedures, following cryotherapy in the region of the limbus and upon Stevens-Johnson syndrome. A deficit of limbal stem cells is characteristic in the case of neurotrophic keratopathy, aniridia, bullos keratopathy, chronic limbitis, peripheral ulcerative keratitis and upon keratitis associated with endocrine disorders.

#### Reconstruction of conjunctival surface

An amniotic membrane can be used to cover large surface defects following complete excision of tumours, scars or extensive pterygia in the region of the conjunctiva. AM functions here as a substitute for the basal membrane, and supports the migration of the neighbouring epithelial cells of the conjunctiva to the recipient. AMT is cosmetically more acceptable than other methods (e.g. transplantation of buccal mucosa). Indications for reconstruction of the conjunctiva are presented in table 3.

The use of amniotic membranes in ophthalmology is expanding also into the realm of **vitreoretinal surgery**, in which its effectiveness is tested in maculopathy of the pit of the optic nerve papilla [9] or for closure of macular



**Fig. 3.** Use of amniotic membrane in acute chemical burns

hole and retinal cracks [10].

**A relative contraindication** for the use of an amniotic membrane is allergy to gentamicin and crystal violet. Absolute contraindications are unknown.

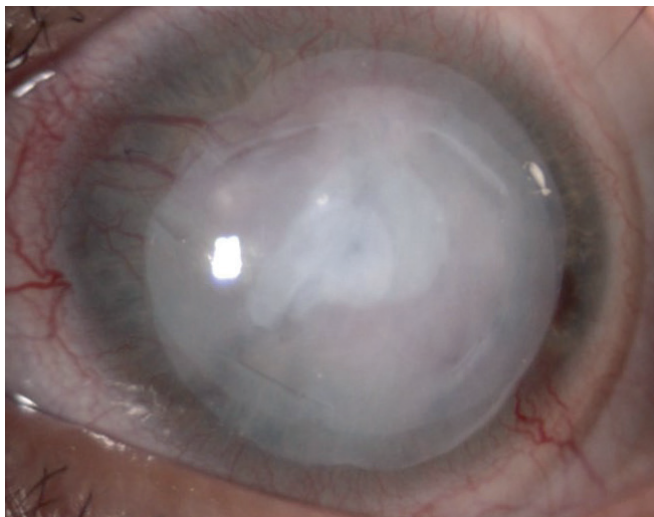
## TECHNIQUES OF AMNIOTIC MEMBRANE TRANSPLANTATION

#### Inlay (graft) technique

Using this technique of “grafting” or “inlay”, a graft of the amniotic membrane is used as a permanent replacement for the basal membrane. The main indications are persistent defects of the epithelium, corneal ulceration or defects following excision of conjunctival pathologies. After cleaning (debridement) of the wound, the AM is sutured (by continuous or individual suture) by the side of the epithelium/basal membrane in an outward direction, so that the adjacent epithelial cells of the recipient migrate to it and the wound is closed. In the case of deep defects and ulcerations, more layers of the AM are used. Epithelialisation of the amniotic membrane integrates into the host tissue, and the AM remains detectable for months, sometimes years. In the case of corneal defects, it is in fact colonised by local keratocytes [8].

**Table 3.** Indications for conjunctival surface reconstruction [8]

Reconstruction of conjunctival surface
Acute chemical burns
Acute Stevens-Johnson syndrome
Covering defects after removal of large conjunctival lesions (tumors, neoplasm, scars)
Symblepharon, fornix reconstruction
Bleb revision (in case of excessive filtration)
Pterygium
Scleral thinning



**Fig. 4.** Inlay and onlay technique

### **Onlay (patch, overlay) technique**

Using this technique, a large amniotic membrane is temporarily placed on the ocular surface as a “patch”. The AM is then usually separated from the surface of the cornea after one to two weeks. Indications cover conditions of delayed or defective healing, including acute burns, acute herpetic keratitis or acute stage of Stevens-Johnson syndrome. In these indications especially, the anti-inflammatory mechanisms of the effect are utilised. The orientation of the amniotic membrane plays only a small role in this surgical procedure [8].

### **Inlay and onlay technique**

This technique, also known as the sandwich technique, is a combination of the above two procedures. It is used in the case of serious defects of the ocular surface (deep and extensive corneal ulceration, microperforation). The main purpose is to protect the inlay and support its epithelialisation. This combined method has a high success rate (65 % to 80 %) and a low degree of recurrence (approximately 20 % to 35 %) [8]. The combined technique is illustrated in fig. 4.

### **Amniotic membrane as cultivation substrate and carrier**

In this technique, the amniotic membrane is placed on the ocular surface together with cultivated cells, and functions as a biomatrix. It is used for the treatment of a deficit of limbal stem cells or in the reconstruction of superficial defects of the ocular surface [8].

**Multilayer technique** is used for the treatment of deep corneal ulcerations, descemetocoeles and small perforations of the cornea [8].

## **COHORT AND METHOD**

Evaluation of the number and effectiveness of individual types of amniotic membrane on a cohort of patients operated on at the Department of Ophthalmology, University Hospital Brno in the years 2014-2019 (specifically in the

period from 1.1.2014 to 30.12.2019) for various different indications. This is a retrospective observation of patients following amniotic membrane transplantation (AMT). The observed cohort included a total of 134 patients, of whom 68 were men and 66 women. The median age was 70 years (youngest patient aged 22 years, oldest patient aged 91 years). The total number of performed amniotic membrane transplantations during the six year period was 139. This concerned 139 eyes of 134 patients (in 1 patient both eyes were operated on, 4 other patients were operated on twice consecutively), in which the ratio of the use of a frozen (total 69 eyes) and lyophilised amniotic membrane (total 70 eyes) was half and half. All the patients underwent a comprehensive initial examination (determination of uncorrected and best corrected visual acuity, performance of autorefractometry, measurement of intraocular tension – only if no baseline microperforation of the cornea was present, examination on a slit lamp, fluorescein staining of the cornea), photo documentation of the anterior segment of the eye was taken and clinical tests were conducted (Schirmer test, break-up time test). In all the tested subjects, before the indicated procedure, swabs from the conjunctival sac were taken for bacteriology (cultivation and sensitivity to antibiotics), a PCR diagnosis of viruses was performed, as well as a parasitological and mycological examination. The procedure was always performed under local anaesthesia (procedures under general anaesthesia were excluded from the cohort). The patients were operated on by five different microsurgeons, whose surgical procedure was similar. The technique of AMT (inlay, onlay, combination of both techniques or suturing of amniotic membrane in several layers) was always chosen on the basis of the initial finding and diagnosis. The decision on the use of the type of amniotic membrane (lyophilised vs. frozen) depended on the urgency of the procedure. At the end of the procedure, a covering soft contact lens was always applied, left in situ always individually according to the indication and capacity for healing. After the procedure, broad-spectrum antibiotics were applied in decreasing frequency until complete epithelialisation of the amniotic membrane, artificial tears without preservative agents were applied at minimum five times per day, and in indicated cases also weak steroids were transitionally administered. In the postoperative period, the patients were monitored at our clinic, including regular photo documentation, if their commuting distance and overall condition of health so permitted.

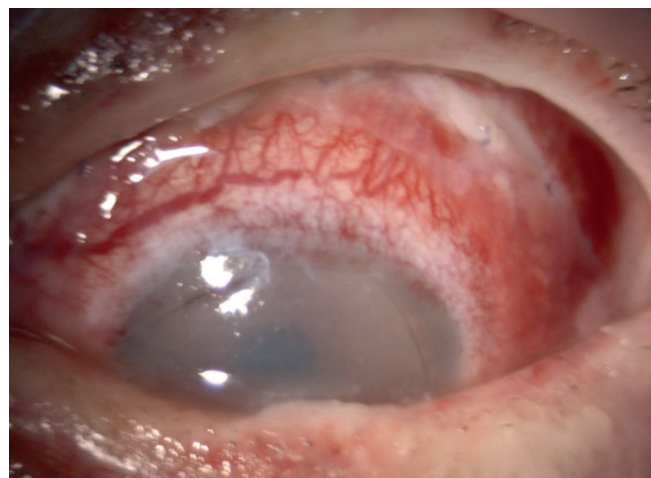
## **RESULTS**

In a cohort of 139 eyes of 134 patients, the number of amniotic membrane transplantations was evaluated, and their effectiveness in individual diagnosis was demonstrated. In one patient both eyes were operated on together. In 4 patients the operation on the affected eye was performed twice consecutively (retransplantation) with a certain time interval, due to failure of the first transplantation. The first of these cases was a woman (91 years) with descemetocoele upon a background of recurring herpetic

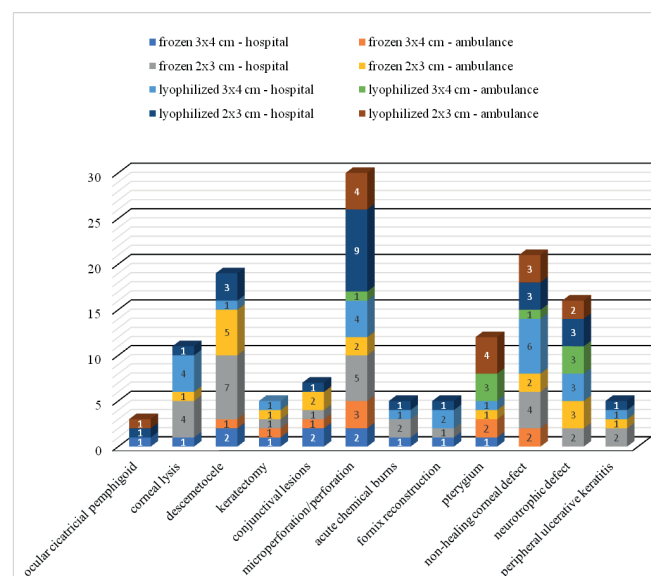
keratitis. The second was a man (50 years) with metaherpetic keratitis and lysis of the corneal transplant, in whom a second transplantation was performed with a frozen amniotic membrane, which evidently appropriately stabilised the local finding. The third patient (man, 23 years) had suffered a severe trauma to the eye caused by a firework, and twice consecutively (within the course of two months) underwent reconstruction of both fornices with a frozen amniotic membrane, (Fig. 5), unfortunately due to continuing progression of scarring of the fornices a plastic adjustment was then performed in the third surgical procedure, with the aid of a graft of the buccal mucosa. The fourth patient (man, 79 years) was operated on twice during the course of one year following an old chemical burn to the eye, with residual light perception and progression of descemetocoele upon a background of recurring herpetic keratitis, in which a frozen amniotic membrane was applied across the entire cornea, and subsequently, due to failure of the procedure, resuturing of the blind eyeball with the conjunctiva was performed.

As presented in table 4, more amniotic membrane transplantations were performed during hospitalisation than in the outpatient department for both types of membranes (frozen and lyophilised). Amniotic membrane transplantation in hospitalisation was performed in a total of 89 eyes, in outpatient surgery an amniotic membrane was used on 50 eyes. The dependency of the used type and size of amniotic membrane on the diagnosis is illustrated by graph 1. The indications for the performed amniotic membrane transplantations at our clinic during the observation period were most frequently microperforations and corneal perforations (in a total of 30 eyes) – this most numerous group of AMT incorporated spontaneous (micro)perforations upon a background of bacterial keratitis (in 10 eyes), following repeated herpetic keratitis (16 eyes), upon a background of a severe course of acne rosacea (3 eyes) and Mooren's ulcer (1 eye). Further indications included non-healing corneal defects (21 eyes) and corneal lysis (11 eyes). Other conditions (conjunctival lesions, fornix reconstruction, chemical burns, peripheral ulcerative keratitis, ocular cicatricial pemphigoid and keratectomy) are represented in a smaller number. Out of the total number of 134 pati-

ents, 22 had keratoconjunctivitis sicca. The group of keratectomies (5 eyes) includes eyes following excision of corneal lesions. The precise number of AMTs according to the used amniotic membrane in individual indications is presented in table 5, the percentage representation of



**Fig. 5.** Fornix reconstruction with frozen amniotic membrane and covering of non-healing surface of cornea and conjunctiva



**Graph 1.** Numbers and types of amniotic membrane used depending on diagnosis

**Table 4.** Number of amniotic membrane transplantations performed at Department of Ophthalmology, University Hospital Brno in the years 2014–2019

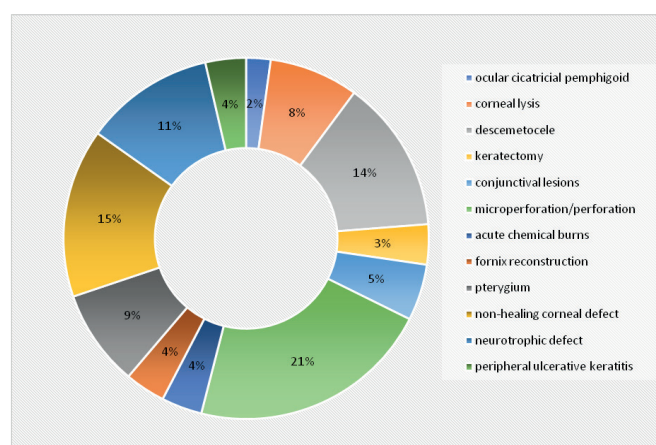
Number of amniotic membrane transplantations			
Type of amniotic membrane	hospitalisation	ambulance	TOTAL
frozen (size 3x4 centimetres)	12	10	22
frozen (size 2x3 centimetres)	29	18	47
FROZEN TOTAL	41	28	69
lyophilised (size 3x4 centimetres)	24	8	32
lyophilised (size 2x3 centimetres)	24	14	38
LYOPHILISED TOTAL	48	22	70
<b>TOTAL NUMBER</b>	<b>89</b>	<b>50</b>	<b>139</b>



individual diagnosis out of the total number of performed AMTs is illustrated in graph 2.

Despite the very diverse group of indications and the advanced age of the patients (median age 70 years), very good effectiveness of the performed amniotic membrane transplantations was determined retrospectively. Unfortunately some patients died during the course of the observation period, and a limitation of the study is therefore its short and unequal follow-up period.

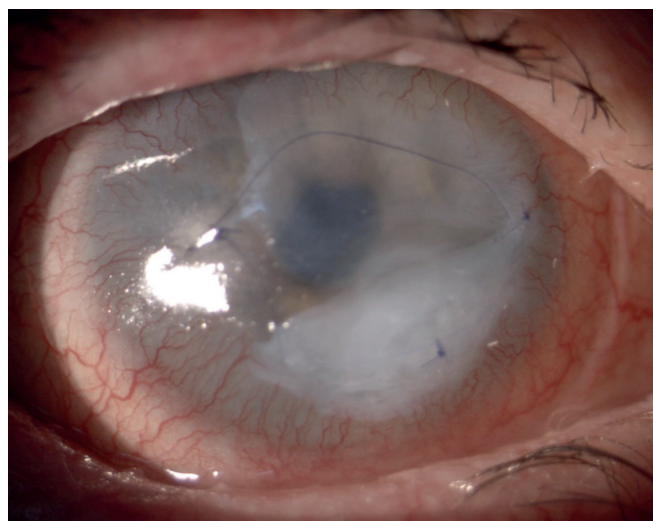A one hundred percent success rate of amniotic membrane transplantation was recorded in the group of reconstructions of the corneal surface in the case of keratectomy, non-healing corneal defects, peripheral ulcerative keratitis and corneal microperforation. In the group of conjunctival reconstructions, the amniotic membrane fulfilled its function over the long term in the case of ablation of a pterygium, and following excision of conjunctival lesions. In



**Graph 2.** Percentage of individual diagnoses out of the total number of performed amniotic membrane transplantations

these eyes (total number 69), no further surgical procedure was required after the performed amniotic membrane transplantation. Complete epithelialisation of the ocular surface was achieved in all of these patients.

In the group of neurotrophic keratitis (total 16 eyes), complete healing of the cornea took place in 14 eyes (87.5 % success rate of AMT). In one eye a small defect persisted even after a well performed transplantation. In one patient (73 year old man following repeated radiotherapy of ocular lymphoma) with neurotrophic keratitis and malpositioned eyelids in the sense of post-radiation entropy of both eyelids, on whom AMT with a frozen membrane in several layers was performed in 2018 (Fig. 6), enucleation of the dolorous blind eyeball was ultimately performed in 2020 upon the express wish of the pa-

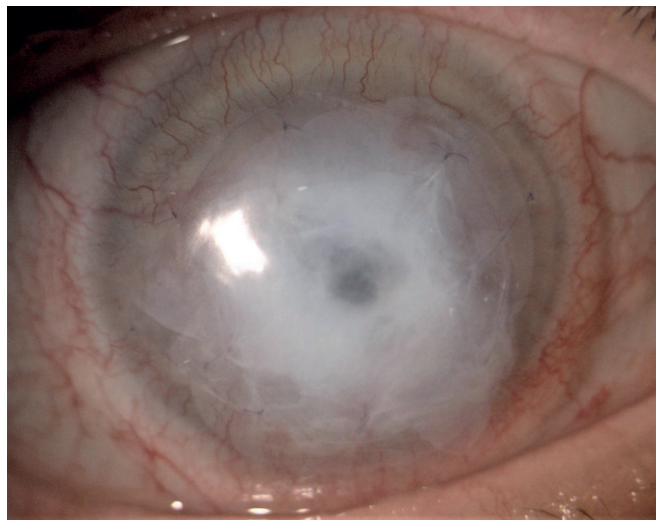

**Fig. 6.** Use of frozen amniotic membrane in neurotrophic keratitis

**Table 5.** Number of performed amniotic membrane transplantations according to the indication at Department of Ophthalmology, University Hospital Brno in the years 2014–2019

Amniotic membrane transplantations according to indication			
Indication	Frozen amniotic membrane (n=69)	Lyophilised amniotic membrane (n=70)	Cellkem
Microperforation/perforation	12	18	30
Non-healing corneal defect	8	13	21
Descemetocoele	15	4	19
Neurotrophic defect	5	11	16
Pterygium	4	8	12
Corneal lysis	6	5	11
Conjunctival lesions	6	1	7
Fornix reconstruction	2	3	5
Acute chemical burns	3	2	5
Peripheral ulcerative keratitis	3	2	5
Keratectomy	4	1	5
Ocular cicatricial pemphigoid	1	2	3
Total number of eyes (n=139)			





**Fig. 7.** Use of frozen amniotic membrane in descemetocoele

tient.

In the remaining group of eyes (total number 54 eyes), complications occurred or re-operations were performed in the postoperative period only in isolated cases in individual indications (ocular cicatricial pemphigoid, corneal lysis, descemetocoele, chemical burns, fornix reconstruction and corneal perforation). In the above-mentioned 4 patients, (two) repeated consecutive amniotic membrane transplantations were performed within a certain time frame. The worst results were recorded in patients with spontaneous corneal perforation following recurring herpetic keratitis with severe changes to the cornea. In the group of corneal perforations (total 11 eyes), corneal transplantation (perforating keratoplasty) was performed in 8 eyes, in which the procedure was always indicated after stabilisation of the finding, with the exception of one case upon a background of a severe course of acne rosacea with spontaneous corneal perforation in a young female patient (24 years). We recorded rapid progression of spontaneous corneal perforation (even despite initially well performed amniotic membrane transplantation) in a young male patient (31 years) with a pronouncedly thinned cornea upon a background of recurring herpetic keratitis and long-term therapy with local steroids, unfortunately in this patient the main reason for the failure of treatment was non-compliance. In the group of descemetoceles (19 eyes), good results were demonstrated in the postoperative period (Fig. 7), with the exception of the patient mentioned above (subsequent resuturing of the cornea with the conjunctiva), though three patients were entirely lost from the observation. In the group of corneal lysis or corneal transplant (total 11 eyes), stabilisation of the finding was demonstrated in 7 eyes, in 4 eyes perforating (re)keratoplasty was performed after a certain time interval. In eyes following chemical burns (5 eyes), the success rate of AMT in our cohort was 60 %, 3 eyes were healed, while one patient following severe chemical burns to the cornea is now awaiting the transfer of limbal stem cells, and another is awaiting corneal transplantation due to corneal leucoma. The group of fornix reconstructions (5 eyes) contained one

patient already mentioned above (fornix reconstructions – see fig. 5 – following the failure of amniotic membrane transplantation, a buccal graft was performed), as well as 3 eyes of patients with a plastic adjustment of the eye socket, 1 eye of 1 patient following treatment of symblepharon and fornix following an old chemical burn to the eye. The group of eyes with cicatricial pemphigoid (total 3 eyes of 2 female patients, one patient had both eyes operated on) recorded the worst results – both patients permanently wear a covering soft contact lens even despite initially well performed amniotic membrane transplantation.

Slightly better long-term results were recorded in the case of transplantation with a frozen amniotic membrane in comparison with a lyophilised membrane. At the University Hospital in Brno, a lyophilised amniotic membrane is immediately available (its storage at room temperature enables immediate use), while a frozen amniotic membrane must be ordered from the tissue bank in advance (one day). Therefore, in the case of an indication for the use of a frozen amniotic membrane, which is more flexible and stronger (although perioperative handling is more difficult than in the case of a lyophilised membrane), and the procedure can be deferred, the patient is prepared for the procedure (if applicable in hospitalisation) and the procedure is planned after ordering of the membrane.

The results are generally worse in patients with associated autoimmune disorders, immune deficits, systemic pathologies and of course in the case of non-compliance of the patient. In treatment it is always necessary to co-operate closely with specialists in other fields of medicines, including rheumatology, dermatovenereology and immunology.

## DISCUSSION

An article by Slovak authors from Bratislava dating from 2016 on experiences with amniotic membrane transplantation retrospectively evaluates a cohort of 71 patients (88 eyes), in which amniotic membrane transplantation was performed over a three year period (2013-2015) [11]. Our cohort retrospectively evaluates a longer period of time (6 year), with a larger cohort of transplantations (139 eyes of 134 patients). In both cohorts, the frequency of the procedures is adequately comparable. The Slovak authors evaluate indications, success rate and failure of AMT, and the number of re-transplantations. In the case of the Slovak authors, the most common indication for AMT was corneal ulcer of uncertain etiology (27 eyes) [11]. In our cohort of patients, the most common indications for AMT included non-healing corneal defects (21 eyes) and descemetocoele (19 eyes). The Slovak authors state bullous keratopathy (10 eyes) as the second most common indication [11]. In our cohort this indication does not appear whatsoever, which is due to the fact that at our centre we prioritise the performance of corneal transplantation (posterior lamellar or perforating keratoplasty) in the case of bullous keratopathy. In third place in terms of the number of performed AMTs, the Slovak authors state corneal ulcers upon a background of herpetic keratitis (8 eyes) [11], in our cohort the frequency of herpetic keratitis is comparable (16 eyes).

In the cohort of the Slovak authors, post-traumatic states are recorded in 6 eyes [11], in our cohort in 5 eyes. Our results show more frequent performance of AMT for neurotrophic corneal defects (16 eyes) and for ablation of pterygium (12 eyes) than in the case of the Slovak authors, who do not state the use of an amniotic membrane following ablation of pterygium whatsoever. The Slovak authors do not differentiate between the type of used amniotic membrane (frozen vs. lyophilised) or the conditions of transplantation (outpatient or hospitalised), which we focused on in our cohort, because we were interested in the statistics and any applicable differences regarding the individual types of membranes. With regard to the diversity of our cohort, and the fact that some patients died or did not report for a follow-up examination after the performed transplantation (despite efforts to contact them), it is not possible to evaluate any applicable failure of treatment reliably (this data was not a priority for our cohort). The Slovak authors state failure of the transplant in 17 eyes (i.e. 19.32 % of cases) [11]. Our cohort shows 4 amniotic membrane re-transplantations during the course of the observation period. We recorded one hundred percent success of AMT in 115 eyes.

## CONCLUSION

Amniotic membrane transplantation supports epithelialisation and the differentiation of the epithelium of the ocular surface, it has pro-angiogenic and anti-inflammatory effects, suppresses scarring, infection and alleviates pain. In a series of cases, by means of avoid amniotic membrane transplantation we avoid or at least defer the necessity of performing perforating keratoplasty of the cornea (or thanks to AMT we prepare the "terrain" for further transplantations). The results of amniotic membrane transplantation depend above all on correct indication, correct timing of the operation and on the technique of the performed procedure. The method effectively stabilises non-healing corneal defects in patients

with immunologically conditioned inflammations (patients with rheumatoid arthritis, acne rosacea) and complications of dry eye syndrome. Amniotic membrane transplantation produces good results also in patients with a breached corneal trophic (patients after pareses of the nervus trigeminus or following recurring herpetic keratitis). Amniotic membrane transplantation ranks among procedures that do not breach the integrity of the eyeball, and as a result represents a very safe method of treatment.

Within the observation period (2014-2019), more amniotic membrane transplantations were performed in hospitalisation than in outpatient surgery for both types of membranes (frozen and lyophilised). Amniotic membrane transplantation in hospitalisation was performed in a total of 89 eyes, in outpatient surgery an amniotic membrane was used on 50 eyes. The ratio of the use of a frozen (69 eyes) and lyophilised amniotic membrane (70 eyes) was practically half and half. The most common indications for AMT were microperforation and perforation of the cornea, non-healing corneal defects, descemetocoeles, ablation of pterygium and corneal lysis. In our cohort of patients, a 100 % success rate of the procedure was demonstrated in patients with non-healing corneal defects, peripheral ulcerative keratitis, microperforations, following keratectomies, following ablations of the pterygium or excisions of conjunctival lesions. In other indications, with only a few exceptions, there was a clearly high success rate of transplantation. In long-term observation, frozen amniotic membranes demonstrated better effectiveness. Unlike frozen amniotic membranes, lyophilised membranes are immediately available at our centre, and as a result the numbers of acute applications of an amniotic membrane to the cornea are higher in this group. The success rate of the procedure depends not only on correct timing, indication and technique of the transplantation, but also on patient compliance and well functioning co-operation of the local ophthalmologists

## LITERATURE

1. Moy AM. The History and Future of Amniotic Membrane Use in Medicine. *J Dry Eye Dis.* 2019;2:7-9. doi: 10.22374/jded.v2i1.9
2. Cason JB. Amniotic membrane transplant. 2020. Available from: [https://eyewiki.aaio.org/Amniotic\\_Membrane\\_Transplant](https://eyewiki.aaio.org/Amniotic_Membrane_Transplant)
3. Murri MS, Moshirfar M, Birdsong OC, et al. Amniotic membrane extract and eye drops: a review of literature and clinical application. *Clin Ophthalmol.* 2018;12:1105-1112. doi: 10.2147/OPTH.S165553
4. Dua HS, Azuara-Blanco A. Amniotic membrane transplantation. *Br J Ophthalmol.* 1999;83(6):748-752. doi: 10.1136/bjo.83.6.748
5. Azuara-Blanco A, Pillai CT, Dua HS. Amniotic membrane transplantation for ocular surface reconstruction. *Br J Ophthalmol.* 1999;83(4):399-402. doi: 10.1136/bjo.83.4.399
6. Národní tkáňové centrum. Amniová membrána lyofilizovaná. Příbalový leták. Available from: [www.natic.cz/docs\\_files/TD.132.CZ-Pribalovy-letak-amniova-membrana-lyofilizovana.pdf](http://www.natic.cz/docs_files/TD.132.CZ-Pribalovy-letak-amniova-membrana-lyofilizovana.pdf)
7. Národní tkáňové centrum. Amniová membrána zmrazená. Příbalový leták. Available from: [www.natic.cz/docs\\_files/tkanove-transplantaty-narodni-tkanove-centrum-amniova-membrana-zmrazena.pdf](http://www.natic.cz/docs_files/tkanove-transplantaty-narodni-tkanove-centrum-amniova-membrana-zmrazena.pdf)
8. Meller D, Pauklin M, Thomasen H, Westekemper H, Steuhl KP. Amniotic membrane transplantation in the human eye. *Dtsch Arztebl Int.* 2011;108(14):243-248. doi: 10.3238/arztebl.2011.0243
9. Rizzo S, Caporossi T, Pacini B et al. Management of Optic Disk Pit-associated Macular Detachment with Human Amniotic Membrane Patch. *Retina.* 2020; Jan 10. doi: 10.1097/IAE.0000000000002753
10. Rizzo S, Caporossi T, Tartaro R et al. Human Amniotic Membrane Plug to Promote Retinal Breaks Repair and Recurrent Macular Hole Closure. *Retina.* 2019;39(1):95-103. doi: 10.1097/IAE.0000000000002320
11. Krčová I, Stanislavová M, Peško K, Furdová A, Koller J. Možnosti použitia amniovej membrány – naše skúsenosti [Amniotic membrane applications-our experience]. *Cesk Slov Oftalmol.* 2016;72(6):204-208. Slovak.