

OCULAR CICATRICAL PEMPHIGOID – RETROSPECTIVE STUDY

SUMMARY

Introduction: Ocular cicatricial pemphigoid (OCP) is rare, severe, sight threatening autoimmune disease of the conjunctiva, which affects elderly patients, more often women.

Aim: To evaluate the success rate of stabilisation of ocular findings in patients with OCP.

Methods: Retrospective study of patients from Centre of Conjunctival and Corneal Diseases at Department of Ophthalmology, General University Hospital and 1st Medical Faculty of Charles University in Prague in 1992-2013 was performed. Frequency of OCP clinical stages, visual acuity (VA), disease activity and ocular complications of referred patients were monitored. Moreover, type of immunosuppressive (IS) therapy, the number of relapses of the disease and progress of OCP clinical stages were evaluated. Especially, we evaluated effects and side effects of mycophenolate mofetil (MM) therapy. In addition to that, type and frequency of ocular surgery that was carried out to the patients before and after the referral were recorded. Furthermore, we evaluated percentage of patients with mucous membranous pemphigoid (MMP). Also, the positive yield of diagnostic methods was assessed.

Results: The OCP was diagnosed and monitored in 51 patients (21 men and 30 women) during 21 years, the average age on the day of diagnosis was 68,4 years, the average period of observation was 57 months. 55 % of eyes were referred to our department at clinical stage 3, 27 % at stage 4. VA was maintained in 76 % of eyes, improved in 5 % of eyes and in 19 % of eyes deteriorated. Activity of OCP was detected during the first examination in 96 % of patients, the most common complications at that time was corneal ulcer or perforation. Patients were treated by immunosuppressive therapy, most often in combination: corticosteroids (47 patients), azathioprine (28 patients), cyclophosphamide (25 patients), MM (16 patients), sulphasalazine (5 patients), dapsons (5 patients). We ascertained relapses in 40 % of patients. The progression to the next stage of OCP were found in 7 eyes (6,9 %) and 95 eyes (93,1 %) remained stable. Activity of disease was well controlled in 11 patients out of 16 (69 %) by MM, IS therapy of remain 5 patients (31 %) had to be changed. Side effects of MM such as lymphopenia were present in 1 patient. Before OCP was diagnosed, patients underwent cataract surgery with the intraocular lens implantation, cryoepilation of eyelashes and eyelid plastic surgery, especially entropion. The most common indicated surgery in our clinic was amniotic membrane transplantation and retro position of muscular cutaneous leaf. 31 % of patients were diagnosed with MMP. Positive results of conjunctival biopsy were detected in 48 % from 42 examined samples and 22 % from 32 examined samples had positive results of indirect immunofluorescence (anti-desmosomes).

Conclusion: OCP diagnosis is established on the basis of patient's ophthalmic history and clinical findings. Positive results of direct and indirect immunofluorescence support the diagnosis. Activity of the disease and progression of OCP is effectively suppressed by systemic immunosuppressive therapy (for example MM), mainly if started at early stage of the disease.

Key words: ocular cicatricial pemphigoid, immunosuppressive therapy, direct and indirect immunofluorescence, mycophenolate mofetil

Čes. a slov. Oftal., 72, 2016, No. 1, p. 283–292

INTRODUCTION

Ocular cicatricial pemphigoid (OCP) is a rare, scarring disease of the conjunctiva, which is sight threatening due to its chronic and progressive course (20). It is part of a heterogeneous group of autoimmune subepithelial pustular pathologies known as mucous membrane pemphigoid (MMP), afflicting any mucous membrane including the oral and nasal cavities, throat, gullet, trachea, rectum, penis and cervical cavity (21). Within this group OCP occurs in up to 75% of cases. If a patient suffers only from affliction of the skin, the incidence of OCP is lower – 25% (24). On the other hand, as many as 50% of patients with OCP have at least one

extraocular affliction (36, 44). If therapy is not commenced, the pathology may even lead to death of the patient (most frequently due to gullet and tracheal strictures). It is necessary to treat up to 75% of patients with general immunosuppressive (IS) therapy (10).

According to the British Ophthalmological Surveillance Unit, the incidence of OCP is 0.7 per 1 000 000 of the population with regional variation to 1.1 per 1 000 000 of the population in Greater London and 1.8 per 1 000 000 of the population in the West Midlands (6, 34). The incidence in France and Germany has been recorded at 1.3 – 2.0 per 1 000 000 per year (3, 4). No racial or geographical predisposition has been recorded (3, 42). Mortality is stated at 0.29 per 1 000

Szabó E., Palos M., Skalická P.

Department of Ophthalmology, 1st Faculty of Medicine, Charles University in Prague and General University Hospital in Prague

Head: doc. MUDr. Bohdana Kalvodová, CSc.

The authors of the study declare that no conflict of interests exists in the compilation, theme and subsequent publication of this academic communication, and that it is not supported by any pharmaceuticals company.



Dr. Eva Szabó

Department of Ophthalmology, 1st Faculty of Medicine, Charles University in Prague and General University Hospital in Prague

U Nemocnice 2

128 00 Praha 2

Eva.Szabo@seznam.cz

000 of the population according to a study conducted in the USA in the period 1992-2002 (35).

The incidence is higher in women than in men, in a ratio of 2-3:1 (14). OCP is most frequently diagnosed after the 70th year of life (24), according to Foster the average age is 65 years (14). In rare cases children may also be affected (25).

A genetic predisposition is assumed in connection with the presence of the gene HLA – DQ7 (HLA-DQB1*0301). External influences are significantly applied (2).

The pathophysiology of the disease has not been entirely unequivocally clarified. In the literature it is stated that OCP is a type 2 immunological reaction (hypersensitivity), characterised by linear deposits of antibodies (immunoglobulins G, A, M and/or immune complement C3) along the basal membrane of the epithelium (43, 7). In a certain subgroup of OCT the autoantibody against $\beta 4$ integrin can be detected (27).

The symptoms are non-specific: long-term reddening of the eye(s), burning, irritation, feeling of a foreign body, lachrymation, photophobia, dry eyes and deterioration of vision (45). The complaints are always long-term, predominantly bilateral (with possible asymmetry of severity), persisting for a number of weeks to years, and gradually worsening (29, 37). In exceptional cases OCP may initially be unilateral, subsequently the other eye becomes affected within 2 years (1).

According to Foster, OCP is classified into 4 stages. The first stage is characterised by subepithelial fibrosis and scarring of the conjunctiva. We look for its symptoms on the tarsal conjunctiva of the lower and upper eyelid (fig. 1). In the second stage there is a softening of the fornices (fig. 2). In the third stage symblepharons are present (fig. 3, 4), and in the final fourth stage ankyloblepharon, in which keratinisation and vascularisation of the cornea takes place (fig. 5, 6). The older classification according to Mondy evaluates the depth of the lower fornix, which is usually around 11 mm. Stage I is softening of the fornix by less than 25%, stage II softening by 25-50%, stage III 50-75% and stage IV by more than 75 % (30).

Diagnosis is determined on the basis of the anamnesis and clinical picture, and is supported with the help of direct and indirect immunofluorescence. In the case of suspicion of OCP a biopsy of the conjunctiva or buccal membrane should be performed and sent for immunohistochemical examination. It is best to perform a biopsy of the conjunctiva from the temporal upper quadrant of the bulbar conjunctiva, where there is the lowest risk of scarring and the upper eyelid accelerates healing. A sample with a size of 2-4 mm is taken, including the basal membrane (BM) of the conjunctiva. By contrast, a biopsy should never be performed from the lower fornix due to the danger of accelerating scarring of the conjunctiva (16). Grau recommends that tissue from the buccal mucosa should be taken at the same time, whether or not the patient has symptoms of its affliction. A positive finding of direct immunofluorescence is presented in fig. 7. Indirect immunofluorescence is performed by taking a sample from the peripheral blood, and the serum is examined for circulating antibodies against BM (anti-desmosomes) (37, 41).

We treat OCP with IS therapy (5, 14, 21, 22, 36, 38). Its se-

lection depends on the activity and stage of progression of the disease, the patient's overall condition, effectiveness of treatment hitherto and the incidence of adverse effects of therapy. Therapy is conducted on a strictly individual basis and is more successful if applied in the early stages of the disease (39).

We can divide complications of OCP into ocular complications and complications of general IS therapy. Frequent ocular complications include dry eye syndrome, filamentary keratitis, limbal cell deficiency, non-healing defect of corneal epithelium, pannus, corneal bullae, corneal ulcers, corneal lysis, perforation of the cornea, endophthalmitis, trichiasis, entropion and lagophthalmos (37).

Serious complications of general therapy include leucopenia, lymphopenia, anaemia, thrombocytopenia, alopecia, haematuria, hepatotoxicity, nephrotoxicity, neuropathy, Cushing's syndrome, osteoporosis, diarrhoea, opportunistic infection and death of the patient.

METHOD

We retrospectively evaluated patients from the Centre for Corneal and Conjunctival Diseases at the Department of Ophthalmology, 1st Faculty of Medicine, Charles University and General University Hospital in Prague.

Our study cohort comprised 51 patients, 21 men and 30 women in whom OCP was diagnosed in the period 1992-2013. The average observation time was 57 months (range 1-248 months).

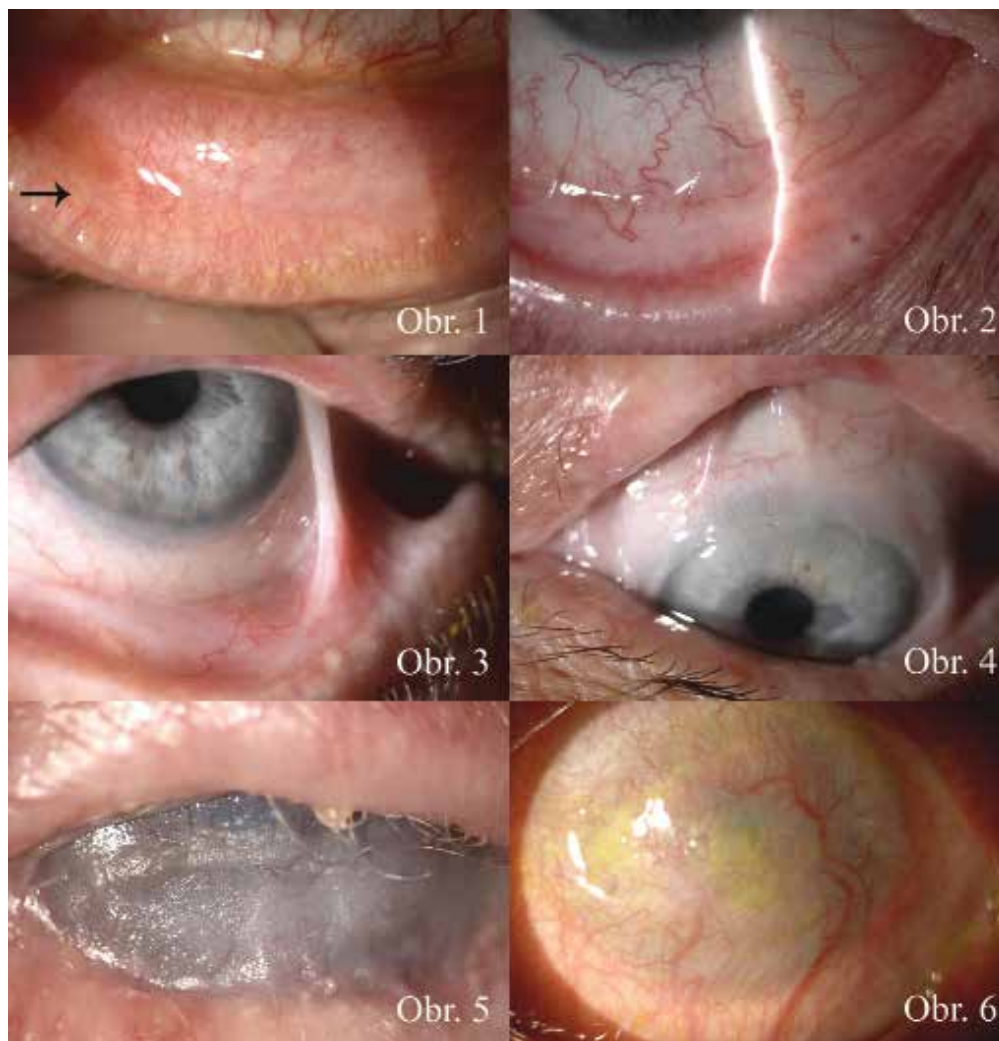In the cohort we evaluated the age upon determination of the diagnosis, baseline central visual acuity (CVA) and final CVA, positivity of direct and indirect immunofluorescence, stage of OCP at the beginning of the disease and at the end of observation, activity of the disease upon arrival, activity of the disease and the number of relapses during treatment and after any applicable discontinuation of therapy.

We also focused on the type of general IS therapy which the patients received and any complications that occurred. In particular we evaluated the effectiveness and adverse effects (AE) of therapy using mycophenolate mofetil (MM).

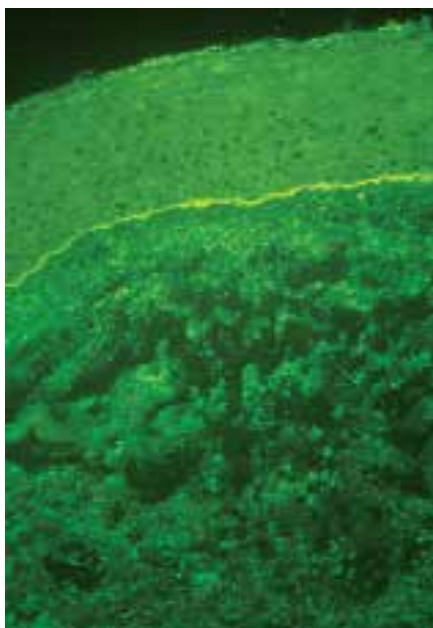
At the same time we observed ocular complications with which the patients came to our centre and which occurred during the observation period within the cohort. We also recorded the operations which the patients had undergone before their arrival at the clinic and the operations which we ourselves indicated.

We also determined whether the patients also suffered from a systemic bullous disorder (MMP).

The diagnosis was determined on the basis of the patients' anamneses and clinical examination on a slit lamp. We evaluated the activity of the disease macroscopically in daylight in all quadrants of the conjunctiva. To confirm the diagnosis a biopsy of the conjunctiva was taken for direct immunofluorescence, and a blood sample was sent for an immunohistochemical examination (anti-desmosomes, indirect immunofluorescence). We examined CVA on Snellen's optotypes. We measured intraocular pressure (IOP) by applanation. We performed photo-documentation on a slit lamp.



Obr. 1-6 OCP stages (classification according to Foster)



Obr. 7 Direct immunofluorescence

RESULTS

Our cohort of 51 patients included a total of 21 men (41%) and 30 women (59%). The age of the patients at the time of determination of the diagnosis was within the range of 29 to 91 years, on average 68.4 years, the median upon determination of the diagnosis was 71 years. We divided the patients into 8 age groups (graph no. 1).

From the graph it is evident that the highest incidence of OCP was in the age group of 70-79 years, in total 20 patients. 7 patients (14 %) died during the observation.

Best CVA at the first examination was 6/6 and worst was light perception, uncertain light projection. In our patients we evaluated stabilisation of CVA or its improvement or deterioration (change by 2 or more rows on Snellen's optotypes). We recorded each eye separately. Stabilisation of CVA was achieved in 76% of eyes, an improvement took place in 5%, whilst we recorded a deterioration of CVA in 19% (graph no. 2).

Out of the total number of 51 patients, a biopsy of the conjunctiva was performed on 42 patients, of whom

we recorded positivity in 20 patients (48 %). Examination for anti-desmosomes was performed on a total of 32 patients, of whom a positive result was recorded in 7 (22 %). We recorded positivity of both examinations in 3 patients out of 28 (11 %), and 24 patients out of 46 (52%) had at least one positive examination. By contrast, negative results in both examinations were found in 12 patients (43 %) out of the 28 on whom the examination were conducted (table 1-3).

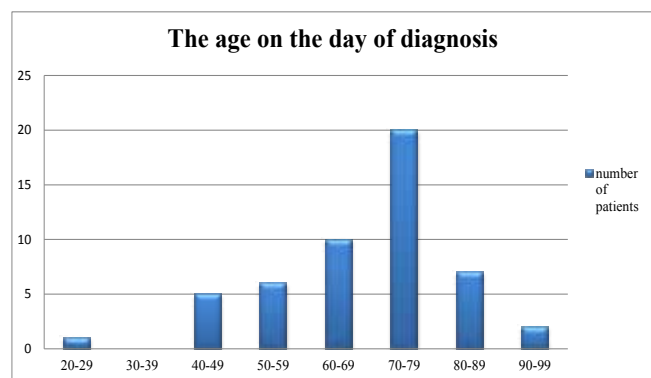
On 5 patients (10%) neither examination was conducted. The reason for this was the already advanced finding of the disease: a 71 year old patient admitted with complications of OCP (corneal ulcer), stage OCP IV in both eyes (OPL), a 72 year old patient with corneal lysis and general MMP had stage IV in the right eye (RE) and III in the left eye (LE), a 75 year old patient with stage III in RE/LE was admitted with perforation of the cornea, a 75 year old patient with stage III in RE/LE without complications observed for 131 months.

All patients in the group had bilateral affliction. 56 eyes (55%) were sent to our outpatient clinic in stage OCP III, 28 eyes (27%) in stage IV. Only 18 eyes (18%) were in stages I or II (table 4).

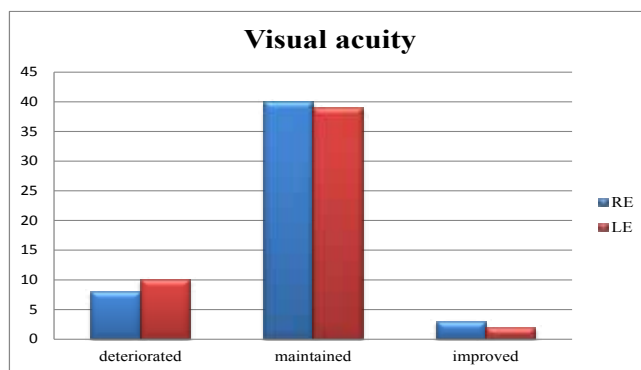
During the observation period there was a progression from stage I in 3 eyes, from stage II in 1 eye and from stage III in 3 eyes. Therefore there was progression to a higher stage of the disease in 7 eyes (6.9%) and 95 eyes (93.1%) remained stable.

The activity of the disease at the beginning of observation was diagnosed in a total of 49 out of 51 patients (96%), see graph no. 3. A 71 year old patient was in remission, but already had an advanced stage of OCP in RE/LE (stage III), an 81 year old patient had active ulceration on the epiglottis upon arrival at the outpatient clinic, stage IV in LE, but a pacific finding on the conjunctiva.

During observation we recorded a relapse of the disease (activity) in 19 patients out of 48 (40%), see graph 4. We did not evaluate a total of 3 patients due to the short observation period: an 89 year old patient admitted with corneal lysis and stage IV OCP in RE/LE and general MMP was observed for 2 months, after which she died, an 86 year old patient with stage II in RE/LE was observed so far for only 2 months, a 72 year old patient



Graph no. 1: Age on day of diagnosis



Graph no. 2: Visual acuity

with general MMP and stage IV in RE and stage III in LE was observed for only one month.

The median of relapses was 2.

We discontinued IS therapy on 16 patients, 4 of whom (25%) experienced a relapse following discontinuation (graph no. 5).

IS therapy was applied on 50 patients. 1 patient was treated only locally with corticosteroid preparations due to the pacific finding without progression. In combination corticosteroids (CS) were most frequently applied on 47 patients, azathioprin (AZA) on 28 patients, cyclophosphamide (CP) on 25 patients, MM on 16 patients, sulphasalazine on 5 patients and dapsone also on 5 patients. The percentage representation of the individual IS drugs can be seen in graph no. 6. On average the patients were administered or alternated 2.5 IS drugs

Table 1-3 Diagnostic investigations results

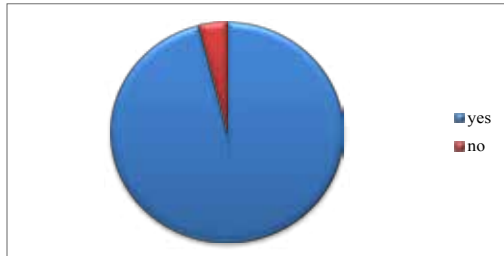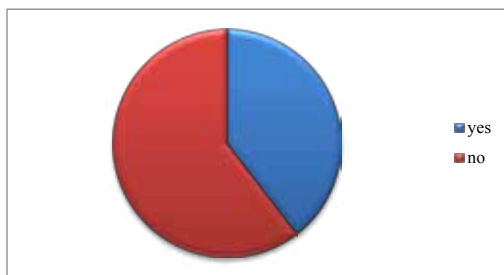
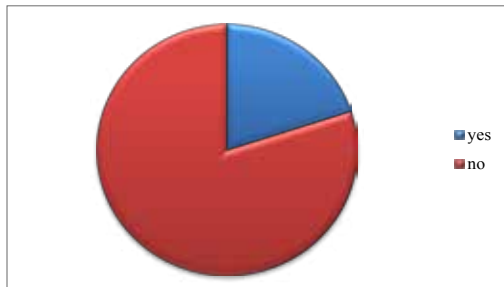
Results according to type of diagnosis - individually	conjunctival biopsy	anti-desmosoms
positive result	20	7
negative result	22	25
not performed	9	19

Results according to type of diagnosis - in total	number of patients	percentage
both results negative	12	43%
both results positive	3	11%
a minimum of one result positive	24	52%
none investigation performed	5	10%

Investigation performed	number of patients	percentage
both investigations	28	55%
only one investigation	18	35%
none investigation	5	10%
minimum of one investigation	46	90%

Tab. 4 Stage of OCP at beginning and end of study

OCP stage	RE beginning	LE beginning	BE %	RE end	LE end	BE %
1	3	3	6	3	0	3
2	7	5	12	5	6	11
3	28	28	55	27	26	52
4	13	15	27	16	19	34
in total	51	51	100	51	51	100

**Graf 3** Activity of OCP**Graf 4** Relaps of OCP**Graf 5** Activity after IS discontinuity

during the course of treatment.

We recorded complications of IS therapy in 24 patients (48%). 3 patients suffered complications with more than one IS preparation.

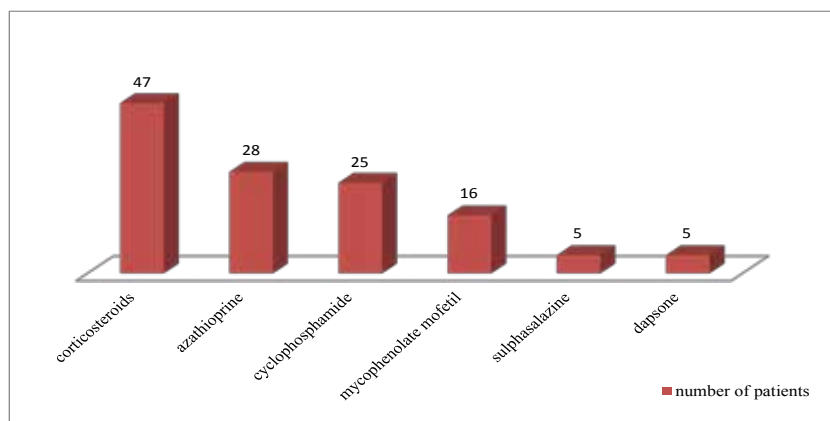
The largest number of adverse effects were suffered by patients after application of CP. These occurred in a total of 14 out of 25 patients on whom it was applied (56%). The most frequent adverse effect was suppression of bone marrow – lymphopenia, leukopenia, thrombocytopenia, see table no. 5. The most serious AE was the death of a 76 year old patient in stage OCP IV from the opportunistic infection *Pneumocystis carinii*, the patient at the same time suffered from gullet spasms and pustules in the hypopharynx.

We determined AE of CS in 5 out of 50 patients (10%). 1 patient had lymphopenia, 2 Cushing's syndrome, 1 osteoporosis and 1 an opportunistic infection, see table no. 6.

In the case of patients using AZA we identified lymphopenia in 2 patients, diarrhoea in 2 patients, elevation of liver tests in 1 patient and anaemia in 1 patient. An 84 year old patient with stage IV OCT in RE/LE died two months after application of AZA. The cause of death was not unequivocally determined. In total AZA was indicated for 28 patients, in whom AE were documented (25%), table no. 7.

AE of MM were found in only 1 patient out of 16 (lymphopenia), table no. 8.

Therapy using MM was commenced on 16 patients, initially in 5/2007 on 10 women and 6 men. The average age of these patients at the time of diagnosis was 73.4

**Graf 6** Immunosuppressive therapy

± 12.2 years in stage OCP II-IV. At the same time 8 patients suffered from MMP – 2 patients had affliction of the skin, 2 the oral mucosa, 1 the epiglottis, 2 affliction of the gullet and 1 multiple affliction of the mucosa. The average observation period was 64 months, the average duration of therapy was 25 months. In 7 patients therapy with MM was the drug of first choice, it was applied on 8 patients due to serious AE of the previous therapy and on 1 patient due to failure of the previous therapy.

Long-term stabilisation and control of the activity of the disease was secured in 11 patients (69 %). 2 patients were in long-term remission and we discontinued therapy with MM after 8 and 15 months, 4 patients remained without activity of the disease but therapy with MM is continuing, 5 patients had episodes of activity upon reduction of the dose. In 5 patients (31%) control of the

disease was not achieved, and as a result therapy was changed to CP or AZA.

We divided ocular complications into complications upon arrival at our outpatient clinic and complications which occurred during treatment. Ocular complications at the first examination were present in 24 patients (47%). In these patients we recorded a total of 34 ocular complications. The most serious included corneal ulcer/lysis in a total of 6 patients, perforation of the cornea in 2 patients and endophthalmitis in 1 patient. The less serious include pannus in 2 patients and corneal bullae in 1 patient, see table no. 9. The most frequent complication was trichiasis, which occurred in 14 patients (27 %).

During treatment we addressed 37 complications in a total of 27 patients (53 %): corneal ulcer/lysis in 7 patients, perforation of the cornea in 5 patients, non-healing defect of the cornea in 2 patients. Less serious complications included infiltration on the cornea in 2 patients, decompensation of IOP in 2 patients and keratinisation in 1 patient. Most frequently we addressed trichiasis, in a total of 18 patients (table no. 10).

Before arrival at our outpatient clinic, 26 patients (51 %) had undergone a total of 48 eye operations: cataract surgery – 17x, cryoepilation or electroepilation of the eyelids – 9x, conjunctival surgery – 4x, surgery for entropion or ectropion – 4x. During our observation we indicated a total of 88 operations on 30 patients (59 %): transplantation of amnion membrane 17x, perforating keratoplasty (PKP) 10x, repositioning of musculo-cutaneous flap (MCF) 21x, cryoepilation or electroepilation of eyelids 14x, plastic surgery of upper eyelids (UE) or tarsorrhaphy 6x – see graph no. 7.

A total of 16 patients (31 %) also suffered from a systemic bullous disorder. 5 patients had only skin affliction until the time of diagnosis of OCP, 10 patients had MMP (i.e. also other affliction of mucosae) and 1 patient had paraneoplastic syndrome.

DISCUSSION

OCP is a bilateral autoimmune sight threatening disease, characterised by progressive scarring of the conjunctiva in combination with several ocular complications. Untreated it can lead to blindness and sometimes even to the death of the patient. Our cohort comprised 51 patients, in whom we diagnosed OCP in the period 1992 – 2013. The results of our observation can be compared in certain parameters with foreign studies.

The largest study was published by Saw et al. (Moorfields Eye Hospital) in 2008 and numbers 115 patients over 11 years (36). In 1996 Elder et al. (Moorfields Eye Hospital, UK) published a study of 66 patients over 3 years of observation (10), Thorne et al. (Wilmer Eye Institute, USA) 94 patients over 22 years (40), Brunner et al. (OMMA Eye Center, Switzerland) 18 patients over 17 years (5), Doycheva et al. (University of Tuebingen, Germany) published data on 10 patients over 4 years of observation (9) and Nottage et al. (Wills Eye Institute, USA) observed 23 patients over 6 years (31).

Table 5–8 Side effects (SE) of IS therapy

SE cyclophosphamide	number of patients
lymphopenia	7
leukopenia	2
lymphopenia+leukopenia	1
thrombocytopenia	1
opportunistic infection, †	1
diarrhoea	1
alopecia	1
in total	14

Table 6.

SE corticosteroids	number of patients
lymphopenia	1
Cushing syndrome	2
osteoporosis	1
opportunistic infection	1
in total	5

Table 7.

SE azathioprine	number of patients
lymphopenia	2
opportunistic infection, †	1
anemia	1
diarrhoea	1
hepatotoxicity	1
severe nausea	1
in total	7

Table 8.

SE MM	number of patients
lymphopenia	1

Table 9 Ocular complications

Referred patients	number of patients
trichiasis	14
pannus	3
corneal neovascularization	1
bullous keratopathy	1
corneal infiltrations	1
corneal ulcer	6
corneal perforation	2
pathological keratinization	2
endophthalmitis	1
decompensated IOP	1
persistent corneal epithelial defect	2
in total	34

Table 10 Ocular complications

During monitoring study	number of patients
trichiasis	18
persistent corneal epithelial defect	2
corneal infiltration	2
corneal ulcer	7
corneal perforation	5
pathological keratinization	1
decompensated IOP	2
in total	37

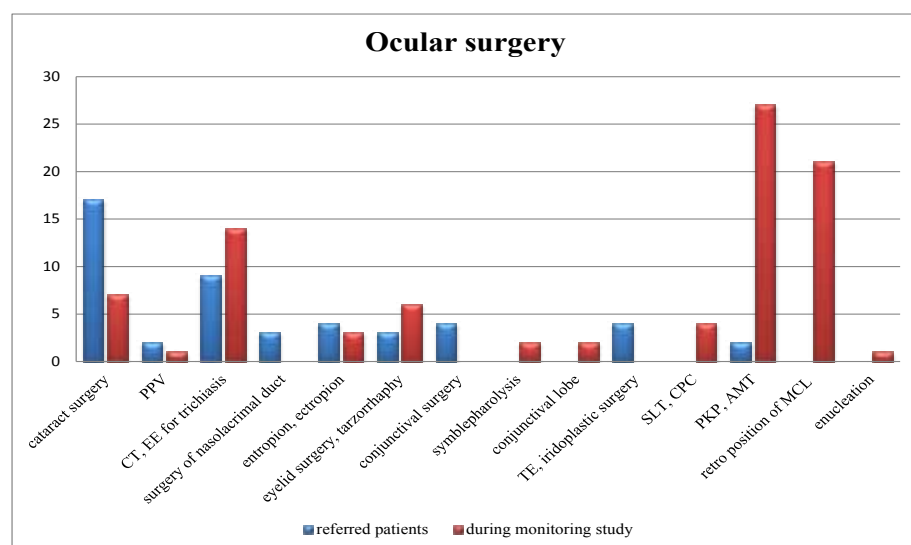
The average age of patients at the time of diagnosis is within the region of 65 years - Saw 66.9 (36), Elder 67 years (10), Doycheva 70 years and the median 75 let (9), Brunner 64 years (5), Thorne 69 years (40). In our cohort the average

age of the patients was 68.4 let, median 71 years, which is in accordance with other publications.

The ratio of women to men differs only negligibly in the various different studies. 1.25:1 (36, 5), 1:1 (9), 1.3:1 (10), 1.1:1 (40). In our cohort the ratio was 1.4:1.

Evaluation of CVA took place differently in the different studies, Thorn et al. state only average baseline CVA in all afflicted eyes (20/30) and prevalence of CVA worse than 20/200 in 16.6% of eyes (40), Elder et al. recorded CVA only at the beginning of the disease (10), Brunner et al. do not state CVA (5). Saw et al. divided CVA into 4 categories. At the time of diagnosis 67% of eyes were within the category of CVA better than 6/18, at the end of observation 48% of eyes were within this category, at the beginning of observation 11% of eyes were within the category of CVA worse than 3/60 and at the end of observation this had risen to 26% of eyes (36). Doycheva et al. compared the change of CVA similarly as in our study, they state an improvement of vision in 11% of eyes, stabilisation in 47% of eyes and deterioration in 42% of eyes. They evaluated change as an improvement or deterioration by 3 or more rows of Snellen's optotypes. In our cohort we succeeded in stabilising CVA in 76% of eyes, an improvement was achieved in 5% of eyes and we recorded a deterioration of CVA in only 19% of eyes (change by 2 or more rows of Snellen's optotypes). Upon arrival CVA was 6/60 or worse in 30% of eyes, at the end of observation in 38% of eyes. The reason for the deterioration of CVA even despite IS therapy is the fact that OCP is only diagnosed in the advanced stages, in which serious ocular complications are present. The most common cause of deterioration of vision is the onset of corneal vascularisation, corneal ulcer/lysis, perforation of the cornea and keratinisation of the cornea. However, CVA is not the conclusive standard for evaluation of the effectiveness of treatment, more significant is remission of the ocular finding and avoidance of relapses.

Positivity of direct immunofluorescence (DIF) is stated in almost all studies. Saw et al. conducted a biopsy on 62 of 115 patients. 49 of these underwent a biopsy of the conjunctiva (positive in 61%) and the remaining 14 patients a



PPV (pars plana vitrectomy), CT (cryotherapy), EE (electroepilation), TE (trabeculectomy), SLT (selective laser trabeculoplasty), CFK (cyklofotokoagulace), CPC (cyclophotocoagulation), PKP (penetrating keratoplasty), AMT (amniotic membrane transplantation), MCF (muscular cutaneous flap)

Graf 7 Ocular surgery

biopsy of the buccal mucosa (positive in 78.6%) (36). Thorne et al. only included patients who had positive DIF in their study (40). In a study conducted by Elder et al. (10), a biopsy of the conjunctiva was taken from 86% of patients, with a positive finding in 54% of these. Brunner states an even higher percentage of positive conjunctival biopsy – 72.7%, conducted on 61.1% of patients (5). By contrast, Nottage et al. state a lower percentage – 47.8% (31), which is in accordance with our results. We recorded positivity in 20 patients (48%) out of 46. Biopsy of the buccal mucosa was not conducted on any of our patients, and we did not conduct repeated biopsies of the conjunctiva. According to Grau et al. (16), the reason for the lower percentage of positive DIF of the conjunctiva in comparison with the buccal mucosa is the fact that the conjunctiva is more brittle than the other mucosae. As a result they recommend that a sample is always taken simultaneously from the conjunctiva and the buccal mucosa, even in the case that this is not affected.

The stage of the disease has been evaluated in a number of studies according to Foster, in others according to Mondino. With regard to the fact that we assessed the degree of affliction according to Foster, I will present only studies which used the same evaluation. In the study conducted by Doycheva et al., 63% of eyes were registered in stage III and 11% of eyes in stage IV. Progression of scarring was described in 47% of eyes, but progression to a higher stage of OCP was recorded in only 11% of eyes (9). Saw et al. had 81% of eyes in stage III in their study, and 2% in stage IV. Progression to a higher stage occurred in 8% of patients (36), progression of scarring in 53%. Thorne et al. state that 74.5% of eyes were in stage III (40). Elder et al. (10) recorded 61% of eyes in stage III and 14% of eyes in stage IV. Progression of scarring occurred in 35% of eyes, progression to a higher stage of OCP in 4%. Brunner et al. (5) diagnosed stage III in 58% of eyes and stage IV in 0%. Progression of scarring occurred in 33% of eyes and they do not state progression to a higher stage of OCP. In our cohort 55% of eyes were sent in stage III, 27% in stage IV, which is a higher incidence of stage IV than in the compared studies. During observation we recorded progression to a higher stage of OCP in a total of 7% of eyes, which can be considered a satisfactory result taking into account the other studies. We did not assess progression of scarring.

Activity of the disease at the beginning of observation was evaluated by Thorne et al. (40) on the basis of the conjunctival finding (reddening of the conjunctiva). They recorded 66% positivity. Relapse of the disease during observation was recorded in 8.5% of patients (8/96). In our cohort activity was evaluated by the same method, and was present at the beginning of observation in a total of 96% of patients. During observation we recorded a relapse of the disease (activity) in 40% of patients (19/48). Saw et al. (36) published a relapse in 20% of patients. Other publications rather evaluated the number of months until remission of the disease was achieved. The median of relapse was 2. We did not evaluate the average value here, since one patient experienced 20 relapses and this would have distorted the result. After discontinuation of IS therapy in 16 patients, in

25% (4 patients) we again recorded activity of the disease (relapse). This was not evaluated in the other studies.

The basis of treatment of OCP is IS therapy. This was applied to 74% of patients in the study by Elder et al. (10). 33% of patients used sulphapyridine, 30% CS, 17% CP, dapsone 15%, 12% sulphamethoxypyridazine and 5% AZA. The study was conducted in 1996, and as a result did not include any patients treated with MM. In 2006 a study was published by Saw et al. (36) from the same centre, in which 12% of all episodes were treated with MM, although dapsone was applied most frequently, in 30% of cases, AZA in 21%, CP in 19% and sulphapyridine in 14% of episodes. The most effective were CP and MM, the least effective AZA and sulphapyridine. IS therapy was used on a total of 75% of patients. At our clinic general therapy was applied on 98% of patients. A total of 29 episodes were treated by monotherapy. The majority of patients were administered combined IS therapy during observation, partially due to the insufficient effectiveness of monotherapy, relapse of the disease or adverse effects of therapy. 47 patients were administered CS, more than half CZA (28 patients) and CP (25 patients), MM was used by 16 patients, sulphasalazine by 5 patients and dapsone also by 5 patients. Therefore, on average each patient received 2.5 IS drugs.

The effectiveness of treatment was evaluated in our cohort of patients receiving MM. The latest studies demonstrate that this IS therapy is highly effective. In contrast with CP it manifests far less AE (36, 38, 9). A total of 16 patients were treated with MM, 8 of whom also suffered from MMP. The average observation period was 64 months, the duration of therapy 25 months. In 7 patients treatment by MM was the drug of first choice, in 8 patients it was applied due to serious AE of previous therapy and in 1 patient due to failure of the previous therapy. In 11 patients (69%) we succeeded in ensuring long-term control of the activity of the disease. 2 patients (12.5%) were in long-term remission and we discontinued MM, 4 patients (33%) remained without activity of the disease but therapy with MM is continuing, 5 patients (31%) had episodes of activity upon reduction of the dose. Doycheva et al. (9) achieved complete remission in 58% of patients using MM, Saw et al. in 59% (36) of patients, Nottage in 82% (31). Our results in controlling the activity of OCP are highly encouraging. In 5 patients using MM (31%) control of the disease was not achieved, as a result of which therapy was changed to CP and AZA, which is a markedly lower percentage in comparison with the above-stated studies.

We determined an adverse effect of treatment in only 1 patient (6%), namely lymphopenia. In general MM manifests a very low risk of AE. In the study by Saw et al. AE was stated at 15% (36), Nottage 21% (31). Doycheva et al. (9) recorded AE in 7 out of 10 patients, but therapy with MM was discontinued for only 1 patient (10%).

Complications of general therapy with CP were evaluated by Saw et al., and registered in as many as 31% of cases (36). The most feared AE of CP (bladder tumour) was determined by Thorne et al. (40) in 1 patient, in another 7 they recorded other malignant tumours (basal cell carcinoma, squamous

carcinoma, leukaemia, breast tumour). They treated a total of 70 patients with CP and also encountered the infection *Pneumocystis carinii*. The other studies did not evaluate AE. In our cohort we addressed complications of IS therapy in 24 patients out of 50 (48%). 3 patients suffered AE with more than one IS preparation. We also recorded the most AE in the case of CP (14 out of 25 patients – 56%), most frequently suppression of bone marrow, and 1 patient even died as a result of the opportunistic infection *Pneumocystis carinii*. AE of CS occurred in 10% of patients and somewhat more in the case of AZA, at 25%. Our conclusions are thus in accordance with the above studies, in that the least AE occur upon use of MM and the most with CP.

The most severe ocular complications were stated in both studies by Elder (12, 10), who encountered 2 perforations of the cornea out of 10 patients who had not responded to previous IS therapy and as a result were treated with high doses of CS and CP. In the second study, in which all patients were included, they recorded perforation in only one out of 66 (1.5%). We also encountered perforation of the cornea, in a total of 7 patients (14% of patients), in 2 of whom this was present at the beginning of observation and in 5 during treatment. Corneal ulceration was recorded by Doycheva et al. (9) in 20% of patients, in our cohort in 12 %. A non-healing epithelial defect is stated by Elder et al. (10) in 18% of patients during therapy, we addressed this in 4% of patients. Less serious ocular complications include trichiasis, which was recorded by Thorne et al. (40) at the first examination in as many as 38.5% of eyes, and scarring of the cornea in 13.4%, which is comparable with our cohort, in which trichiasis was suffered by 27% of patients upon arrival at our clinic. In a further study (9) trichiasis was present in as many as 50% of patients.

In their study cohort Doycheva et al. (9) stated that 53% of patients had undergone eye surgery before arriving at

their clinic, which is in accordance with our own records – 51% of patients. During treatment they then indicated 58% of patients for surgery, and we referred almost exactly the same amount, 59% of patients. However, our results differ in the type of operations that were performed. Doycheva et al. most often indicated filtering surgery due to decompensated glaucoma, reconstruction of the fornix and eyelid operations. By contrast, we indicated transplantation of an amnion membrane (17x) or PKP (10x), retropositioning of MCF (21x), cryoepilation or electroepilation of eyelids (14x) and plastic surgery of the upper eyelids or tarsorrhaphy (6x). Altogether our 51 patients underwent 88 procedures.

Presence of MMP has been recorded in several studies and ranges from 44.4 % (5) and 50 % (10, 36), up to 70 % (12). In our cohort MMP was diagnosed in only 31% of patients. 62% of these also had other afflictions of the mucosae, 31% had ocular and skin afflictions and 6% paraneoplastic syndrome.

CONCLUSION

Ocular cicatricial pemphigoid is a rare, chronic and serious pathology, the diagnosis of which is determined on the basis of anamnesis, clinical picture and supported by a positive results of a conjunctival biopsy and/or anti-desmosomes. Systemic immunosuppressive therapy can effectively suppress the activity of the disease and prevent its progression, ideally commenced in the early stages of OCP. However, sometimes even despite aggressive IS therapy there may be progression of scarring and ocular complications, which can lead to blindness.

Thanks:

For relevant comments and correction I express my deepest thanks to Dr. Michaela Brichová, Dr. Pavel Diblík and Dr. Jarmila Heissigerová

LITERATURE

- Ahmed M, Zein G, Khawaja F. et al.:** Ocular cicatricial pemphigoid: pathogenesis, diagnosis and treatment. *Prog Retin Eye Res* 2004; 23: 579–92.
- Ahmend AR, Foster SC, Zaltas MM.:** Association of DQw7 (HLA-DQβ1*0301) with ocular cicatricial pemphigoid, *Proc Natl Acad Sci U S A* 1991; 88: 11579–82.
- Bernard P, Vaillant L, Labeille B, et al.:** Incidence and distribution of subepidermal autoimmune bullous skin diseases in three French regions. *Bullous Disease French Study group. Arch Dermatol* 1995; 131; 48–52.
- Bertram F, Brocker EB, Zillikens D, et al.:** Prospective analysis of the incidence of autoimmune bullous disorders in Lower Franconia, Germany. *J Dtsch Dermatol Ges*, 2009; 7: 434–40.
- Brunner M, Lacoste KJ, Bernauer W.:** Control of ocular disease in mucous membrane pemphigoid. *Klin Monbl Augenheilkd*, 2014 Apr; 231(4): 331–4.
- Canizares MJ, Smith DI, Conners MS at al.:** Successful treatment of mucous membrane pemphigoid with etanercept in 3 patients. *Arch Dermatol*, 2006 Nov; 142(11): 1457–61.
- DaCosta J.:** Ocular cicatricial pemphigoid masquerading as chronic conjunctivitis: a case report. *Clin Ophthalmol*, 2012; 6: 2093–5.
- Daniel E, Thorne JE, Newcomb CW et al.:** Mycophenolate mofetil for ocular inflammation. *Am J Ophthalmol*, 2010 Mar; 149(3): 423–32.e1–2.
- Doycheva D, Deuter C, Blumenstock G, at al.:** Long-term results of therapy with mycophenolate mofetil in ocular mucous membrane pemphigoid. *Ocul Immunol Inflamm*, 2011 Dec; 19(6): 431–8.
- Elder MJ, Bernauer W, Leonard J, Dart JK.:** Progression of disease in ocular pemphigoid. *Br J Ophthalmol*, 1996; 80: 292–6.
- Elder MJ, Dart JK, Collin R.:** Inferior retractor plication surgery for lower lid entropion with trichiasis in ocular cicatricial pemphigoid. *Br J Ophthalmol*, 1995 Nov; 79(11): 1003–6.
- Elder MJ, Lightman S, Dart JK.:** Role of cyclophosphamide and high dose steroid in ocular cicatricial pemphigoid. *Br J Ophthalmol*, 1995 Mar; 79(3): 264–6.
- Foster CD.:** Cicatricial pemphigoid. In: *Cornea: Fundamentals, Diagnosis, and Management.*, ed 3 In" Krachmer JH, Mannis MJ, Holland EJ, eds Vol. 1. Philadelphia, Mosby Elsevier, 2011; p. 591–9.
- Foster CS, Chang PY, Ahmed AR:** Combination of rituximab and intravenous immunoglobulin for recalcitrant ocular ci-

- catricular pemphigoid: a preliminary report. *Ophthalmology*, 2010 May; 117(5): 861–9.
15. **Gangaputra S, Newcomb CW, Liesegang TL et al.:** Methotrexate for ocular inflammatory diseases. *Ophthalmology*, 2009 Nov; 116(11): 2188–98.e1.
 16. **Grau AE1, Setterfield J, Saw VP.:** How to do conjunctival and buccal biopsies to investigate cicatrising conjunctivitis: improving the diagnosis of ocular mucous membrane pemphigoid. *Br J Ophthalmol*, 2013 Apr; 97(4): 530–1.
 17. **Heffernan MP, Bentley DD.:** Successful treatment of mucous membrane pemphigoid with infliximab. *Arch Dermatol*, 2006 Oct; 142(10): 1268–70.
 18. **Hervás Ontiveros, Salom, España Gregori.:** Methotrexate as a treatment in ocular cicatricial moderate pemphigoid. *Arch Soc Esp Oftalmol*, 2013 Dec 18. pii: S0365–6691(13): 00376–6.
 19. **Hollick EJ1, Watson SL, Dart JK et al.:** Legeais BioKpro III keratoprosthesis implantation: long term results in seven patients. *Br J Ophthalmol*, 2006 Sep; 90(9): 1146–51.
 20. **Chan LS, Ahmed AR, Anhalt GJ, et al.:** The first international consensus on mucous membrane pemphigoid: definition, diagnostic criteria, pathogenic factors, medical treatment and prognostic indicators. *Arch Dermatol*, 2002; 138: 370–9.
 21. **Chan LS.:** Ocular and oral mucous membrane pemphigoid (cicatricial pemphigoid). *Clin Dermatol*, 2012 Jan-Feb; 30(1): 34–7.
 22. **Chang JH, McCluskey PJ.:** Ocular cicatricial pemphigoid: manifestations and management. *Curr Allergy Asthma Rep*, 2005 Jul; 5(4): 333–8.
 23. **Iakymenko S.:** Forty-five years of keratoprosthesis study and application at the Filatov Institute: a retrospective analysis of 1 060 cases. *Int J Ophthalmol*, 2013 Jun 18; 6(3): 375–80.
 24. **Kanski, J. J.:** „Clinical Ophthalmology: A Systematic Approach“, Butterworth-Heinemann, 2007, s. 235–237, ISBN 9780702040931.
 25. **Kharfi M, Khaled A, Anane R, et al.:** Early onset childhood cicatricial pemphigoid: case report and review of the literature. *Paediatr Dermatol*, 2010; 27: 119–24.
 26. **Kirzhner M1, Jakobiec FA.:** Ocular cicatricial pemphigoid: a review of clinical features, immunopathology, differential diagnosis, and current management. *Semin Ophthalmol*, 2011 Jul-Sep; 26(4–5): 270–7.
 27. **Letko E, Bhol K, Foster CS, Ahmed AR.:** Influence of intravenous immunoglobulin therapy on serum levels of anti- $\beta 4$ antibodies in ocular cicatricial pemphigoid. *Curr Eye Res*, 2000; 21: 646–54.
 28. **Messmer EM1, Hintschich CR, Partsch K at al.:** Ocular cicatricial pemphigoid. Retrospective analysis of risk factors and complications. *Ophthalmologie*, 2000 Feb; 97(2): 113–20.
 29. **Miserocchi E1, Baltatzis S, Roque MR.:** The effect of treatment and its related side effects in patients with severe ocular cicatricial pemphigoid. *Ophthalmology*. 2002 Jan; 109(1): 111–8.
 30. **Mondino BJ, Brown SI.:** Ocular cicatricial pemphigoid. *Ophthalmology*, 1981 Feb; 88(2): 95–100.
 31. **Nottage JM1, Hammersmith KM, Murchison AP, et al.:** Treatment of mucous membrane pemphigoid with mycophenolate mofetil. *Cornea*, 2013 Jun; 32(6): 810–5.
 32. **Pasadhika S, Kempen JH, Newcomb CW et al.:** Azathioprine for ocular inflammatory diseases. *Am J Ophthalmol*, 2009 Oct; 148(4): 500–509.e2.
 33. **Pujari SS, Kempen JH, Newcomb CW et al.:** Cyclophosphamide for ocular inflammatory diseases. *Ophthalmology*, 2010 Feb; 117(2): 356–65.
 34. **Radford CF1, Rauz S, Williams GP et al.:** Incidence, presenting features, and diagnosis of cicatrising conjunctivitis in the United Kingdom. *Eye (Lond)*, 2012 Sep; 26(9): 1199–208.
 35. **Risser J1, Lewis K, Weinstock MA.:** Mortality of bullous skin disorders from 1979 through 2002 in the United States. *Arch Dermatol*, 2009 Sep; 145(9): 1005–8.
 36. **Saw VP, Dart JK, Rauz S, et al.:** Immunosuppressive therapy for ocular mucous membrane pemphigoid strategies and outcomes. *Ophthalmology*, 2008; 115: 253–261.
 37. **Saw VP, Dart JK.:** Ocular mucous membrane pemphigoid: diagnosis and management strategies. *Ocul Surf*, 2008 Jul; 6(3): 128–42.
 38. **Sobolewska B, Deuter C, Zierhut M.:** Current medical treatment of ocular mucous membrane pemphigoid. *Ocul Surf*, 2013 Oct; 11(4): 259–66.
 39. **Srikumaran D, Akpek EK.:** Mucous membrane pemphigoid: recent advances. *Curr Opin Ophthalmol*, 2012 Nov; 23(6): 523–7.
 40. **Thorne JE, Woreta FA, Jabs DA et al.:** Treatment of ocular mucous membrane pemphigoid with immunosuppressive drug therapy. *Ophthalmology*, 2008 Dec; 115(12): 2146–2152.
 41. **Thorne JE1, Anhalt GJ, Jabs DA.:** Mucous membrane pemphigoid and pseudopemphigoid. *Ophthalmology*, 2004 Jan; 111(1): 45–52.
 42. **Trimarchi M1, Bellini C, Fabiano B, et al.:** Multiple mucosal involvement in cicatricial pemphigoid. *Acta Otorhinolaryngol Ital*, 2009 Aug; 29(4): 222–5.
 43. **Tyagi S, Bhol K, Natarajan K at al.:** Ocular cicatricial pemphigoid antigen: partial sequence and biochemical characterization. *Proc Natl Acad Sci U S A*, 1996 Dec 10; 93(25): 14714–9.
 44. **Williams GP, Radford C, Nightingale P, et al.:** Evaluation of early and late presentation of patients with ocular mucous membrane pemphigoid to two major tertiary referral hospitals in the United Kingdom. *Eye*, 2011; 25: 1207–18.
 45. **Xu HH1, Werth VP, Parisi E, Sollecito TP.:** Mucous membrane pemphigoid. *Dent Clin North Am*, 2013 Oct; 57(4): 611–30.