

Significant Anti-tumor Effectiveness of Imatinib in C-kit Negative Gastrointestinal Stromal Tumor – Case Report

Významná protinádorová účinnost imatinibu u c-kit negativního gastrointestinálního stromálního tumoru – kazuistika

Kocáková I.¹, Kocák I.¹, Špelda S.¹, Fabian P.², Jurečková A.¹, Vyzula R.¹

¹ Department of Comprehensive Cancer Care, Masaryk Memorial Cancer Institute, Masaryk University Faculty of Medicine, Brno, Czech Republic

² Department of Oncological Pathology, Masaryk Memorial Cancer Institute, Brno, Czech Republic

Summary

Inoperable c-kit negative gastrointestinal stromal tumor (GIST) is commonly considered to be highly resistant to systemic therapy. We present a case of a woman with an abdominal sarcoma-like tumor diagnosed at the age of 26. The patient underwent several surgical procedures and courses of cytostatic therapy without any substantial effect. Later, the tumor was reclassified as c-kit negative GIST harbouring the mutation in exon 12 of *PDGFRA* gene. Hence, the therapy with imatinib mesylate was initiated, resulting in partial remission of metastatic lesions and further stabilization of the disease for five years to date. We therefore consider imatinib mesylate an appropriate therapy for c-kit negative GIST bearing *PDGFRA* mutations.

Key words

gastrointestinal stromal tumors – c-kit receptor – *PDGF* alpha receptor – imatinib mesylate

Souhrn

Inoperabilní c-kit negativní gastrointestinální stromální tumor (GIST) je považován za onemocnění rezistentní ke konvenční cytostatické systémové léčbě. Prezентujeme případ ženy, u které byl ve věku 26 let diagnostikován v dutině břišní maligní tumor charakteru sarkomu. Pacientka prodělala několik chirurgických zákroků a aplikací chemoterapie, nicméně vše bez efektu. Později byl tumor reklasifikován jako c-kit negativní GIST a byla u něj prokázána mutace v exonu 12 genu pro *PDGFRA*. Na základě tohoto nálezu byla zahájena cílená léčba imatinib mesylátem, která vedla k parciální remisi nádoru, dle CT vyšetření. Uvedenou léčbou bylo do dnešní doby dosaženo již pět let trvající stabilizace nemoci. Imatinib mesylát je použitelný jako cílená léčba i v případě c-kit negativního GIST, nesoucího mutaci v genu *PDGFRA*.

Klíčová slova

gastrointestinální stromální tumory – c-kit receptor – *PDGF* alfa receptor – imatinib mesylát

This study was supported by scientific program of the Czech Ministry of Health – DRO (MMCI, 00209805).

Práce byla podpořena výzkumným záměrem MZ ČR – RVO (MOÚ, 00209805).

The authors declare they have no potential conflicts of interest concerning drugs, products, or services used in the study.

Autoři deklarují, že v souvislosti s předmětem studie nemají žádné komerční zájmy.

The Editorial Board declares that the manuscript met the ICMJE "uniform requirements" for biomedical papers.

Redakční rada potvrzuje, že rukopis práce splnil ICMJE kritéria pro publikace zasílané do biomedicínských časopisů.



MUDr. Ivo Kocák, Ph.D.

Department of Comprehensive Cancer Care
Masaryk Memorial Cancer Institute
Zluty kopec 7
656 53 Brno
Czech Republic
e-mail: kocak@mou.cz

Submitted/Obrženo: 24. 10. 2013

Accepted/Přijato: 2. 11. 2013

Introduction

Gastrointestinal stromal tumors (GISTs) represent a group of rare mesenchymal tumors characterized by strong expression of tyrosin kinase receptor KIT (CD 117), as the most important immunohistochemical marker of these tumors [1]. Approximately 5–10% of GISTs do not stain for c-kit membrane protein; this often correlates with a mutation of *PDGFRA* gene [2,3], which encodes type III tyrosin kinase receptor. As the name implies, GISTs are most often localized in the stomach (40–70%) and in the small intestine (20–40%). The colon, oesophagus and rectum are less frequently involved. "EGIST" stands for an extra-gastrointestinal stromal tumor found in mesentery, omentum or retroperitoneum. EGISTs are occasionally found in pancreas, gallbladder and vagina. GISTs metastasize predominantly to the liver, soft abdominal tissues (omentum, peritoneum, retroperitoneum) and less frequently to pelvic and abdominal lymph nodes.

The treatment of choice for a locally advanced, inoperable or metastatic disease is imatinib mesylate (Glivec®) [4]. It has been used in the Masaryk Memorial Cancer Institute since September 2003.

According to Summary of Product Characteristics (SmPC) imatinib is indicated for treatment of patients with KIT-positive (CD 117) inoperable and/or metastatic GIST, as well as for adjuvant treatment of adult patients with a significant risk of recurrence after resection of KIT (CD117)-positive GIST. Patients with low or very low-risk of recurrence should not receive this treatment.

Case report

We report a case of a young female, who was referred to the Masaryk Memorial Cancer Institute for consultation in March 2008 with a large tumor infiltration of the liver, involving the retroperitoneum and perigastric area in addition to multiple abnormal infiltrates on intestinal loops in the left hypochondrium. Five surgical revisions for recurrent sarcoma of abdominal cavity and several lines of palliative chemotherapy had preceded the visit in our institute.

The first symptoms occurred when the patient was 26 years old in the year 2001. Due to an acute abdominal pain mimicking with appendicitis, there was a laparotomy performed in October 2001 extramurally, involving a partial stomach resection and extirpation of a pathological infiltrate of the omentum measuring 160 × 130 × 90 mm. Histological evaluation in concordance with the second reading diagnosed a low-grade hemangiosarcoma M 9120/31. Subsequently, three series of adjuvant chemotherapy (combination of doxorubicin, ifosfamide and mesna) followed. The therapy was completed in January 2002.

The first relapse of the disease occurred in October 2003. Multiple focuses up to 40 mm in diameter were extirpated from omentum and peroperative suture of a ruptured right-sided ovarian cyst was performed; histological finding was re-classified as myofibrosarcoma G I, c-kit negative. The surgery was "secured" by intraperitoneal administration of cisplatin.

The second recurrence in the abdominal cavity occurred two years later – in May 2005. Surgical revision with a resection of tumor masses was indicated (without any record about the size of the tumor) and intraperitoneal administration of cisplatin followed. Histologically, recurrence of epitheloid angiosarcoma of abdominal cavity M 9120/31 was described again. The patient received nine cycles of chemotherapy – paclitaxel once every three weeks. The treatment was completed on 24 February 2006.

The third recurrence of disease was detected eight months later in October 2006 by a CT scan, which revealed an abnormal finding in the retroperitoneum. Extirpation of abnormal retroperitoneal lymph nodes was performed on 21 November 2006. Histologically, the tumor was concluded to be an angiosarcoma M 9120/3, G I, KI67 10%, c-kit negative. Temporarily, COX II inhibitor + vitamin D were administered in an attempt to influence the anti-angiogenic spread, however, the therapy was soon withdrawn because of palpitations.

The fourth relapse of disease occurred within a year. In October 2007 a CT scan

showed a massive hepatic mass and further dissemination in the abdominal and pelvic cavities. The fifth operation was performed. The patient underwent right-sided adnexectomy, extirpation of recurrent 100 mm tumor in lower pelvis. The lesion in the liver was classified as inoperable. Histologically, a definitive diagnosis of a low-grade c-kit negative GIST was established. As for the staging, the CT scan showed a large necrotic infiltration of the liver, retroperitoneum and perigastric area. The liver mass was approximately 16 cm in diameter, another lesion involved the greater curvature of the stomach occupying the left subphrenic area along with retroperitoneal lymphadenopathy up to 2 cm. Another suspicious infiltrate of intestinal loops had been shown in the left hypochondrium and pelvis (Fig. 1, 2). A chest radiogram did not prove any lung involvement.

A PET scan did not detect any focuses with higher glucose metabolism that would indicate the presence of viable tumorous tissue.

The second histological opinion and molecular analysis of mutation in *KIT* and *PDGFR* genes were requested.

Microscopic finding

The biopsy specimen of the primary tumor and all recurrences displayed similar morphological pattern of a solid, monomorphic neoplasm comprising predominantly epitheloid cells with eosinophilic vacuolized cytoplasm and distinct cell membranes visible occasionally. Nuclei were uniform; hyperchromasia and visualization of nucleoli have not been detected. There was a rich capillary network with occasional foci of hemorrhage. Necrosis was not present in any of the specimens. Primary tumor invaded muscle tissue of the stomach and fat tissue in omentum, as did the recurrent tumor cells. Serosal invasion could not be clearly assessed. Surgical margins have not been specified. The maximum mitotic activity was 2mit/50HPF. Tumor cells stained for vimentin diffusively. Focally, the reaction for CD34 (20% of cells), SMA and MSA (15% of cells) was positive, whereas the other markers (desmin, S-100, CKAE, EMA, CD99,

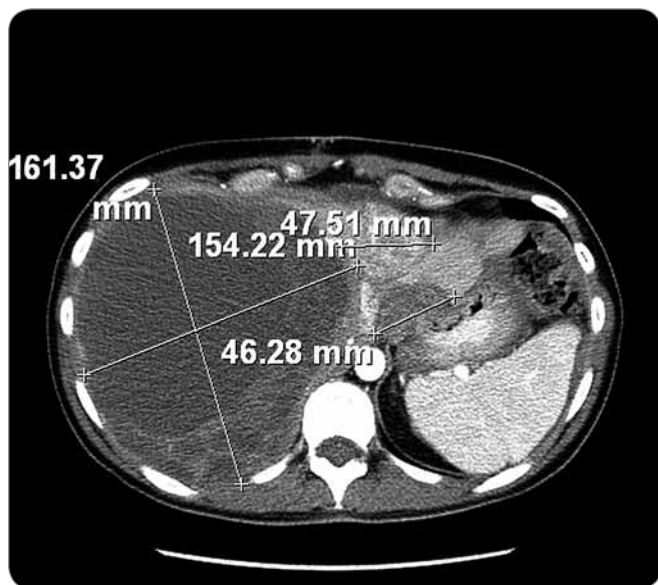


Fig. 1. Large tumor of the liver measuring 161 × 154 mm, retroperitoneum and perigastric area occupied by a necrotic tumor, prior to initiation of treatment; March 2008.

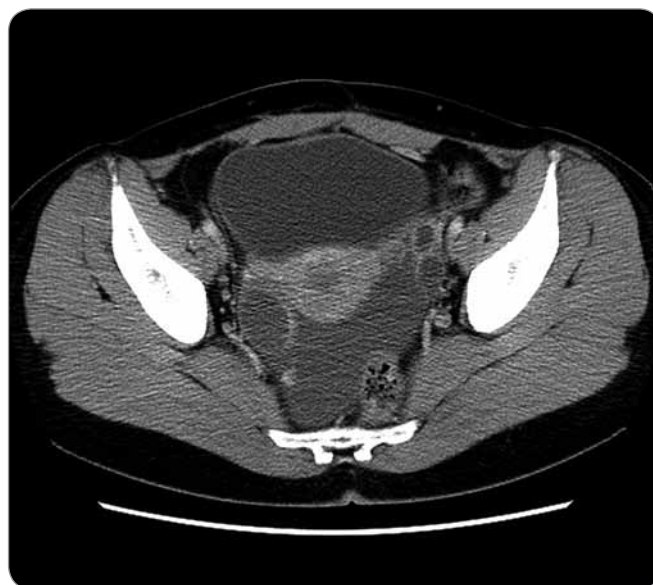

Fig. 2. Large tumor mass in the pelvis prior to initiation of treatment; March 2008.

CK8/18, CD31) were negative. Similarly, immunohistochemistry for C-kit was negative.

Conclusion

The second histological evaluation was consistent with the diagnosis of a recurrent c-kit negative gastrointestinal stromal tumor. With respect to the size of the primary lesion (160 mm), in spite of its low mitotic activity (2mit/50HPF), the tumor was categorized into a group with high-risk of aggressive behavior. Additionally, mutation in exon 12 of a *PDGFRA* gene was detected at a specialized clinic by single-step PCR and subsequent direct sequencing. No further mutations were detected in the other examined exons.

The Karnofsky performance status of the patient with recurrent c-kit negative GIST was 80%. She reported continuous abdominal pain of variable intensity irradiating to the back, and progressively to the right shoulder. The pain worsened at night and recumbency, requiring analgesic therapy. Despite the extensive organ involvement, laboratory parameters were within reference range. Based on the histological nature of the disease and the *PDGFR* mutation, the patient was commenced on imatinib 400 mg/day, despite the c-kit

negative status (see recommendations in SmPC) [5]. During the treatment, no abnormalities in laboratory parameters occurred and abdominal pain resolved within two weeks after the therapy. Actually, imatinib was proven effective and led to significant reduction of tumor in all the documented areas, as shown on the figures below.

Control CT scan

After two months of therapy, a considerable regression of cystoid liver lesion was observed. Moreover, regression of hypodense masses adjacent to the stomach and occupying the left hypochondrium was seen as well. A residual tumor was detected at the lesser curvature of stomach behind the diaphragm. Retroperitoneal lymph nodes remained stable. There were unchanging cystic masses in the left ovary observed.

The patient has been checked every three months during the treatment. Gradually a complete regression of the tumor was seen on CT examinations (the last one in March 2013). The remaining cystoid mass in the liver and ovarian cyst-like lesions are considered necrotic metastases (Fig. 3, 4).

To prove the assumption, ultrasound-guided fine needle biopsy of the

liver mass was performed in January 2010. Cytological examination revealed oligocellular substance comprising of lymphocytes and erythrocytes; tumor cells were not detected. Fine needle biopsy of the left ovarian cystoid was performed in September 2010, yielding predominantly red blood cells without tumor cell on a cytological examination.

Discussion

The prognosis of patients with inoperable and/or metastatic GISTs had been poor prior to launch of imatinib to clinical practice. The patient presented in this case report had undergone several surgeries in a short time as well as several lines of "ineffective" systemic chemotherapy. It is necessary to mention that targeted biological treatment was not available for patients with GIST in the Czech Republic till September of 2003.

In our case, the detection of *PDGFRA* mutation became a significant diagnostic tool and played an important role in therapeutic decision-making process. This illustrates that in case of a mutation in exon 12 of *PDGFRA* gene the treatment with imatinib can be beneficial even to a patient with a c-kit mutation-negative GIST. As health insurance companies generally do not reimburse

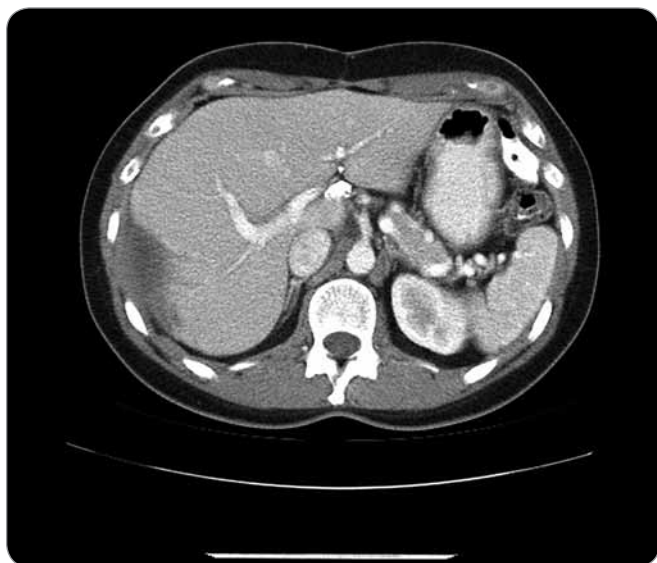

Fig. 3. Significant liver tumor regression during the treatment with imatinib; abdominal metastases are not depicted; December 2010.

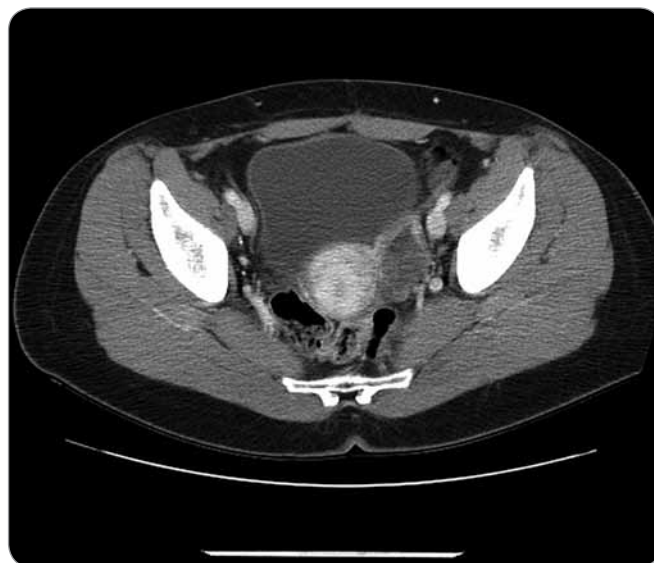

Fig. 4. Significant regression of finding in the pelvis after imatinib therapy; persisting residual cystoid in the left ovary; December 2010.

imatinib mesylate to patients with c-kit negative GISTs, it is necessary to request reimbursement for each respective case.

The patient was referred to the Masaryk Memorial Cancer Institute in March 2008 with significantly locally advanced disease accompanied with abdominal pain. Multiple organ metastatic involvement had been shown. According to CT scans, treatment with imatinib resulted in significant remission of tumor in the abdomen. Two persisting cystoids

most likely represent necrotic, non-viable metastases. During the treatment, symptoms of disease resolved completely and the clinical status of the patient has significantly improved – at the time she works as a rehabilitation nurse on a full-time basis. The patient has been treated with imatinib since March 2008 which is 60 months without any sign of disease progression. This is a unique therapeutic success in contrast to the prognosis of other metastatic sarcomas.

References

1. Fletcher CD, Berman JJ, Corless C et al. Diagnosis of gastrointestinal stromal tumors: a consensus approach. *Hum Pathol* 2002; 33(5): 459–465.
2. Heinrich MC, Corless CL, Duensing A et al. PDGFRA activating mutations in gastrointestinal stromal tumors. *Science* 2003; 299(5607): 708–710.
3. Hirota S, Ohashi A, Nishida T et al. Gain-of-function mutations of platelet-derived growth factor receptor alpha gene in gastrointestinal stromal tumors. *Gastroenterology* 2003; 125(3): 660–667.
4. Demetri GD, von Mehren M, Blanke CD et al. Efficacy and safety of imatinib mesylate in advanced gastrointestinal stromal tumors. *N Engl J Med* 2002; 347(7): 472–480.
5. Medeiros F, Corless CL, Duensing A et al. KIT-Negative Gastrointestinal Stromal Tumors: Proof of Concept and Therapeutic Implications. *Am J Surg Pathol* 2004; 28(7): 889–894.