proLékaře.cz | 25.10.2026

Multiple forms of suffocation used in double murder

Petr Handlos [1], Matěj Uvíra [1,2], Ondřej Klabal [3], Marek Joukal [4], Klára Handlosová [1]

[1] *Institute of Forensic Medicine, University Hospital Ostrava, Ostrava, Czech Republic*
[2] *The Fingerland Department of Pathology, Faculty of Medicine in Hradec Kralove, Charles University, Hradec Kralove, Czech Republic*
[3] *Department of English and American Studies , Faculty of Arts, Palacký University Olomouc, Olomouc, Czech Republic*
[4] *Department of Anatomy, Faculty of Medicine, Masaryk University, Brno, Czech Republic*

SUMMARY

This paper presents a case of double murder in which different mechanisms of suffocation, involving smothering, burking, and manual strangulation, were used. The victims are usually elderly people with disabilities and social isolation. The cases described here involve two women who were disabled and were murdered through blockage of the airway. Even though similar suffocating mechanisms were used in the murders, the autopsy findings differed between the two cases. This difference between the two can be explained by a preexisting medical condition that the younger victim had, which was quadriplegia resulting from cerebral hemorrhage, which limited herself-defense ability.

Keywords: Suffoction – Smothering – Burking – Manual strangulation – Double murder

Různé mechanismy dušení u dvojnásobné vraždy

SOUHRN

Článek popisuje případ dvojnásobné vraždy, při které byly použity různé mechanismy dušení, zahrnující překrytí dýchacích cest neprodyšným materiálem, znemožnění dýchacích pohybů a rdoušení. S kombinací výše uvedených metod dušení se můžeme v praxi běžně setkat při vraždách. Oběťmi jsou obvykle starší, sociálně izolovaní lidé se zdravotním postižením. V daném konkrétním případě se jednalo o vraždu dvou žen, matky a dcery ve věku 82 a 58 let. Přestože vraždy byly spáchány obdobnými mechanismy vedoucími k rozvoji dušení, makroskopické nálezy u obou zemřelých se odlišovaly. Zatímco u starší ženy byly dobře vytvořeny známky nasvědčující pro proběhlé dušení, u mladší ženy tyto byly zcela diskrétní. Uvedený rozdíl lze vysvětlit zvláštním osobním stavem poškozené, která byla kvadruplegická v důsledku staršího mozkového krvácení, což vedlo k omezení kompenzačníxh schopnosti organismu se znemožněním motorické činnosti a omezením schopnosti sebeobrany. Na uvedených případech chtějí autoři demonstrovat různé formy dušení, které zejména u starších, zdravotně hendikepovaných osob, mohou vést ke zcela diskrétním nálezům, což může při pitvě zapříčinit jejich přehlédnutí a stanovení nesprávné příčiny smrti.

Klíčová slova: Dušení - Smothering – Burking – Rdoušení – Dvojnásobná vražda

Soud Lek 2022; 67(3): 30–33

Smothering and burking in adults are common in murders, less so in accidental deaths, and are rare in suicides (1,2). The victims are usually older people with disabilities and social isolation with limited self-defense capacities (2,3). This paper deals with a double murder case in which smothering, burking, and manual strangulation were used to asphyxiate the victims. The cases are atypical not only because of the use of multiple asphyxiation mechanisms but also because of significant differences in external and internal examinations between the two victims.

CASE REPORT

The corpses of two women were found in a family home. One was aged 82 years and was found on the first floor; her 58-year-old daughter was found on the ground floor. Both women were found lying supine. The younger woman had a medical history of quadriplegia from rupture of a cerebral arterial aneurysm and was lying in a special nursing bed, whereas the older woman was found in a regular bed (Figure 1a, 1b). The crime scene investigation revealed no signs of struggle, self-defense, or postmortem manipulation with the bodies (Figure 1).

On-site examination of the older victim revealed well-developed signs of asphyxia, i.e., numerous facial and conjunctival petechial hemorrhages (Figure 2b) and suffusions on the eyelid conjunctiva (Fig. 2d) and oral mucosa (Figure 2f). Furthermore, minor skin abrasions were found on the forehead and nose, as well as on the right wrist and dorsal side of the right hand. The presence of hematoma at the right part of the chest was noted. The internal findings were consistent with the external examination and showed well-developed signs of asphyxia, including severe acute pulmonary emphysema (pulmonary hyperinflation) and numerous pleural and subepicardial petechial hemorrhages. The right cardiac ventricle was dilated and filled with liquid blood, and all of the organs were congested. Furthermore, fracture of the right superior horn of the thyroid cartilage and hemorrhage into the surrounding soft tissues were found. The preexisting medical conditions were described as follows: coronary atherosclerosis with the presence of the double aorto-coronary bypasses, replacement of the mitral and aortic valves by artificial prosthesis, and hypertrophic configuration of the left cardiac ventricle. Blood analyses showed a therapeutic level of tramadol (0.33 mg/l) and the presence of nicotine and caffeine. The cause of death was determined to be asphyxiation.

✉ ***Correspondence address:***
Petr Handlos, M.D., Ph.D.
Institute of Forensic Medicine
University Hospital Ostrava
17. listopadu 1790/5, Ostrava
70852, Czech Republic
E-mail: petr.handlos@fno.cz

Delivered: 00.00.2022
Accepted: 00.00.2022

proLékaře.cz | 25.10.2026

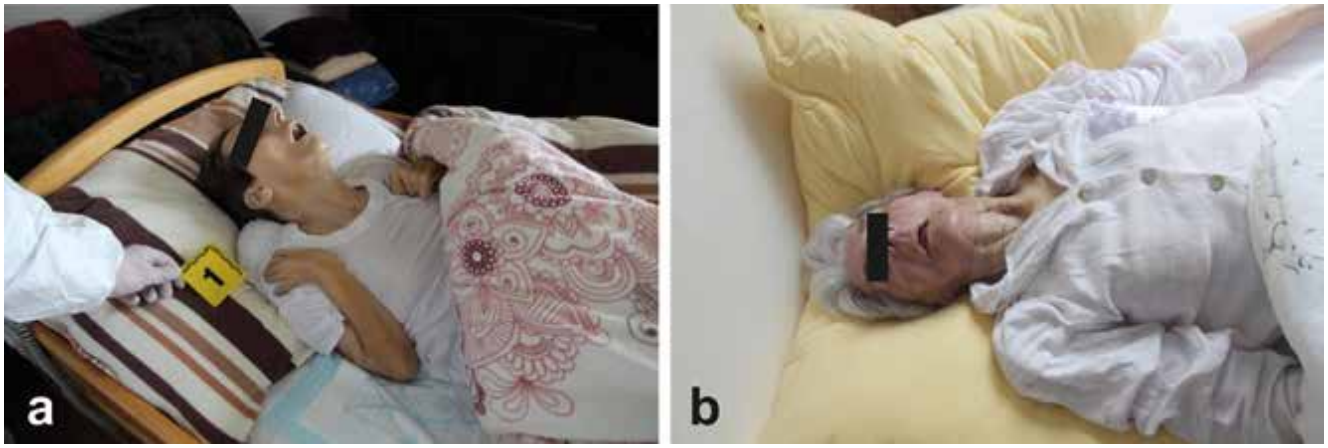

Fig. 1. The crime scene showed no signs of struggle, self-defense, or post-mortem manipulation. The 58-year-old woman (a) and her 82-year-old mother (b) were found lying dead in their beds.

The gross examination of the younger woman at the crime scene, as well as in the autopsy theater, revealed only a few minor conjunctival and oral mucosa petechial hemorrhages and minor oral mucosa abrasions (Figure 2c, 2e). The internal examination showed only minor signs of acute pulmonary emphysema (pulmonary hyperinflation) with a few pleural and subepicardial petechial hemorrhages. The right ventricle was dilated and filled with liquid blood, and all of the organs were congested. The brain examination revealed signs of previous encephalomalatic lesions (cerebral hemorrhage) in the right-side basal ganglia region as well as in the right frontal and temporal cerebral lobes. The blood analyses revealed the presence of a therapeutic level of sertraline (0.15 mg/l) and of a low concentration of metamizole. Asphyxia was determined as the proximate cause of death.

The man who reported the incident was the husband of the younger woman. He was arrested when the first police officers arrived at the scene. At the very beginning, he pleaded guilty to the double murder. He reported that he had murdered the older woman by kneeling on her chest, covering her airways with a 30 × 25 cm plastic bag, and compressing her neck with his hand. Afterward, he reported that he had killed his wife by covering her air passages using the same plastic bag he had used to kill her mother. His stated motive was an inability to continue caring for his wife and her mother.

The perpetrator was taken into custody, and his blood sample was collected for toxicological analysis. The toxicological analysis revealed the presence 72 mg/100 ml of ethanol. Extrapolating this data, the blood alcohol concentration at the time of the murders was estimated to have been 166–229 mg/100 ml. Genetic analysis of the samples collected from the plastic bag at the crime scene revealed the presence of DNA from both victims, and this bag was later determined to be "an offending weapon" used to cover the airways of the victims. These genetic findings were consistent with the perpetrator's testimony. The perpetrator was convicted of double murder and sentenced to 15 years in a high-security prison without the possibility of probation.

DISCUSSION

Although the mechanism of suffocation was similar in both victims, there was a significant contrast in autopsy findings. The autopsy of the older victim revealed well-developed signs of asphyxia and right superior thyroid horn fracture with hemorrhage into the surrounding soft tissues, which are strongly indicative of smothering or strangulation mechanisms. The autopsy findings in the younger victim, however, were faint and nonspecific and could have been easily overlooked. These weak and nonspecific findings in the younger victim were explained by a severe preexisting medical condition involving quadriplegia resulting from a stroke. Furthermore, the external examination of the corpse of the older victim revealed right hand and chest skin injuries. The presence of bruises and abrasions at the right wrist and dorsal side of the right hand were indicative of self-defense, and the chest hematoma could be explained by the perpetrator's report of having knelt on the victim's chest while covering her airway, a mechanism called "burking."

The term 'burking' is derived from the notorious criminal William Burke and his accomplice William Hare, murderers who lived in Scotland in the early part of the 19th century and who killed older people using a combination of smothering and traumatic asphyxia. The pair sold the bodies to the medical school in Edinburgh (4, 5). From 1827 to 1828, they killed 16 people (6). Their modus operandi was as follows: One of them covered the victim's airways while the other sat on the victim's chest. This atypical form of asphyxiation did not leave behind any significant injuries, allowing them to sell these bodies to the Anatomic Institute of the University of Edinburgh. Hare provided details of all of the murders, and thanks to his testimony, he was granted immunity whereas Burke was hanged in 1829.

Some authors define burking as chest compression by sitting or kneeling (7,8). Others, however, define it as a combination of chest compression and manual mouth and nose occlusion (9-12). The perpetrator in this case used the latter combination.

Smothering is a form of asphyxiation using the mechanism of external airway blockage, typically using hands, pillows, bedding, or other airtight fabrics. Smothering can also occur with gagging followed by gag aspiration or the forced push of a gag into the throat, completely blocking the airways.[13] The rapidity of asphyxiation depends on whether the airway occlusion is complete or partial.

Accidental cases of smothering are most frequent in newborns and toddlers, when the asphyxiation usually follows accidental entanglement under pillows or blankets while sleeping (14,15). In adults, suffocation following closure of the external airway is usually seen in murders, less so in accidental deaths, and very rarely in suicides (2). In murder cases, the victims are usually older and have mental or physical disabilities or both, and often are socially isolated (11). Cases have been reported of accidental asphyxiation involving nose and mouth occlusion in a prone (face-down) position in unconscious individuals (1, 16).

proLékaře.cz | 25.10.2026

Fig. 2. Faint hemorrhagic ecchymosis was found on the eyelids (arrow on c) and oral mucosa (arrow on e) in the younger woman. The body of the older victim showed petechial hemorrhages on the face (arrow in b), suffused hemorrhages in the conjunctiva (arrow on d), and hemorrhage spots in the oral mucosa (arrow in f).

Suicides using smothering are extremely rare and typically involve patients receiving psychiatric care. Saint-Martin et al. described a case in which the upper airways were blocked because of inhaled toilet paper pellets (17).

In cases of smothering, the external examination usually shows facial petechiae and congestion (18). Most of the petechial hemorrhages are seen in the ocular region, inside the eyelids, and on the oral mucosa. In addition to petechial hemorrhages, minor abrasions or bruises at the area of the nose and lips are usually seen. The imprint of the object used to close the airways or abrasions and bruising on the interdental spaces may be found. In victims with fragile teeth or with caries, a fallen or broken tooth may be found in the airways. Cases of nose deformation from smothering are also described (19). If the airways are occluded by a fibrous airtight material, the fibers of such material can be found in the oral cavity as well as in the airways. The presence of fibers in the trachea and bronchi is considered an intra-vital reaction (20). To diagnose smothering, all other possible causes of asphyxia need to be excluded, which makes the process extremely challenging.

proLékaře.cz | 25.10.2026

Manual strangulation usually leads to crescent-shaped skin abrasions on the neck, caused by nails, or to oval bruises inflicted by the fingers of the perpetrator. In addition to skin injuries from pressure on the neck, fractures of the hyoid bone and larynx are usually found (21). Further findings tend to be non-specific and can include acute lung emphysema (pulmonary hyperinflation) and lung edema with numerous petechial hemorrhages at the mucous membranes, especially the pleura and pericardium. The right cardiac ventricle is usually dilated and full of blood, while the left ventricle is usually contracted with a small amount of liquid blood. The brain shows signs of severe edema, all organs are congested, and the large vessels contain liquid blood (22).

During the police questioning, the perpetrator reported kneeling on the older victim's chest, thus fixing the torso during manual strangulation by one hand while covering the airways with a plastic bag in the other hand. After he had killed his mother-in-law, he went to the ground floor to kill his wife. He used the same plastic bag to cover her nose and mouth. He reported the rapid onset of unconsciousness and no self-defense attempts from his wife. The perpetrator's testimony was consistent with the autopsy results and further police investigation. Caregiver collapse such as this may result in murders that have been mischaracterized as "mercy killings"(23). Social supports for caregivers, including access to emergency support in exigency, should be a priority to prevent these murders.

The significant differences in autopsy findings between the two asphyxiated victims could be explained by both the severe preexisting medical condition in the younger woman (quadriplegia) and the combination of mechanisms used to asphyxiate the older woman (burking, manual strangulation, and smothering).

The correct diagnosis of smothering or burking on autopsy is a tough challenge for forensic pathologists, and the diagnosis is usually inferred after exclusion of all other causes of asphyxia. In light of these two cases, it is highly recommended to keep such mechanisms of asphyxia under consideration even in the absence of evident signs of struggle, self-defense, or post-mortem manipulation. Although smothering and burking are usually encountered in cases of murder involving victims who are socially isolated and elderly, multiple deaths in one location cannot automatically exclude the possibility, and it needs to be borne in mind. Moreover, in victims who have disabilities and severe preexisting conditions, signs of asphyxia can be very faint or may not be present at all.

FUNDING

This research received no specific grant from any funding agency in the public, commercial, or not-for-profit sectors.

CONFLICT OF INTEREST

The authors declare that there is no conflict of interest.

ETHICAL APPROVAL

All procedures performed in studies involving human participants were in accordance with the ethical standards of the institutional and national research committee and with the 1964 Helsinki declaration and its later amendments or comparable ethical standards.

REFERENCES

1. **Prahlow JA, Byard RW.** Atlas of forensic pathology: for police, forensic scientists, attorneys, and death investigators. New York: Springer; 2011: 633-692.
2. **Spitz WU, Spitz DJ, Fisher RS.** Spitz and Fisher's medicolegal investigation of death: guidelines for the application of pathology to crime investigation. Springfield: Charles C Thomas Publisher; 2006: 783-845.
3. **Falzon AL, Davis GG.** A 15 year retrospective review of homicide in the elderly. *J Forensic Sci* 1998; 43: 371-374.
4. **Buschmann CT, Rosenbaum F, Tsokos M.** Ein Fall von überlebter Thoraxkompression durch Beknien-"Burking". *Arch Kriminol* 2008; 222: 128-132.
5. **Prasad DD.** Burking: a case report. *J Evol Med Dent Sci* 2014; 3: 9959-9964.
6. **Douglas H.** Burke and Hare. *Br Hist Illus* 1978; 5: 32-43.
7. **Maxeiner H.** Gewaltsame Erstickung, Praxis Rechtsmedizin. Heidelberg: Springer; 2003: 149-163.
8. **Dettmeyer RB, Verhoff MA, Schütz HF.** Asphyxia. Forensic Medicine, Heidelberg: Springer; 2014: 227-241.
9. **Brettel H.** Ersticken infolge Strangulation, Praxis Der Rechtsmedizin. Heidelberg: Springer; 1986: 121-143.
10. **DiMaio VJ, DiMaio D.** Forensic pathology. London: CRC press; 2001: 243-244.
11. **Saint-Martin P, Bouyssy M, O'Byrne P.** An unusual case of suicidal asphyxia by smothering. *J Forensic Leg Med* 2007; 14: 39-41.
12. **Brinkmann B, Madea B.** Handbuch gerichtliche medizin. Heidelberg: Springer; 2003: 699-796.
13. **Wills SM, Johnson CP.** Homicidal smothering: vital histological confirmation of orofacial injury despite a prolonged post-mortem interval. *Forensic Sci Med Pathol* 2009; 5: 28-31.
14. **Byard RW, Jensen LL.** Fatal asphyxial episodes in the very young: classification and diagnostic issues. *Forensic Sci Med Pathol* 2007; 3: 177-181.
15. **Combrinck M, Byard RW.** Infant asphyxia, soft mattresses, and the "trough" effect. Am *J Forensic Med Pathol* 2011; 32: 213-214.
16. **Schmeling A, Fracasso T, Pragst F, et al.** Unassisted smothering in a pillow. *Int J Legal Med* 2009; 123: 517-519.
17. **Saint-Martin P, Lefrancq T, Sauvageau A.** Homicidal smothering on toilet paper: A case report. *J Forensic Leg Med* 2012; 19: 234-235.
18. **Ely SF, Hirsch CS.** Asphyxial deaths and petechiae: a review. *J Forensic Sci* 2000; 45: 1274-1277.
19. **Hicks L, Scanlon MJ, Bostwick TC, et al.** Death by smothering and its investigation. *Am J Forensic Med Pathol* 1990; 11: 291-293.
20. **Schyma C, Madea B.** Comments on unassisted smothering in a pillow. *Int J Legal Med* 2011; 125: 155-156.
21. **Hawley DA, McClane GE, Strack GB.** A review of 300 attempted strangulation cases part III: injuries in fatal cases. *J Emerg Med* 2001; 21: 317-322.
22. **Dolinak D, Matshes E, Lew EO.** Forensic pathology: principles and practice. Boston: Elsevier; 2005: 202-224.
23. **Saukko P and Knight B.** Knight's forensic pathology. 4th ed. London: CRC press; 2015: 353-398.