proLékaře.cz | 30.9.2026

Motor vehicle – pedestrian occupational accident: A case report study

Eirini Giovannopoulou[1], Valeria Karakasi[2], Stylianos Kapetanakis[3], Maria Alexandri[4], Ioannis Kougioumtzis[5], Pavlos Pavlidis[6]

[1] *Laboratory of Forensic Sciences, Medical School, Democritus University of Thrace, Alexandroupolis, Greece.*
[2] *Laboratory of Forensic Sciences, Medical School, Democritus University of Thrace, Alexandroupolis, Greece*
[3] *Spine Department and Deformities, Interbalkan European Medical Center, Thessaloniki, Greece.*
[4] *Laboratory of Forensic Sciences, Medical School, Democritus University of Thrace, Alexandroupolis, Greece.*
[5] *Department of Orthopedic Surgery, University Hospital of Alexandroupolis, Alexandroupolis, Greece.*
[6] *School of Medicine, Democritus University of Thrace, Dragana, Alexandroupolis, Evros Prefecture, Greece.*

SUMMARY

A rare case of serious non-fatal pedestrian-motor vehicle accident in the constructions sector is described, leading to severe orthopedic trauma and disability. A 49-year-old male worker was admitted to the orthopedic department due to reported occupational injury. The accident occurred at the workplace during the construction of a cycling road, where the victim as pedestrian was referred to be crashed by a motor vehicle at his left lower extremity. He consequently fell on the ground and the vehicle drifted his whole limb with its caterpillar. The patient bore occupational trauma with extensive avulsion and degloving injury of the left lower extremity, extensive hematoma formation of the extreme foot, subtalar and tarsometatarsal dislocation, open fracture of the ankle joint, intraarticular calcaneal fracture, potential vascular injury (segmentation) of the posterior tibial artery, while peroneal and dorsalis pedis arteries were identified intact in Doppler examination of the lower limb. Construction industry is one of the most hazardous industries, concerning the occupational fatality rates. Occupational injury is the leading cause of morbidity in the employed population and adversely affects productivity. Forensic evaluation focuses on the mechanism and biomechanics of the injury and enlightens the potential contribution of external factors. The forensic approach adds to the understanding of a single occupational incident and, thus, the establishment of more effective preventive strategies and the improvement of safety regulations at workplace.

Keywords: Working Environment – Occupational Risks – Workplace

Pracovní úraz – nehoda motorového vozidla s chodcem. Kazuistika

SOUHRN

V publikaci je popsán případ nehody chodce s motorovým vozidlem ve stavebnictví, vedoucí k těžkému traumatu a invaliditě. 49letý dělník byl přijat na ortopedické oddělení pro nahlášený pracovní úraz. K nehodě došlo na pracovišti při výstavbě cyklistické stezky, kde byl poškozený jako chodec sražen motorovým vozidlem s následným přejetím levé dolní končetiny. Pacient utrpěl pracovní úraz s rozsáhlým poraněním levé dolní končetiny. Stavebnictví je v Řecku jedním z nejrizikovějších odvětví, pokud jde o pracovní úmrtnost. Úraz z povolání je hlavní příčinou nemocnosti zaměstnané populace a nepříznivě ovlivňuje produktivitu. Forenzní hodnocení se zaměřuje na mechanismus a biomechaniku zranění a objasňuje potenciální přispění vnějších faktorů. Forenzní přístup přispívá k pochopení pracovního incidentu a tím k vytvoření účinnějších preventivních strategií a zlepšení bezpečnostních předpisů na pracovišti.

Klíčová slova: pracovní úrazy – prevence pracovních úrazů – biomechanika

Soud Lek 2022; 67(1): 2–5

Occupational accident is defined as an unexpected event, that includes acts of violence, happens in connection with work(or as a result of it) and has the potential to cause injury, illness -independent of severity - or even death to one or more workers (1,2). Occupational injury is any physical trauma, damage of body tissues or, even, death, that arises out of an occupational accident (1). Occupational accidents are classified as fatal, leading to death within one year and serious non-fatal, causing a minimum of 4 days absence of work (3). The final outcome may vary from temporary to permanent health (mental or physical) impairment and has numerous individual, socioeconomical and legal consequences (3).

The terms "unintended", "uncontrolled", "unplanned" were commonly used to define occupational accidents. A more sophisticated accident approach, however, is based on the use of scientific principles or systems approach, in order to identify the exact sequence of events leading to the final outcome (4). The significance of human error in the causation of occupational accidents has been moderated under the insight of recent advances in knowledge and understanding, that question the inherent safety of the systems (5). Human error is, now, considered as a normal deviation of human behavior (2) and all accidents are considered preventable under the appropriate circumstances (2). Behavioral epidemiologic data add to the conception of the human factor and the application of more effective preventive strategies (6).

Occupational injuries negatively affect the productivity and are the main cause of morbidity and mortality in the employed population (1). Forensic evaluation of the occupational trauma provides the essential data for the "reconstruction of the event", the understanding of its mechanism and biomechanics, the

✉ ***Correspondence address:***
Pavlos Pavlidis MD PhD, Associate Professor
Forensic Medicine, School of Medicine
Democritus University of Thrace
Dragana, PC 68100, Alexandroupolis
Evros Prefecture, Greece.
Tel: +30 25513 53822; Fax: +30 25513 53824
E-mail: pavlidi@med.duth.gr

proLékaře.cz | 30.9.2026

Fig. 1. Left lower limb at the initial presentation at the emergency department. Open IIIB fracture according to Gustilo-Anderson classification. Extensive hematoma formation, soft tissue loss, periosteal stripping, osseous tissue exposure, subtalar dislocation and open calcaneal fracture.

analysis of the potential causes and contributing factors and the development of prevention policies (2). Nevertheless, clinical forensic medicine investigates non-fatal occupational accidents from the perspective of civil or criminal law and leads to the collection of all the data admissible to court in a potential litigation in order to support –or not- any legal claim from the side of the victims (2).

Concerning the paucity in the literature on the forensic evaluation of occupational injuries (2), we describe a case of non-fatal occupational accident between a pedestrian worker and a machinery motor vehicle in the constructions sector. A rare case of severe physical trauma, leading to potentially permanent occupational and physical disability.

MATERIAL AND METHODS

This case was investigated by the Laboratory of Forensic Sciences of Democritus University of Thrace, Alexandroupoli. The present study is in compliance with the Declaration of Helsinki (7). The victim provided informed consent and the study was approved by the local ethics committee.

CASE REPORT

A 49-year-old male worker was admitted to the orthopedic department of the General Hospital of Kavala due to reported occupational injury. The accident occurred at the workplace during the construction of a cycling road, where the victim as pedestrian was referred to be crashed by a motor vehicle at his left lower extremity. He consequently fell on the ground and the vehicle drifted his whole limb with its caterpillar. The patient was subjected to a thorough clinical examination, routine

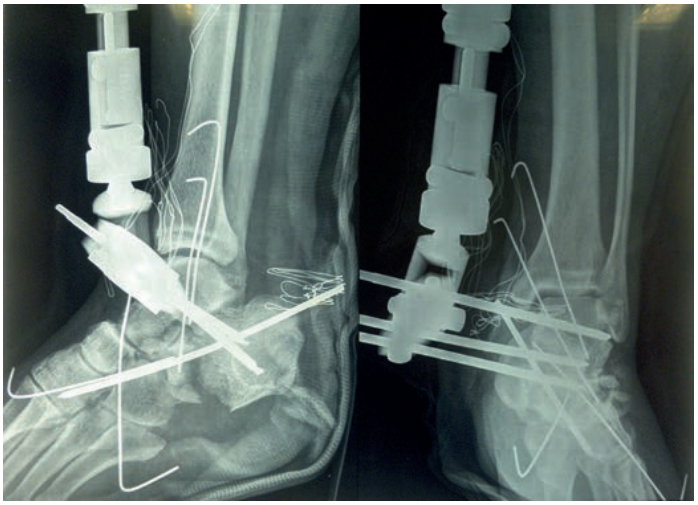

Fig. 2. Postoperative x-rays. Stabilization of the calcaneal fracture with Steinmann pins, stabilization of the tarsometatarsal joint with Kirschner wire (K-wire) and external fixation between the tibia and the midfoot.

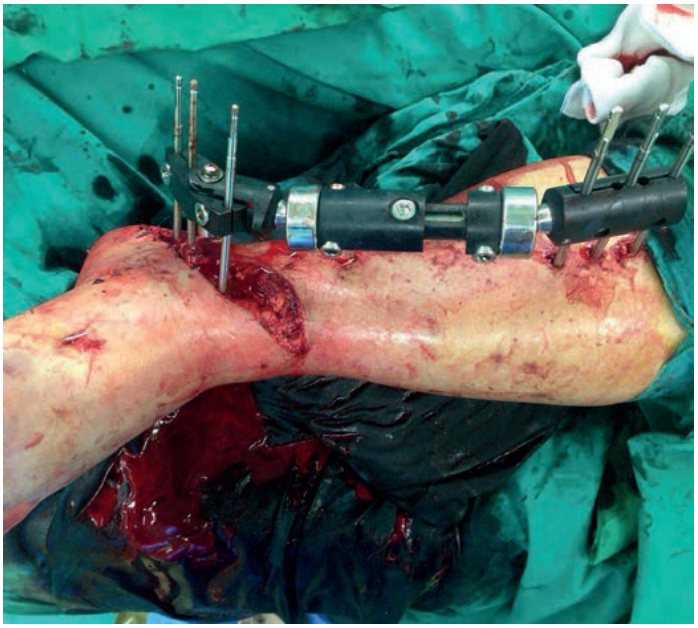

Fig. 3. Intraoperative image. External fixation between the tibia and the midfoot.

laboratory testing and radiographic imaging of the chest, pelvis, femur, tibia, knee and ankle joints, as well as plain radiographs of the extreme foot.

The findings were consistent with (i) extensive avulsion and degloving injury of the left lower extremity (ii) extensive hematoma formation of the extreme foot (iii) subtalar and tarsometatarsal dislocation (iv) open fracture of the ankle joint, intraarticular calcaneal fracture (v) potential vascular injury (segmentation) of the posterior tibial artery (Fig. 1), while peroneal and dorsalis pedis arteries were identified intact in Doppler examination of the lower limb.

After the initial presentation to the emergency department, the patient was hospitalized for immediate surgical intervention. He was subjected to operative irrigation with normal saline solution (15L), urgent and immediate debridement, reduction and stabilization of the calcaneal fracture with Steinmann pins, external fixation between the tibia and the midfoot and stabilization of the tarsometatarsal joint with Kirschner wire (K-wire) (Fig. 2, 3). Dorsalis pedis artery was identified intact by Doppler

proLékaře.cz | 30.9.2026

examination postoperatively. Pharmaceutical therapy was immediately initiated including tetanus prophylaxis (tetanus immune-globulin), intravenous antibiotics (cefuroxime, metronidazole, amikacin) and analgesics. Low molecular weight heparin was initiated for prevention of thromboembolism.

After the initial surgical management, the patient was transferred to the University Hospital of Alexandroupolis for further evaluation and hospitalization in the orthopedic department. Vascularization of the limb was examined by a vascular surgeon. Vascular supply of the limb was characterized adequate with no need for further intervention for revascularization. The worker was hospitalized for 12 calendar days and, thereafter, discharged from the hospital.

DISCUSSION

Epidemiology

In European countries, construction industry is the one of the most hazardous industries, according to the occupational fatality rates. Other industries with high risk are minimg, transportation and storage, manufacturing, agriculture, forestry and fishing (3). People employed as workers in the construction sector are under nearly at fourfold (3,5 times more) risk to become victims of a fatal occupational injury and they sustain non- fatal injuries, associated with 2.5 times higher lost-workday case rates, compared with all other industries (8).

Ore and Fosbroke investigated the causality of occupational fatality in the construction industry during a 12 year period. Falls was the predominant cause of death, followed by motor-vehicle accidents. Other leading causes were electrocution and accidents involving machinery (9). Motor vehicle accidents represented a percentage of 15 % of the total fatality in this group. In the majority of cases, the victims were pedestrians. Second in row were drivers and last passengers. Concerning the type of the motor-vehicle, trucks were involved in 54 % of the cases, while passenger vehicles and machinery constituted a 22% and 6 %, respectively.

Occupations characterized by the highest motor-vehicle fatal incidents are those associated with transportation and material moving (drivers, engineers, machinery operators and other), laborers, technicians, machine operators, assemblers and inspectors, in order of decreasing frequency (9). Age and gender -related differences in the fatality rate are, also, described, with older age and male gender being associated with higher rates. Another aspect of interest is the persistent high rates of motor-vehicle mediated accidents in the constructions sector, despite the overall decrease in occupational fatality by an average of 49 %, as reported by Ore and Fosbroke (9).

Occupational injury

Tarsus is the anatomical region of the foot that includes the talus, the calcaneus, the cuboid, the navicular and the three cuneiform bones. Calcaneus is the largest in size, followed by the talus (10). Fractures of the hindfoot are quite infrequent, but when they occur the calcaneus is the most frequently affected bone (10,11,12). Calcaneal fractures are estimated at 1- 2% of all fractures (13) and at 60-70% of all tarsal bone injuries (10).

Gustilo and Anderson is the most common classification system in the literature concerning open fractures (14). Gustilo and Anderson (1976) recognized three categories of open bone fractures, based on prognosis and optimal treatment (14,15). Leading criteria for the discrimination were (i) the size of the wound or the extent of soft tissue damage , (ii) the microbial contamination and (iii) the type of bone fracture itself (14). In 1984, Gustilo et al. further classified Type III open fractures to three sub-groups from A to C, with increasingly worse prognosis (16). According to this classification system, our case falls into IIIB category as it is associated with extreme damage of soft tissue, osseous tissue exposure, without vascular injury that demands surgical intervention. The latter characteristic if present would classify our case as IIIC. In a type IIIB fracture, the possibility of bacterial infection is as high as 52%, while that of amputation 16%, as described by Gustilo et al. (16). In a recent study, Zhang et al. have investigated the parameters significantly affecting the prognosis of open calcaneal fractures (10). As expected, the Gustilo classification was significantly connected with prognosis, with type III Gustilo fractures reaching a complication rate up to 40%. Interestingly, the prognosis was not affected by the surgical technique used for fixation (10).

Open fractures constitute a minority of all calcaneal fractures, with a prevalence greatly varying from 0.8% to 10%, among different studies (12). Detailed epidemiologic data for calcaneal fractures are reported by Mitchell et al (11). According to the findings of the study, calcaneal fractures occur in 11.5 per 100.000 of general population every year, with a gender preference to males (male to female ratio estimated at 2.4:1) (11). Nevertheless, this type of fracture commonly results from high energy injuries and has a bipolar age distribution in males, during the 3rd and 6th decade of life (11) Predominant injury mechanism is fall from height, especially above 6 feet. Only a percentage of 18.8% constitute work-related incidents. Frequent concomitant injuries from the lower extremities are dislocation of the talus, pilon type or femoral fractures with an overall frequency of 13.2% in this series. Spinal and upper extremity injuries less frequently accompany a calcaneal fracture, in 6.3% and 5.4 % of the cases, respectively (11). Additional data from the study of Court- Brown et al. support that open fractures of the calcaneus demonstrate one of the highest prevalences among type III fractures, compared with other anatomic regions and despite their rarity (17).

Functional status following open calcaneal fractures has been investigated by Berry et al (2004), using both condition-specific and generic health related quality of life questionnaires, such as the Short Form 36 questionnaire (12). Patients with a history of open calcaneal fracture scored significantly lower in the physical component of SF-36, compared to general population. Additionally, the functional ability was independent from age, gender, mechanism of injury or Gustilo classification. External wound location at the plantar surface or comminuted fractures were associated with inferior functional outcome. It must be stated that the previous study did not include any incident of occupational injury in the analysis (12).

Previous studies have investigated the socio-economical burdens of calcaneal fractures (11,18). Special anatomic features, occupational etiology, young age, extensive reconstructive operations and poor functional rehabilitation contribute to the long-term effect of the injury, at both individual and social level (10,18). In addition to the fact that their management is economically demanding, they result in a prolonged period of work absence and withdrawal of social activities (18). Brauer et al (2005) conducted an evaluation of calcaneal fractures from an economical perspective. The findings suggested that surgical treatment is more effective, but simultaneously more expensive for the health care system, compared to conservative treatment. However, when indirect costs (like absence of work) were included in the evaluation, surgical treatment was the optimal choice in terms of cost and effectiveness (18).

proLékaře.cz | 30.9.2026

CONCLUSIONS

Construction industry is a hazardous workplace, with high rates of occupational injuries. Motor – vehicle mediated accidents are the second cause of fatalities and most commonly the victim is a pedestrian. Our case report describes a motor-vehicle pedestrian occupational injury in the construction sector. Its scientific interest arises from the mechanism of the injury, as well as from the severity and infrequency of the orthopedic trauma.

CONFLICT OF INTEREST

The authors declare that they have no conflict of interest.

REFERENCES

1. **Jovanović J, Aranđelović M, Jovanović M.** Multidisciplinary aspects of occupational accidents and injuries. *Work Living Environ Prot* 2004; 2(4): 325-333.
2. **Harris C.** Occupational Injury and Fatality Investigations. *J Forensic Nurs* 2013; 9(4): 193-199.
3. European social statistics Pocketbooks European social statistics 2013 edition.
4. Occupational accident research and systems approach. *J Occup Accid* 1984; 6(1-3): 77-89.
5. **Dekker SWA.** Accidents are Normal and Human Error Does Not Exist: A New Look at the Creation of Occupational Safety. *Int J Occup Saf Ergon* 2003; 9(2): 211-218.
6. Behavioural epidemiology as a tool for accident research. *J Occup Accid* 1990; 12(1-3): 207-222.
7. World Medical Association Declaration of Helsinki Ethical Principles for Medical Research Involving Human Subjects. *WMA Gen Assem Somerset West, Repub South Africa* 1964. http://archivedpublicwebsite.up.ac.za/sitefiles/file/45/2875/Declaration of Helsinki_Fortaleza_Brazil 2013.pdf. Accessed September 27, 2017.
8. **Kisner SM, Fosbroke DE.** Injury hazards in the construction industry. *J Occup Med* 1994; 36(2): 137-143.
9. **Ore T, Fosbroke DE.** Motor vehicle fatalities in the United States construction industry. *Accid Anal Prev* 1997; 29(5): 613-626.
10. **Zhang X, Liu Y, Peng A, Wang H, Zhang Y.** Clinical efficacy and prognosis factors of open calcaneal fracture: a retrospective study. *Int J Clin Exp Med* 2015; 8(3): 3841-3847.
11. **Mitchell MJ, McKinley JC, Robinson CM.** The epidemiology of calcaneal fractures. *Foot* 2009; 19(4): 197-200.
12. **Berry GK, Stevens DG, Kreder HJ, McKee M, Schemitsch E, Stephen DJG.** Open fractures of the calcaneus: a review of treatment and outcome. *J Orthop Trauma* 2004; 18(4): 202-206.
13. **Bridgman S, Dunn K, McBride D, Richards P.** Interventions for treating calcaneal fractures. *In:* Bridgman S, ed. Cochrane Database of Systematic Reviews. Chichester, UK: John Wiley & Sons, Ltd; 2008.
14. **Gustilo RB, Anderson JT.** Prevention of infection in the treatment of one thousand and twenty-five open fractures of long bones: retrospective and prospective analyses. *J Bone Joint Surg Am* 1976; 58(4): 453-458.
15. **Kim PH, Leopold SS.** In brief: Gustilo-Anderson classification. *Clin Orthop Relat Res* 2012; 470(11): 3270-3274.
16. **Gustilo RB, Mendoza RM, Williams DN.** Problems in the management of type III (severe) open fractures: a new classification of type III open fractures. *J Trauma* 1984; 24(8): 742-746.
17. **Court-Brown CM, Bugler KE, Clement ND, Duckworth AD, McQueen MM.** The epidemiology of open fractures in adults. A 15-year review. *Injury* 2012; 43(6): 891-897.
18. **Brauer CA, Manns BJ, Ko M, Donaldson C, Buckley R.** An Economic Evaluation of Operative Compared with Nonoperative Management of Displaced Intra-Articular Calcaneal Fractures. *J Bone Jt Surg* 2005; 87(12): 2741.