proLékaře.cz | 29.9.2026

Complex suicide involving pyrethroid ingestion (mosquito coils) and fatal self-wounding by sharp force

Maria – Valeria Karakasi[1,2], Pavlos Pavlidis[2], Epameinondas Vasilikos[1], Doxakis Anestakis[3], Nikolaos Raikos[3]

[1]Adult Psychiatry, Psychiatric Department, G. Papanikolaou General Hospital of Thessaloniki, Thessaloniki, Greece
[2] Laboratory of Forensic Sciences, School of Medicine, Democritus University of Thrace, Alexandroupolis, Greece
[3] Laboratory of Forensic Medicine and Toxicology, Faculty of Medicine, Aristotle University of Thessaloniki, Thessaloniki, Greece

SUMMARY

"Complex suicide" is a term referring to the suicidal pattern in which more than one suicidal method is applied in the purpose of inducing death. The present paper aims to review complex suicide literature shortly and investigate an unusual planned complex suicide incident, the rarity of which is attributable to the combination of suicide methods as well as the type and quantity of substances applied to induce poisoning.
A 33-year-old man with a history of psychotic depression was found dead in his bedroom lying within a large quantity of blood. He had already committed two previous suicide attempts and he was under treatment with antidepressants. The forensic examination revealed the use of the following successive suicide methods: benzodiazepine and alcohol intake, pyrethroid poisoning due to ingestion of mosquito coils, wrist cutting, and a fatal cut in the victim's neck. Death occurred due to hemorrhagic shock.
Furthermore, the authors extensively discuss the use of sharp force in suicide and the discrimination "tools" between suicide and homicide.

Keywords: forensic pathology – complex suicide – pyrethroids

SOUHRN

Použije-li sebevrah k ukončení svého života dvě nebo i více smrtících metod, pak soudnělékařská terminologie hovoří o tzv. **kombinované (komplexní) sebevraždě**. Její incidence se pohybuje od 1,5 do 5 % všech sebevražd. Plánovaná (primární) kombinovaná sebevražda zahrnuje úmyslný výběr a současné užití více sebevražedných metod, naopak u neplánované (sekundární) kombinované sebevraždy vyplývá použití dalšího smrtícího způsobu až ze selhání toho předcházejícího. Na rozdíl od primární kombinované sebevraždy zahrnující současné použití více metod, u sekundární kombinované sebevraždy sebevrah k jednotlivým způsobům sebevraždy přistupuje postupně.
Cílem práce je podání krátkého přehledu literatury věnující se sebevraždám a popis neobvyklého případu plánované kombinované sebevraždy, jehož neobvyklost spočívala v kombinaci použitých sebevražedných metod (včetně druhu a množství látek požitých za účelem otravy).
33letý muž s anamnézou psychických depresí byl nalezen mrtvý ležící na posteli na levém boku v tratolišti krve. Uvnitř místnosti a v kapsách zemřelého se nacházelo větší množství zápalných spirál proti komárům. Muž se již v minulosti dvakrát pokusil o sebevraždu a užíval antidepresiva.
Pitva odhalila použití následujících postupně použitých sebevražedných metod: požití benzodiazepinu a alkoholu, požití pyrethroidů obsažených v zápalných spirálách proti komárům, řezné rány na zápěstí a smrtelnou řeznou ránu na krku délky 12 cm a hloubky 3,5 cm, nacházející se v jugulární krajině vpravo. Vnitřní prohlídkou bylo zjištěno akutní nedokrvení vnitřních orgánů a velké množství nazelenalé látky v žaludečním obsahu pocházející ze zápalných spirál proti komárům.
Ačkoli požití zápalných spirál proti komárům je vzácné, otravy pesticidy a insekticidy jsou často používanou metodou sebevraždy, která tvoří každoročně více než třetinu všech případů sebevražd. Oproti tomu sebepoškození bodnořezným nástrojem je vzácnou metodou sebevraždy, která představuje ve většině zemí pouze 2–3 % z celkového počtu sebevražd. Přitom v západních zemích se jedná naopak o běžný způsob vraždy, a to z důvodu existence přísných zákonů o kontrole střelných zbraní. Proto je v těchto případech ze soudnělékařského hlediska třeba věnovat náležitou pozornost odlišení vraždy a sebevraždy. Autoři široce diskutují použití bodnořezného nástroje ke spáchání sebevraždy a metody odlišení úmyslného sebepoškození od vraždy, neboť možnost vraždy nemůže být bez znalosti všech okolností případu soudním lékařem ihned vyloučena.

Klíčová slova: soudní lékařství – kombionovaná sebevražda – pyrethroidy

Soud Lek 2017; 62(4): 45-50

Suicide typology by Marcinkowski and his colleagues distinguishes suicide cases into simple and complex (1-3). The term "complex suicide" defines the suicidal pattern in which more than one suicide methods are applied in the purpose of inducing death (2-5). Complex suicides account for 1.5 – 5 % of all suicides and can be, in turn, divided into further sub-categories: (a) planned and unplanned; and (b) primary and secondary (6).

Planned complex suicides include the element of premeditation in regard of the selection of suicide methods, which are previously planned in order to ensure that the outcome will be fatal (even if one fails) (1-3). In history, a famous complex suicide was committed by Adolf Hitler, who took a cyanide pill and shot himself in the head (3,7). On the contrary, unplanned complex suicides include elements of impulsivity and improvisation, as the succession of suicide methods is not planned. In regard of the latter, if the originally selected method fails, the victim

✉ ***Correspondence address:***
Pavlos Pavlidis M.D., Ph.D.
Assistant Professor Forensic Medicine
School of Medicine, Democritus University of Thrace,
Dragana, 68100, Alexandroupolis, Evros Prefecture, Greece.
tel: +30 25513 53822
fax: +30 25513 53824
e-mail: pavlidi@med.duth.gr

proLékaře.cz | 29.9.2026

Table 1. Suicide taxonomy.

Simple suicide			Death occurs due to one suicide method.
Complex suicide			Death occurs due to more than one suicide method.
	(a)	Planned	The combination of suicide methods is previously planned.
		Unplanned	The secondary suicide method is applied only after the first one has failed.
	(b)	Primary	Suicide methods are applied simultaneously.
		Secondary	Suicide methods are applied in chronological sequence.
Complicated suicide			Death results from an unintentional secondary traumatization following the original suicide method.

attempts to find one or several other, more effective or less painful methods. In unplanned complex suicides, injuries by sharp force are often found as the primary act of suicide, which most frequently fails due to dullness or mishandling of the weapon, great pain, or vague knowledge of anatomy (1-3).

Furthermore, a complex suicide is characterized as "primary" if the methods are applied simultaneously. If the mechanisms are applied successively (even in a fast chronological sequence), however, a complex suicide is classified as "secondary" (6).

"Complicated suicide" is an additional term encountered in the literature, which differs from complex suicide. This term involves fatal cases that result from an accidental secondary event, which occurs sequentially to the initial suicide method (6,8). Suicide typology is summarized in **Table 1**.

Throughout international literature, several cases of complex suicide have been described and the suicidal methods involved include: (a) sharp force; (b) insecticide ingestion; (c) firearms (one or two firearms simultaneously); (d) medicine overdose; (f) hanging; (g) falling from a height; (h) self-strangulation (i) drowning; (j) liquefied petroleum gas and/or natural gas inhalation; (k) fungicide ingestion; (l) rodenticide ingestion; (m) corrosive ingestion; (n) self-incineration; (o) transdermal nicotine poisoning with homemade nicotine patches; (p) self-electrocution; and (q) ingestion of pointed objects (e.g., nails, pins, knives, needles) (4,9-39). The greatest number of suicidal methods that have been described to have been applied in a single case of complex suicide are six (6), involving wrist cuts, neck cuts, insecticide ingestion, ingestion of HCl, self-inflicted craniocerebral stab wounds by a screwdriver shaft, and hypothermia (6).

Complex suicide victims are most frequently young to middle-aged individuals with male gender predominance (10,16,28). The majority of suicide victims had been formerly diagnosed with a psychiatric disorder. Personality disorders, schizophrenia and depression are the most common diagnostic entities prevailing throughout decedents' histories (10,28,29).

In the present study, an unusual planned complex suicide case is described. The rarity of the following incident is attributable to the combination of suicide methods, as well as the type and quantity of the substances applied to induce poisoning. Drug intoxication, ingestion of mosquito coils (pyrethroids), and stab wounds were the suicide methods involved.

CASE REPORT

Background

A 33-year-old man was found dead by his mother lying within a large amount of blood inside the bedroom of his house. The decedent had been suffering from depressive disorder with psychotic symptoms and suicidal ideation for 8 years and was under medication with antidepressants. The suicide victim had already committed two previous suicide attempts. He was single and unemployed.

Death scene investigation and external post mortem examination findings

During the forensic investigation of the death scene, the accumulation of a large amount of blood was observed in the room. The deceased was found lying on his bed in a supine position. No suicide note was detected. In his right hand, he was holding a knife with a total length of 32 cm, which bore a 20-cm-long blade. A 12-cm-long cut wound was detected in the decedent's right jugular area (neck) which was induced by a penetrating and cutting agent (knife). Its depth reached 3.5 cm and led to extensive bleeding. A 6.4-cm-long superficial tentative cut was also present 1 cm below the latter (**Fig. 1**). In addition, a 5-cm-long tentative cut was detected in the lowest third of the anterior surface of the decedent's left forearm (wrist). Its depth was 1cm, but was confined to the skin and subcutaneous fat, without damaging the underlying vessels. It bore smooth traumatic edges and was consistent with a knife blade injury.

Furthermore, numerous pieces of mosquito coil were found scattered within the room and in the pockets of the deceased (**Fig. 2**). Greenish coloration of the decedent's tongue was noted, which was compatible with the green color of the spiral mosquito coils.

Table 2. Symptomatology of acute pyrethroid intoxication.

Mild pyrethroid toxicity	Moderate pyrethroid toxicity	Severe pyrethroid toxicity
Paresthaesia	Central nervous system depression	Seizures
Nausea	Increased salivation	Coma
Anorexia	Blurred vision	Pulmonary edema
Vomiting	High body temperature	Respiratory failure
Headache	Diaphoresis	
Fatigue	Fasciculations	
Dizziness		

proLékaře.cz | 29.9.2026

Additionally, two (2) tattoos were detected on the body of the decedent: one in the lowest third of the right arm, and one in the anterior surface of the left forearm.

Autopsy findings

During the dissection of the cranial cavity, exsanguination of the cerebrum was noticed, and similarly, during the dissection of the thoracic cavity, exsanguinated thoracic viscera were observed, as well. Pulmonary edema of low degree was also noted. In the right jugular region, a traumatic cross section of the vessels (jugular vein and carotid artery) was detected, also involving discontinuance of the underlying muscles and nerves (cutting wound dimensions: 12 x 3.5 cm) (**Fig. 1**).

The dissection of the abdominal cavity revealed a large quantity of greenish material inside the stomach (mosquito coils). Material of the same color was also detected in the esophagus and on the tongue of the deceased (**Fig. 3**). All abdominal viscera were exsanguinated.

Death occurred due to hemorrhagic shock, resulting from the deep cut in the decedent's right jugular area (neck) which was inflicted by a penetrating and cutting agent (knife).

Toxicological examination was conducted on the victim's biological fluids and viscera (blood, urine, kidney, liver section with gall bladder and gastric content) through Gas Chromatography – Mass Spectrometry (GC-MS) method after liquid – liquid extraction. Results indicated that the decedent was positive for alcohol (27.18 mg/dl) in serum. Furthermore, diazepam (benzodiazepines) metabolites were detected in urine at a concentration of 762.66 ng/ml. Pyrethrin I and pyrethrin II (mosquito coil compounds) were detected in the gastric content of the deceased. (The screening and identification of pyrethroids in the gastric content was qualitative rather than quantitative, and therefore the concentrations are not available.) No metabolites were detected from the rest of the deceased's psychiatric treatment (e.g. antidepressants).

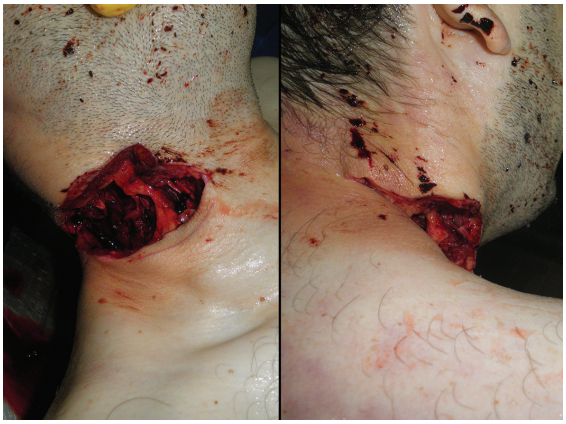

Fig. 1. The anterior and posterior side of the fatal cut wound with dimensions 12 x 3.5 cm in the right jugular area. Concomitant traumatic cross section of the vessels (jugular vein and carotid artery) can be observed, as well as discontinuance of the underlying muscles and nerves. Image taken during external forensic examination.

Fig. 2. Pieces of mosquito coils found in the pockets of the deceased. Image taken during external forensic examination.

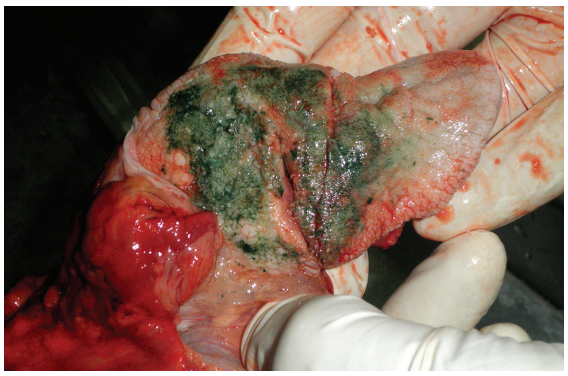

Fig. 3. Greenish coloration of the tongue due to mastication and consumption of mosquito coils. Image taken during autopsy.

DISCUSSION

In the present case study, three (3) successive suicide methods can be counted: (a) poisoning due to pyrethroids (ingestion of mosquito coils), (b) wrist cutting (a trial cut with dimensions 5x1cm in the flexor side of the wrist), and (c) neck cuts (a deep cutting wound with dimensions 12x3.5cm in the right jugular area coupled with a shallow tentative cut situated directly below).

The benzodiazepines that the decedent ingested at once were in his monthly prescribed treatment. Benzodiazepines and alcohol were used as assistive agents, as their combination aimed to increase the intensity of the symptoms of sedation and reduced pain sensation, so that the inducer could inflict lesions capable of causing massive bleeding and be exempt from experiencing the complete duration of the process. Racette and Sauvageau did not consider the simultaneous intake of drug and/or medicine as an additional method of suicide, as the combination of drug and/or medicine is very common with otherwise simple suicides and this inclusion lessens the reach of the definition of complex suicide (5). In the present case study, toxicological findings indicated that benzodiazepines and alcohol were assistive to the accomplishment of suicide but were not consumed at a fatal dose and, thus, the simultaneous intake of alcohol and benzodiazepines was excluded as an additional suicide method.

The deceased had a long psychiatric history of depressive disorder with psychotic symptoms, experienced active suicidal ideation and had previously attempted to commit suicide twice. The present suicide incident was an outcome of planning rather impulse, as the decedent had earlier obtained large amounts of mosquito coils, alcohol, and the wounding agent (32-cm-long knife) (police investigation data). Therefore, the present incident involves a planned secondary complex suicide incident.

In the aforementioned case, evidence of severe pyrethroid toxicity was present due to the concomitant pulmonary edema (which was of low degree due to massive blood loss), while the decedent's lungs were exsanguinated (**Tab. 2**) (39-42). Ten (10) mosquito coils were estimated to have been ingested by the

proLékaře.cz | 29.9.2026

deceased, as they were missing from the mosquito coil packs (approximately 226 gr). The remainders were found fragmented in his pockets. Although mosquito coil ingestion is a rarity (39-42), poisoning by pesticides and insecticides is one of the leading suicide methods and accounts for more than one third of all suicide cases each year in the world (43).

Pyrethroid toxicity

Pyrethroids are synthetic modifications of natural pyrethrins, which are organic compounds (esters) normally derived from Chrysanthemum cinerariifolium (flower). Pyrethrum (natural extract) was used for centuries as an insecticide in Persia and Europe (39-42).

Pyrethroid products involve aerosol sprays, smoke coils, electric mats, oil formulations, emulsifiable concentrates as well as powders. A pyrethroid shampoo formulation is also available for the control of human lice. Commercial formulations usually contain piperonyl butoxide, a synergist which inhibits the metabolic degradation of the active ingredients (39-42, 44-51).

Mosquito coils are manufactured from a mosquito repelling incense shaped into a spiral, which consists of the following ingredients (both active and inactive): (a) pyrethrum (natural extract); (b) pyrethrins (extracts of pyrethrum); (c) allethrin (sometimes d-trans-allethrin, the first synthetic pyrethroid); (d) esbiothrin (a form of allethrin); (e) butylated hydroxytoluene (inert ingredient that prevents pyrethroid oxidation during burning); (f) piperonyl butoxide (additive that improves pyrethroid effectiveness); and (g) N-Octyl bicycloheptene dicarboximide or „MGK 264" (inert ingredient that improves pyrethroid effectiveness) (52).

Pyrethroids are ion channel toxins that cause neurotoxicity. They interfere with the function of the nervous system by modifying the gating characteristics of neuronal sodium channels and delaying their closure, thereby resulting in prolongation of neuronal excitation and nervous system overactivity (39-42).

Pyrethroids have a potent selective toxicity for insects compared to mammals, by targeting the sensitive nervous system of insects, while they are considered to be low-toxicity pesticides from a human health standpoint, due to poor skin absorption and more efficient hepatic metabolism among mammals. Pyrethroids, however, are readily absorbed from the gastrointestinal and respiratory tract. Therefore, ingestion of concentrated pyrethroid-containing products is capable of causing severe and occasionally fatal effects to the human body (39-42, 44-50).

Pyrethroid toxicity derives from neuronal excitation and includes a wide spectrum of symptoms ranging from paraesthesia and increased salivation to seizures, coma and death. **Table 2** summarizes the symptoms of acute pyrethroid intoxication. Management of pyrethroid toxicity is supportive and symptomatic (39-42, 44-50).

Sharp force injuries in suicide

Sharp force (self-inflicted cutting or stabbing) is an extremely rare method of suicide representing only 2-3% of total suicidal cases in most countries (3,53-58).

Bonhert and Pollak suggested that sharp force, especially in the flexor surface of the elbows and wrists, is usually found as a primary suicidal method in cases of complex suicide (2). It is frequently observed that complex-suicide victims opt for methods of lesser lethality before choosing more lethal techniques. The selection change from lesser to greater methods of lethality is most likely associated with pain, anguish and frustration (3,29).

In forensic pathology, stab wounds are defined as sharp injuries whose depth into the body exceeds its length on the skin surface. Incised wounds (or cuts) are sharp injuries whose length on the surface exceeds the depth into the body (3,59-61).

Hesitation (tentative) injuries are defined as superficial stabs or cuts, resulting when the suicidal patients attempt to incise their skin. These injuries are frequently close to the fatal wound, but they may be alternatively located in other parts of the body (3,59,62,63). Although tentative injuries are shallow, their depth may range from affecting just the epidermis to lacerating even the subcutaneous fat (3,60,64).

As far as the dynamics of sharp force injuries are concerned, a number of factors have to be assessed: (a) the sharpness of the wounding agent, (b) its velocity at the moment of impact, and (c) the skin resistance and elasticity (Langer's lines) (3,64).

Although sharp force is a rare suicidal method, it is the primary homicide method in western countries, due to strict gun-control laws (53-58). Therefore, a major forensic issue also arises concerning the differential diagnosis between suicide and homicide. In sharp force injury cases, the morphological criteria of injuries should be observed, as they can provide useful information to distinguish between homicide and suicide.

In cases of death due to a penetrating trauma, the localization of sharp force injuries may be assistive in terms of discrimination between suicide and homicide. The main criterion of suicidal victims in their choice of anatomical areas for sharp force wounds is the efficiency of trauma infliction. Therefore, the most frequently-wounded anatomical regions are: the ones with vital organs such as the heart and the lungs, the major vessels of the neck (carotid arteries, jugular veins) and the vessels of the extremities (radial and brachial arteries) (60,62).

With regard to hesitation wounds, the most common anatomical sites are: (a) the jugular region, (b) the left thoracic region, and (c) the lowest third of the upper extremities (wrists). Furthermore, hesitation wounds are more likely to be multiple and adjacent to each other forming clusters (60,62).

Throughout literature, some anatomical regions have also been reported as very infrequent in regard to the localization of self-inflicted sharp force injuries. Hesitation wounds are extremely rare in the face of a suicide victim, for instance. These findings are consistent with several empirical research studies, such as Gill et al. in New York, Karlsson et al. in Sweden, and Karger et al. in Germany (54,57,61). Only a single case was reported by Vanezis and his colleagues, in which hesitation wounds were present in the face. The decedent also inflicted stabs which were located on the chest and abdomen (60).

On the contrary, sharp force injuries located in the posterior surface of the torso (back) are strongly indicative of homicide. No self-inflicted cuts / stabs have ever been found on the back of a suicide victim (62).

As the localization of hesitation wounds should be in accordance with the handedness of the deceased (right- or left-handedness), the latter is used as an additional indicative point as to whether a wound could have been caused by the deceased himself, as an act of self-harm (62).

Furthermore, a contrast in the localization pattern of hesitation marks (low dispersion) and defense wounds (high dispersion) was highlighted through a graphical depiction in the research study of Racette and his colleagues. This empirical study has to be replicated, however, in larger samples, so that the reliability of the conclusions be enhanced reliable and formulate a useful criterion for the distinction between suicide and homicide (62).

While the presence of hesitation wounds may be classic, typical or highly suggestive in suicide, they may not occur uniquely in this condition, as they have been found in homicidal cases as well, and therefore they are not a pathognomonic finding that determines the forensic distinction between suicide and homicide beyond any doubt (56,63-66).

The detailed examination of the death site, the existence of

proLékaře.cz | 29.9.2026

active suicidal ideation and/or psychiatric history and the toxicological findings are additional indicative factors (56,63,65,66).

CONCLUSION

The present paper aims to summarize complex suicide literature and describe a planned complex suicide incident involving drug intoxication, ingestion of mosquito coils (pyrethroid poisoning), and self-inflicted sharp force to the wrist and neck.

Complex suicide is a rare phenomenon as it accounts for 1.5 to 5% of all suicides. Sharp force (self-inflicted) is also a very rare suicide method accounting for 2-3% of all suicides, whereas it is the main method of homicide in western countries where gun control laws are very strict. A major forensic concern, thus, arises when it comes to the distinction between suicide and homicide. Vigilance is required, as the hypothesis of homicide cannot be excluded fast by forensic pathologists, who have to take numerous factors into consideration.

Furthermore, the mastication and ingestion of mosquito coils is a very rare suicide method of poisoning and, to the authors' knowledge, the single one described in a complex suicide incident. The combination of all the aforementioned methods renders the present case of complex suicide a rarity to forensic literature.

CONFLICT OF INTEREST

The authors declare that there is no conflict of interest regarding the publication of this paper.

REFERENCES

1. **Marcinkowski T, Pukacka-Sokolowska L, Wojciechowski T.** Planned complex suicide. *Forensic Sci* 1974; 3(1): 95-100.
2. **Bohnert M, Pollak S.** Complex suicides--a review of the literature. *Arch Kriminol* 2004; 213(5-6): 138-153.
3. **Karakasi MV, Nastoulis E, Kapetanakis S, Vasilikos E, Kyropoulos G, Pavlidis P.** Hesitation wounds and sharp force injuries in forensic pathology and psychiatry: Multidisciplinary review of the literature and study of two cases. *J Forensic Sci* 2016; 61(6): 1515-1523.
4. **Demirci S, Dogan KH, Erkol Z, Deniz I.** A series of complex suicide. *Am J Forensic Med Pathol* 2009; 30(2): 152-154.
5. **Racette S, Sauvageau A.** Planned and unplanned complex suicides: a 5-year retrospective study. *J Forensic Sci* 2007; 52(2): 449-452.
6. **Petković S, Maletin M, Durendić-Brenesel M.** Complex suicide: an unusual case with six methods applied. *J Forensic Sci* 2011; 56(5): 1368-1372.
7. **O'Donnell JP.** The Bunker. New York: Da Capo Press 2001: 230, 323.
8. **Töro K, Pollak S.** Complex suicide versus complicated suicide. *Forensic Sci Int* 2009; 184(1-3): 6-9.
9. **Dogan KH, Demirci S, Deniz I.** An unusual complex suicide by corrosive ingestion and stabbing. *Case Reports in Clinical Pathology* 2014; 1(1): 8-13.
10. **Bohnert M.** Complex Suicides. In: **Tsokos M,** ed. Forensic Pathology Reviews. Vol 2. Totowa, NJ: Humana Press Inc; 2005: 127-143.
11. **Nor FM, Das S.** Planned complex suicide: Self--strangulation and fall from height. *Journal of Forensic and Legal Medicine* 2011; 18(7): 336-339.
12. **Youssef N, Wiem BA, Sami B, Malek Z, Zouhir H, Samir M.** An Unusual Complex Suicide by Pesticide Ingestion and Stabbing: A Case Report. *Austin J Forensic Sci Criminol* 2015; 2(4): 1039.
13. **Kučerová S, Hejna P, Zátopková L, Straka L.** Primary and secondary complex suicide. A 30-year retrospective suicide. *Soud Lek* 2012; 57(3): 51-55.
14. **Blanco-Pampín JM, Suárez-Peñaranda JM, Rico-Boquete R, Concheiro-Carro L.** Planned complex suicide. An unusual suicide by hanging and gunshot. *Am J Forensic Med Pathol* 1997; 18(1): 104-106.
15. **Cascini F, Longo F, Polacco M, Scafetta I.** Foreign object ingestion in complex suicide: a case report and review of the literature. *Forensic Sci Int*. 2012; 219(1-3): e1-3.
16. **Bohnert M, Rothschild MA.** Complex suicides by self-incineration. *Forensic Sci Int* 2003; 131(2-3): 197-201.
17. **Lardi C, Vogt S, Pollak S, Thierauf A.** Complex suicide with homemade nicotine patches. *Forensic Sci Int* 2014; 236: e14-8.
18. **Palmiere C, Risso E, van Hecke O, La Harpe R.** Unplanned complex suicide by self-strangulation associated with multiple sharp force injuries: a case report. *Med Sci Law* 2007; 47(3): 269-273.
19. **Schlenger R, Kaatsch HJ, Grellner W.** Unusual circumstances in a fourfold complex suicide. *Arch Kriminol* 2008; 221(5-6): 149-158.
20. **Martínez MA, Ballesteros S.** Toxicological findings in two planned complex suicide cases: ingestion of petroleum distillates and subsequent hanging. *J Anal Toxicol* 2009; 33(6): 336-342.
21. **Kaliszan M, Karnecki K, Tomczak E, Gos T, Jankowski Z.** Complex suicide by self-stabbing with subsequent drowning in the sea. *J Forensic Sci* 2013; 58(5): 1370-1373.
22. **Padosch SA, Schmidt PH, Madea B.** Planned complex suicide by self-poisoning and a manipulated blank revolver: remarkable findings due to multiple gunshot wounds and self-made wooden projectiles. *J Forensic Sci* 2003; 48(6): 1371-1378.
23. **Fatteh A, Gore SB, Mann GT, Garvin K.** Suicide with two guns: a unique case. *J Forensic Sci* 1980; 25(4): 883-885.
24. **Ulucay T, Yavuz MS, Kir MZ, et al.** A case of complex suicide: Self-electrocution. *Medical Science and Discovery* 2014; 1(2): 61-63.
25. **Vidhate SG, Pathak H, Parchake M, Sukhadeve R, Meshram V.** A planned complex suicide: Cut injury to the wrist with corrosive acid poisoning. *Egypt J Forensic Sci* 2016; 6(4): 478-480.
26. **Beltempo P, Tattoli L, Candela RG, Solarino B.** Planned Complex Occupation-related Suicide by Sulfuric Acid Ingestion and Thorax Stab Wound: Case Report. *Arab J Forensic Sci & Forensic Med* 2015; 1(2): 237-243.
27. **Turk EE, Anders S, Tsokos M.** Planned complex suicide. Report of 2 autopsy cases of suicidal shot injury and subsequent self-immolation. *Forensic Sci Int* 2004; 139: 35–38.
28. **Cingolani M, Tsakri D.** Planned complex suicide: report of three cases. *Am J Forensic Med Pathol* 2000; 21(3): 255-260.
29. **Taff ML, Boglioli LR, Danto BL.** Planned complex suicide. *Am J Forensic Med Pathol* 1998; 19: 194.
30. **Altun G.** Planned complex suicide: report of three cases. *Forensic Sci Int* 2006; 157(2-3): 83-86.
31. **Maeda H, Imura M, Higuchi T, Noguchi K.** An autopsy case of suicide by hanging with multiple stab wounds of the neck and chest. *Med Sci Law* 1993; 33(1): 67-69.
32. **Nadjem H, Weinmann W, Pollak S.** Ingestion of pointed objects in a complex suicide. *Forensic Sci Int* 2007; 171(1): e11-4.
33. **Lignitz E, Strauch H.** Combined suicide caused by burns and falling from a high place. *Arch Kriminol* 1986; 178(1-2): 51-53.
34. **Viel G, Schröder AS, Püschel K, Braun C.** Planned complex suicide by penetrating captive-bolt gunshot and hanging: case study and review of the literature. *Forensic Sci Int* 2009; 187(1-3): e7-11.
35. **Faller-Marquardt M, Bohnert M, Logemann E, Pollak S.** Combined suicide by drinking acetic acid with subsequent hanging. *Arch Kriminol* 2000; 206(5-6): 140-149.
36. **Türk EE, Tsokos M.** Vehicle-assisted suicide resulting in complete decapitation. *Am J Forensic Med Pathol* 2005; 26(3): 292–293.
37. **Adair TW, Fisher A.** Suicide with associated acts of arson: two cases from Colorado. *J Forensic Sci* 2006; 51(4): 893-895.
38. **Graham MA, Poklis A, Mackell MA, Gantner GE.** A case of suicide involving the concomitant intravenous injection of barbital and oral ingestion of arsenic. *J Forensic Sci* 1983; 28(1): 251-254.
39. **Proudfoot AT.** Poisoning due to pyrethrins. *Toxicol Rev* 2005; 24(2): 107-113.
40. **Bradberry SM, Cage SA, Proudfoot AT, Vale JA.** Poisoning due to pyrethroids. *Toxicol Rev* 2005; 24(2): 93-106.
41. **He F, Wang S, Liu L, Chen S, Zhang Z, Sun J.** Clinical manifestations and diagnosis of acute pyrethroid poisoning. *Arch Toxicol* 1989; 63(1): 54-58.
42. **Beasley M, Temple W,** National Poisons Centre. Pyrethroid toxicity and its management. Available at: http://www.bpac.org.nz/BPJ/2013/December/docs/BPJ57-pyrethroid.pdf Accessed 03 May 2016.
43. **Bertolote JM, Fleischmann A, Eddleston M,**

proLékaře.cz | 29.9.2026

Gunnell D. Deaths from pesticide poisoning: a global response. *Br J Psychiatry* 2006; 189(3): 201-203.
44. **Giampreti A, Lampati L, Chidini G, et al.** Recurrent tonic-clonic seizures and coma due to ingestion of Type I pyrethroids in a 19-month--old patient. *Clin Toxicol (Phila)* 2013; 51(6): 497-500.
45. **Altenkirch H, Hopmann D, Brockmeier B, Walter G.** Neurological investigations in 23 cases of pyrethroid intoxication reported to the German Federal Health Office. *Neurotoxicology* 1996; 17: 645-651.
46. **Dewan G.** Mosquito coil poisoning with neurological manifestation. *Int J Med Toxicol & Forensic Med* 2015; 5(2): 102-104.
47. **Ardhanari A, Srivastava U, Kumar A, Saxena S.** Management of a case of prallethrin poisoning-an unusual agent for suicidal ingestion. *Sri Lankan J Anaesthesiol* 2011; 19(1): 51-52.
48. **Khokon MK, Islam AHMS, Basher A, Alam MR, Faiz MA.** Patterns of Self Poisoning by Household Substances. *Int J Med Toxicol Forensic Medicine* 2011; 1(2): 59-64.
49. **Garg P, Garg P.** Mosquito Coil (Allethrin) Poisoining in Two Brothers. *Indian Pediatrics* 2004; 41: 1177-1178.
50. **Yang PY, Lin JL, Hall AH, Tsao TC, Chern MS.** Acute ingestion poisoning with insecticide formulations containing the pyrethroidpermethrin, xylene, and surfactant: a review of 48 cases. *J Toxicol Clin Toxicol* 2002; 40(2): 107-113.
51. World Health Organization. WHO specifications and evaluations for public health pesticides: d-allerthrin. Geneva: WHO; 2002. Available at: http://www.who.int/whopes/quality/en/dAllethrin_spec_eval_March_04.pdf Accessed 03 May 2016.
52. **Strickman D, Frances SP, Debboun M.** Prevention of Bug Bites, Stings, and Disease. New York: Oxford University Press; 2009: 117.
53. **Start RD, Milroy CM, Green MA.** Suicide by self-stabbing. *Forensic Sci Int* 1992; 56(1): 89-94.
54. **Karger B, Niemeyer J, Brinkmann B.** Suicides by sharp force: typical and atypical features. *Int J Legal Med* 2000; 113(5): 259-262.
55. **Sloan JH, Kellerman AL, Reay DT, et al.** Handgun regulations, crime, assaults, and homicide. A tale of two cities. *N Engl J Med* 1988; 319(19): 1256-1262.
56. **Karlsson T.** Homicidal and suicidal sharp force fatalities in Stockholm, Sweden. Orientation of entrance wounds in stabs gives information in the classification. *Forensic Sci Int* 1998; 93(1): 21-32.
57. **Karlsson T, Ormstad K, Rajs J.** Patterns in sharp force fatalities--a comprehensive forensic medical study: Part 2. Suicidal sharp force injury in the Stockholm area 1972-1984. *J Forensic Sci* 1988; 33(2): 448-461.
58. **La Harpe R, Dozio A.** Economic crisis and suicide in Geneva: 1991-1995. *Arch Kriminol* 1998; 202(3-4): 69-74.
59. **DiMaio D, DiMaio VJM.** Forensic Pathology. 2nd ed. Washington, DC: CRC Press; 2001: 214-215.
60. **Vanezis P, West IE.** Tentative injuries in self stabbing. *Forensic Sci Int* 1983; 21(1): 65-70.
61. **Gill JR, Catanese C.** Sharp injury fatalities in New York City. *J Forensic Sci* 2002; 47(3): 554-557.
62. **Racette S, Kremer C, Desjarlais A, Sauvageau A.** Suicidal and homicidal sharp force injury: a 5-year retrospective comparative study of hesitation marks and defense wounds. *Forensic Sci Med Pathol* 2008; 4(4): 221-227.
63. **Herbst J, Haffner H.** Tentative injuries to exposed skin in a homicide case. *Forensic Sci Int* 1999; 102(2-3): 193-196.
64. **Knight B.** The dynamics of stab wounds. *Forensic Sci* 1975; 6(3): 249-255.
65. **Greggers HE.** Zur Diagnostik der Halsschnittwunden bei Totung durch eigene oder fremde Hand. *Dtsch Z Ges Gerichtl Med* 1932; 19(1): 328-349.
66. **Betz P, Tutsch-Bauer E, Eisenmenger W.** "Tentative" injuries in a homicide. *Am J Forensic Med Pathol* 1995; 16(3): 246-248.

POKYNY PRO AUTORY

Aktuální pokyny pro autory jsou k dispozici na níže uvedených odkazech:

http://www.soudnilekarstvi.cz/wp-content/uploads/2014/04/3-Pokyny-pro-autory.pdf
http://www.soudnilekarstvi.cz/wp-content/uploads/2014/04/3-Instructions-for-Authors.pdf