proLékaře.cz | 29.9.2026



# Right haemothorax related to the rupture of abdominal aortic aneurysm

**Filiz Eren[1], Nursel Türkmen İnanır[2], Bülent Eren[1], Berna Şenel[3], Recep Fedakar[2]**

[1] *Council of Forensic Medicine of Turkey, Bursa Morgue Department*
[2] *Uludağ University Medical Faculty, Forensic Medicine Department, Council of Forensic Medicine of Turkey, Bursa Morgue Department*
[3] *İstanbul University Cerrahpaşa Medical Faculty, Forensic Medicine Department*

**SUMMARY**

Reported case was 63 years old forester died suddenly in the village. Autopsy examination revealed massive coagulated haemorrhage filling the right hemithorax, neither free fluid nor blood were observed in the abdominal cavity. Abdominal aortic aneurysm 20x15x15 cm in size was examined. We aimed to report the rare case of abdominal aortic aneurysm presented with transdiafragmatic rupture and bleeding in the right hemithorax.

**Keywords:** haemothorax – abdominal aortic aneurysm – rupture – autopsy.

## Pravostranný hemothorax z ruptury aneurysmatu abdominální aorty

**SOUHRN**

Úmrtnost související s rupturou aneurysmatu abdominalní aorty je vysoká zejména v pokročilejším věku. Při ruptuře se častěji krev provalí do retroperitonea než do volné dutiny břišní. Prasknutí výdutě do dutiny je doprovázeno šokovými příznaky, jako je dušnost a hypotenze. Transdiaphragmatická ruptura aneurysmatu břišní aorty do dutiny pleurální je vzácně popisovaný jev.
V práci je popisováno úmrtí muže stáří 63 let, který pracoval jako lesník a náhle zemřel při manipulaci s kládami. Vzhledem k tomu, že kriminální policie označila okolnosti smrti jako nejasné, bylo nařízeno provedení pitvy. Při vnitřní prohlídce byl nalezen otok mozku i obou plicních křídel a masivní koagulovaný pravostranný hemothorax. V dutině břišní naopak nebyly známky krvácení vůbec patrné. Bylo nalezeno subdiafragmaticky lokalizované aneurysma břišního úseku aorty velikosti 20 x 15 x 15 cm s trhlinou velikosti 2,5 cm. Dále byla nalezena tlaková atrofie obratlů Th11 a Th12. Histologicky byla na srdci zjištěna fibrosa a ostatní přidružené nálezy korespondující se zhojeným infarktem myokardu. Toxikologické vyšetření bylo kompletně negativní. Jako příčina smrti byl stanoven šok ze zakrvácení dutiny hrudní z ruptury aneurysmatu břišní aorty pronikající cestou hiatus aorticus.

**Klíčová slova:** hemothorax – aneurysma břišní aorty – ruptura – pitva.

*Soud Lek 2016; 61(2): 18-19*

Studies have indicated that mortality is high in case of thoraco-abdominal aneurysm rupture, especially in the elderly cases with different complications (1,2). Transdiaphragmatic, intrathoracic rupture of abdominal aortic aneurysm is rarely reported entity, especially by the Japanese researchers(3,4). In this study we aimed to report and discuss the transdiaphragmatic rupture of abdominal aortic aneurysm from medicolegal point of view.

## CASE REPORT

According to the criminal police investigation records forester man died suddenly during log loading procedure in the village. Death was evaluated as suspicious by prosecutor and autopsy was mandated. The deceased was 168 cm in height, 65 kg in weight, 63 years old man. External examination revealed 5x2 cm echimoses on the right shoulder, injection marks on left antecubital region and 20 cm operation scar on the left lower quadrant of abdomen. During autopsy, 2600 ml coagulated blood was detected in the right hemithorax. There was no free fluid or blood in in the abdominal cavity. On gross examination brain and both lungs were edematous and congested. On the macroscopic examination of the abdominal cavity, subdiaphragmatically located 20x15x15 cm sized mass (Fig. 1), abdominal aortic aneurysm was observed. Ongoing dissection revealed 2.5 cm in diameter defect and opening area of abdominal aneurysm on the right diaphragmatic crus at the hiatus aorticus level (Fig. 2) with right haemothorax, also destruction of T11 vertebrae and corpus fracture in T12 vertebrae formed by pressure effects of aneurysm. Histological examination of the heart revealed fibrosis, findings corresponding to healed myocardial infarction. Analysis of the organ specimens revealed none of the substances screened for systematic toxicological methods. Death was reported as casued by internal bleeding and shock due to the rupture of the abdominal aortic aneurysm.

✉ ***Correspondence address:***
*Bülent Eren, M.D., Associate Professor*
*Council of Forensic Medicine of Turkey*
*Bursa Morgue Department, 16120,*
*Nilüfer, Beşevler, Bursa, Turkey*
*tel.: +90 224 222 03 47, fax: +090 224 225 51 70*
*e-mail: drbulenteren@gmail.com*

## DISCUSSION

Studies on thoracoabdominal aneurysms reported high mortality rates (1,2). Transdiaphragmatic and intrathoracic rupture of abdominal aortic aneurysms are rarely reported entities, especially by the Japanese researchers (3,4). Rupture of aneu-

proLékaře.cz | 29.9.2026

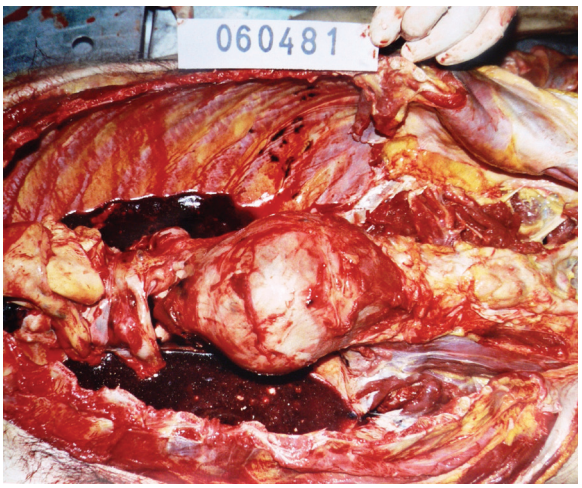


**Fig. 1.** Aneurysm of the abdominal aorta.

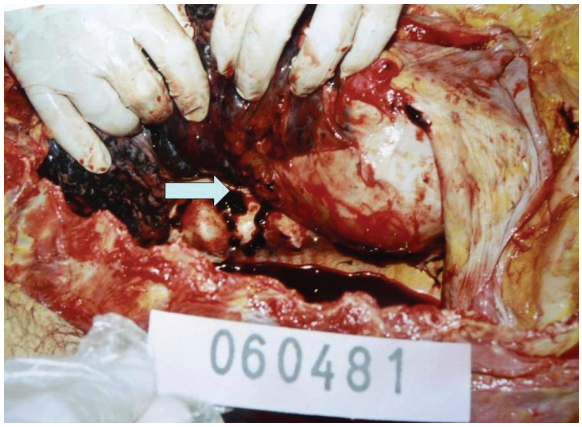


**Fig. 2.** Rupture area on the right diaphragmtic crus.

rysms into an internal cavity, which was accepted between complications of disease were often reported in the elderly as the presented case (1,2,5). Clinical presentation with shock symptoms like dyspnea and hypotension that can guide were noted in medical literature (6), but asymptomatic cases were also published (7). After the sudden development of haemorrhagic shock, detection of bleeding into the thoracic cavity by radiological examination and thoracostomy are commonly reported in the literature (6). Under emergency conditions, especially sudden shock, in patients coming with right sided hemothorax abdominal aortic aneurysm should usually be first to come into the mind, but also (1,3,4,6) can occur in transdiafragmatic rupture of abdominal aortic aneurysm like as in our case, so angiographic assesements should be done immediatelly without delay (5). In the cases with corpus vertebra destruction and fractures due to chronic pressure effect of the aneurysm, development of spinal cord damage, in which symptoms that may interfere with spondylitis findings were also observed in the later periods of desease (8,9). Although majority of patients taking medical treatment have been lost, stent application of aortic aneurysm ruptures, graft replacements, reconstruction operations with a limited number of cases are reported to be successful (1,3,4), with developing new techniques the mortality rate is also lower. Black and friends reported that they have gained successful results in complicated thoracoabdominal aneurysms using endovascular exclusion and visceral revascularisation method (5). Classical symptoms of adult aortic aneurysm rupture can occur at any time or may not be seen by the autopsy findings. For successful approach toward this rare entity, precise physical examination in adults with chest pain complaints, careful radiological investigations of chest space in cases with intrathoracic bleeding, transdiaphragmatic rupture of abdominal aortic aneurysm should be considered between instant causes in the differential diagnoses.

## LITERATURA


1. **Saito T, Akimoto H, Oda M, Yamada M, Tabayashi K.** Successful surgical treatment for acute type A dissecting aneurysm complicated with impending rupture in a thoracoabdominal aortic aneurysm in an octogenarian. *Jpn J Thorac Cardiovasc Surg* 2002; 50: 387-390.
2. **Kotsis T, Scharrer-Pamler R, Kapfer X, et al.** Treatment of thoracoabdominal aortic aneurysms with a combined endovascular treatment of thoracoabdominal aortic aneurysms and surgical approach. *Int Angiol* 2003; 22: 125-133.
3. **Error T, Namba H, Tsushima Y, et al.** A successful surgical case of ruptured into the right pleural cavity thoracoabdominal aortic aneurysm. *Kyobu Geka* 1992; 45: 557-560.
4. **Obayashi T, Anza T, Sakata Y, Tycoon H, Yanagisawa H.** A case of right thoracoabdominal aortic aneurysm ruptured into the extrapleural cavity. *Kyobu Geka* 1990; 43: 924-928.
5. **Black SA, Wolfe JH, Clark M, Hamady M, Cheshire NJ, Jenkins MP.** Complex thoracoabdominal aortic aneurysms: endovascular exclusion with visceral revascularization. *J Vasc Surg* 2006; 43: 1081-1089.
6. **Baharloo F, Verhelst R, Collard P, Pieters T.** Rupture of aortic aneurysm with right-sided haemothorax. *Eur Respir J* 1999; 13: 465-467.
7. **Totaro P, Degno N, Sprini D, Argano V.** Unusual presentation of descending thoracic aortic aneurysm ruptured. *J Cardiovasc Med* 2007; 8: 291-292.
8. **Carruthers R, Sauerbrei E, Gutelius J, Brown P.** Sealed rupture of abdominal aortic aneurysm imitating metastatic carcinoma. *J Vasc Surg* 1986; 4: 529-532.
9. **Sakai T, Katoh S, Sairyo K, Higashino F, Hirohasm N, Yasui N.** Extension of contained rupture of an abdominal aortic aneurysm into a lumbar intervertebral disc. Case report. *J Neurosurg Spine* 2007; 7: 221-226.