proLékaře.cz | 4.10.2026

Death due to peripheral vascular injury following blunt trauma

Eren B.[1], Türkmen N.[2], Erkol Z.[3]

[1] *Council of Forensic Medicine of Turkey, Bursa Morgue Department*
[2] *Uludağ University Medical Faculty, Forensic Medicine Department, Council of Forensic Medicine of Turkey, Bursa Morgue Department*
[3] *Abant Izzet Baysal University Medical Faculty, Forensic Medicine Department, Council of Forensic Medicine of Turkey, Istanbul Turkey*

SUMMARY
According to the document of death, 34-year-old forester sustained a crush injury to his lower extremity and pelvis as was pinned between the wood log and ground. During autopsy intramuscular bleeding was observed in the left pelvic region the left femoral region femur was detected intact there was no fracture, but there was observed a traumatic transection of the common femoral artery and vein, which was accompanied with massive bleeding in the surrounding soft tissues and muscles. We presented rare case of traumatic transection of the common femoral artery and vein in a patient without an femoral fracture caused by blunt trauma.

Keywords: blunt trauma – peripheral vascular injury – autopsy

Smrt v důsledku periferního cévního poranění po tupém traumatu

SOUHRN
Podle dokladu o úmrtí utrpěl 34-letý lesník drtivé poranění dolních končetina pánve, když byl přimáčknut mezi dřevěný kmen a povrch země. Při pitvě bylo zjištěno intramuskulární krvácení do pánevní oblasti vlevo a do levé stehenní krajiny. Kost stehenní byla neporušena, bez zlomeniny, ale bylo zjištěno úrazové přerušení arteria a vena femoralis, které bylo doprovázeno masivním krvácením do okolních měkkých tkání a svalů.
Je prezentován řídký případ úrazového přerušení stehenní tepny a žíly bez zlomeniny kosti stehenní u jedince, který utrpěl tupé poranění.

Klíčová slova: tupé trauma – periferní cévní poranění – pitva

Soud Lek 2012; 57(4): 58–59

Peripheral vascular injuries when exist together with life threatening haemorrhage from a peripheral blood vessel may take initial priority, arterial and venous injuries must be controlled while treating other injuries (1–5). Demonstration of the injured vessel, determination of whether vascular injury is lethal by itself as well as the number, locations and sides of the injuries are important for the assessment of the injury (6).

CASE REPORT

We describe intersting autopsy case of accidental peripheral vascular injury. According to the document of death, during transportation of wood blocks, an wooden log fell from the truck and forester sustained a crush injury to his lower extremity and pelvis as was pinned between the wood log and ground. He was carried to the local hospital and after transported to the regional public hospital where he died in the emergency service. The death was considered to be suspicious by prosecutor and an autopsy was mandated. The case was a 34-year-old man cadaver; he was 180 cm tall and weighed 90 kg. On inspection, there were ecchymotic bruises on left low abdominal wall and the anterior superior iliac spine line, distinctive haematoma, spreading to the lower part of the left femoral region, 10x5 cm ecchymose on right inguinal region, widespread ecchymose on the genitalia, and 3x2 cm ecchymotic abrasion on the right knee, crepitation and deformation under right knee were detected. Subcutaneous haemorrhages were observed in the abdominal wall during autopsy. Intramuscular bleeding without subcutaneous haemorrhage was observed in the left pelvic region. During dissection of the left femoral region femur was detected intact there was no fracture (Figure 1), but there was observed a traumatic transection of the common femoral artery and vein (Figure 2), which was accompanied with massive bleeding in the surrounding soft tissues and muscles. Analysis of the organ specimens revealed none of the substances screened for in systematic toxicological methods. Macroscopic examination of brain, lungs, heart and other internal organs showed paleness. We reported rare case of traumatic transection of the common femoral artery and vein in a patient without an femoral fracture caused by blunt trauma.

DISCUSSION

Developments in vascular surgery, improved general awareness in first aid contributed to the increasing treatment success and de-

✉ ***Correspondence address:***
Dr. Bülent Eren
Council of Forensic Medicine
of Turkey Bursa Morgue Department
Heykel, Osmangazi 16010, Bursa, Turkey
tel.: +90 224 222 03 47, fax: +090 224 225 51 70
e-mail: drbulenteren@gmail.com

proLékaře.cz | 4.10.2026

Figure 1. Dissection of the left femur.

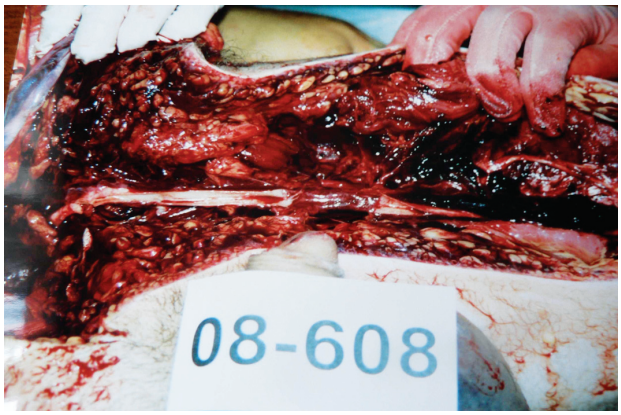

Figure 2. Traumatic transection of the common femoral artery.

creased mortality in extremity vascular injuries (1–6). In such injuries, first aid in the form of direct compression or proximal occlusion followed by expert surgical intervention at the hospital provide the highest chance of success. There is a marked male dominance in peripheral vascular injuries in both hospitalizations as well as autopsy cases (6,7), as was our case. The fact that men are more active in social life and they are more frequent participants in events that set the stage for injury. In the literature, extremity vascular injury patients are generally young adults (6). Studies on hospitalized patients as well as autopsy series in our country showed that the most frequent mechanism of injury was a stab wound followed by gunshot wounds (6,7). In different study from Georgia (8), 87 % of the cases were due to penetrating trauma and 13 % were due to blunt trauma. In Pakistan 54 % of the presented cases were due to gunshot wounds, 18 % due to blunt trauma and 12 % due to stab wounds (9). In England (10), 46% of the lower extremity vascular injury cases were due to gunshots, 19% due to blunt trauma and 12 % due to stab wounds. In lethal extremity vascular injuries, the critical wound is usually in the lower extremity. This may be due to the large area and volume of the lower extremities, the larger size of the vessels in the lower extremities, the relative immobility of the lower extremities during injury, the selection of the lower extremity in injuries without intention to kill but subsequent death due vascular injury and on the contrary intentional targeting of the groin region. As in similar studies (1–10), the left lower extremity was the most frequently injured extremity as in the present series. The mechanism of injury following blunt trauma of the extremities was fracture or dislocation, acute traction on the extremity and contusion. Common findings were complete arterial disruption, intimal or intimal and medial tears. Because the lower extremity was more frequently involved, the lower extremity vessels more specifically the femoral artery and its branches were the most frequently injured vessels. This due to its large size and length. It was followed by the femoral vein which is adjacent to the artery. Similar studies were obtained in other studies (1,3,9–11). Demonstration of the injured vessel, determination of whether it is lethal by itself as well as the number, locations and side of the injuries are important for the assessment of the intention to kill or to injure (1,2). Accidents were the most common initiating events reported as a cause of blunt peripheral vascular injuries. In the absence of a potentially lethal injury at some other location, death caused by extremity injury is possible due to major vascular injury. The studies on cases in medicolegal series showed that the most frequent mechanism of injury was a stab wound followed by gunshot wounds and blunt trauma. The following report demonstrates rare case of traumatic transection of the common femoral artery and vein in a patient without an femoral fracture caused by blunt trauma.

REFERENCES

1. **Nalbandian MM, Maldonado TS, Cushman J, Jacobowitz GJ, Lamparello PJ, Riles TS.** Successful limb reperfusion using prolonged intravascular shunting in a case of an unstable trauma patient. A case report. *Vasc Endovascular Surg* 2004; 38: 375–379.
2. **Rich NM, Hobson RW, Fedde CW, Collins GJ.** Acute common femoral arterial trauma. *J Trauma* 1975; 15: 628–637.
3. **Martin LC, McKenney MG, Sosa JL, et al.** Management of lower extremity arterial trauma. *J Trauma* 1994; 37591–37598.
4. **Cargile JS 3rd, Hunt JL, Purdue GF.** Acute trauma of the femoral artery and vein. *J Trauma* 1992; 32: 364–370.
5. **Sturm JT, Bodily KC, Rothenberger DA, Perry JF Jr.** Arterial injuries of the extremities following blunt trauma. *J Trauma* 1980; 20: 933–936.
6. **Turkmen N, Fedakar R, Eren B, Saka NE.** Deaths related to vessel injuries in extremities. *The Bulletin of Legal Medicine* 2003; 8: 78–81.
7. **Erturk S, Ege B, Karali H.** Retrospective evaluation of 94 vascular injury autopsy cases. *Journal of Forensic Medicine* 1990; 6: 181–186.
8. **Razmadze A.** Vascular injuries of the limbs: a fifteen-year Georgian experience. *Eur J Endovasc Surg* 1999; 18: 235–239.
9. **Guraya SY.** Extremity vascular trauma in Pakistan. *Saudi Med J* 2004; 25: 498–501.
10. **Hafez HM, Woolgar J, Robbs JV.** Lower extremity arterial: Results of 550 cases and review of risk ractors associated with limb loss. *Journal of Vascular Surgery* 2000; 33: 212–219.
11. **Cihan HB, Gulcan O, Hazar A, Turkoz R.** Peripheral Vascular Injuries. *Ulusal Travma Derg* 2001; 7: 113–116.