proLékaře.cz | 29.9.2026

Study of morphological changes in the skin of the neck in suicidal cases by hanging

Angel Fernandez-Flores[1], Oliva Orduña[2], Veronica Carranza[2]

[1] *Service of Cellular Pathology, Clinica Ponferrada. Ponferrada, Spain.*
[2] *Legal Medicine Institute of Leon and Zamora, Ponferrada, Spain*

SUMMARY

Purpose: the morphologic changes in specimens from people who have committed suicide by hanging have mainly centered on macroscopic findings. Pour purpose is to inestigate the microscopis changes in the ligature marks.
Methods: we report the histopathologic features of the ligature mark on the neck of three people who committed suicide by hanging themselves.
Results: the main finding was coagulative necrosis of all cutaneous layers and the subjacent striated muscle. In the areas close to the ligature, blood vessels appeared congestive with a mild inflammatory perivasculary infiltrate. In some other areas, we found preserved sebaceous and eccrine glands, underneath the epidermis with marked necrotic changes.
Conclusions: These findings suggest that neither pressure nor hypoxia is enough to induce necrosis in cutaneous adnexa.

Keywords: hanging – ligature mark – coma necrosis

Morfologické změny v kůži krku u osob, které spáchaly sebevraždu oběšením

SOUHRN

U osob, které spáchaly sebevraždu oběšením, bylo většinou sledování morfologických změn zaměřeno převážně na makroskopické nálezy v místě rýhy od škrtidla.
Seznamujeme s charakteristickými histopatologickými nálezy strangulační rýhy na šíji u třech jedinců, kteř spáchali sebevraždu oběšením. K hlavním nálezům patří koagulační nekróza celé vrstvy kůže a přiléhajících příčně pruhovaných svalů. V oblasti uzavřené škrtidlem je v cévách patrné městnání krve s mírným zánětlivým perivaskuárním infiltrátem. Mazové a ekrinní žlazky zůstávají zachovalé. Tyto nálezy naznačují, že ani tlak ani hypoxie nejsou dostatečné, aby způsobily nekrózu kožních adnex.

Klíčová slova: oběšení – strangulační rýha – koagulační nekróza

Soud Lek 2011; 56(2): 24–26

INTRODUCTION

The morphologic changes in specimens from people who have committed suicide by hanging have mainly centered on macroscopic findings. Some histopathologic studies have focused on the morphology of internal organs such as large vessels and muscles of the neck area. Not many studies on the cutaneous changes of the ligature mark have been published. In one of them (1), the authors studied such changes in people who died several weeks after the suicidal attempt, so the main histopathologic feature was chronic inflammation with granulation tissue.

We have histopathologically studied the cutaneous changes of the ligature mark of three cases of suicide by hanging from people who died immediately after the attempt.

✉ ***Correspondence address:***
Angel Fernandez-Flores, M.D., Ph.D.
S. Patología Celular, Clinica Ponferrada
Avenida Galicia 1, 24400 Ponferrada, Spain
Tel.: (00 34) 987 42 37 32
Fax: (00 34) 987 42 91 02
e-mail: gpyauflowerlion@terra.es

DESCRIPTION OF THE CASES

Case 1

An 86-year-old man was found at home, hanging by a rope. The face had a bluish tone and after removing the rope, a depressed supraglotic mark was evidenced (Fig. 1, left).

The autopsy revealed a fracture of the hyoid bone (right greater and lesser cornu, as well as left lesser cornu). The internal organs were generally congestive, but no other pathology was found. The study for toxics and drugs was negative. The final determination from the coroner was suicide.

The microscopic study of the supraglotic depression showed compression of all the layers of the skin, as well as of the subjacent striated muscle (Fig. 2). At this level, the structures were necrotic, with preservation of the shapes of the adnexa but with loss of the definition of the cellular details (Fig. 3). In some areas, we could see how sebaceous glands, as well as sudoripary ducts were preserved underneath areas of necrotic dermis and epidermis (Fig. 4). The preserved immediate adjacent dermis showed congestive blood vessels with mild inflammatory perivascular infiltrate (Fig. 5).

Case 2

A 40-year-old woman, who was under psychiatric treatment,

proLékaře.cz | 29.9.2026

was found dead at home, hanging from a sheet that surrounded her neck. After removing the sheet, the neck presented a lineal depression. The necropsy evidenced fracture of the left lesser cornu of the hyoid. There were also general anoxic organic alterations, with no other pathology. The study for toxics and drugs was negative. The autopsy from the coroner determined suicide.

A sample from the depressed area of the cutaneous lesion of the neck was morphologically studied. It showed compression of all the layers of the skin, as well as of the subjacent striated muscle. Necrosis of the adnexa was evidenced, including sudoripary glands, as well as the pilosebaceous unit (Fig. 6). The dermis close to the necrotic area showed dilated blood vessels with mild inflammatory chronic perivascular infiltrate.

Case 3

A 25-year-old woman was found at home, hanging from the ceiling, with a rope around her neck. The depression under the rope showed vital signs. The depressed area reached the submaxillary area. Both sternocleidomastoid muscles showed albus line. The left jugular vein showed Otto sign (internal jugular wall torn) and the left carotid artery presented Amussat sign (internal carotid wall torn). No signs of violence were found and the coroner's autopsy determined suicide. The study for toxics and drugs was negative.

A sample from the cutaneous wrinkle in the middle part of the neck was histopathologically studied (Fig. 1, right). Coagulative necrosis

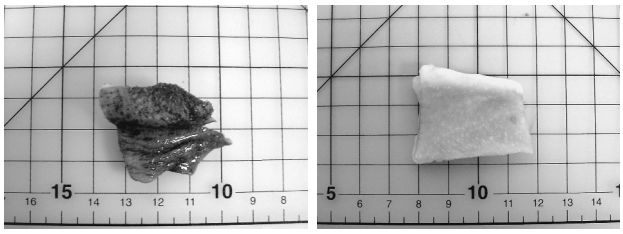

Fig. 1. *Left:* Sample of the neck of case 1 that was sent for histo-pathologic study. A prominent ligature mark can be observed. *Right:* Macroscopic view of the ligature mark from case 3.

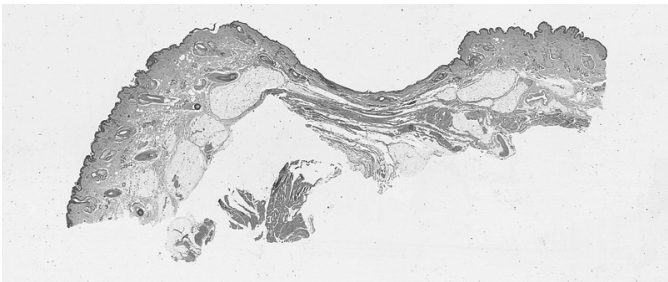

Fig. 2. Low power view of a cross section of case 1. The ligature mark can be seen in the center, with remarkable compression of all the layers of the sample.

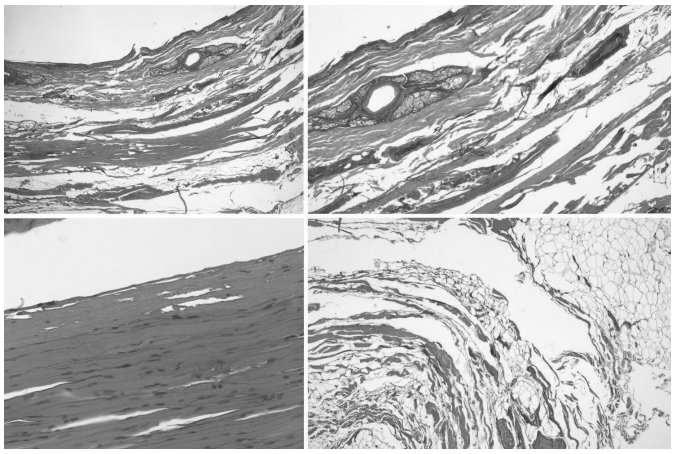

Fig. 3. Images from case 1, showing coagulative necrosis of all layers, including epidermis and dermis (top), hypodermis (bottom right) and striated muscle (bottom left). Sebaceous glands were also necrotic at this level.

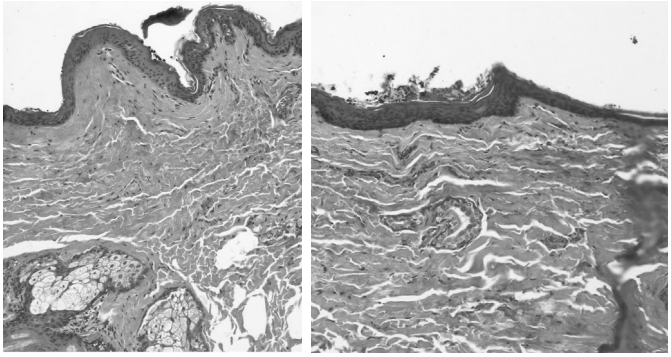

Fig. 4. In some areas, preserved sebaceous glands were observed under necrotic epidermis areas.

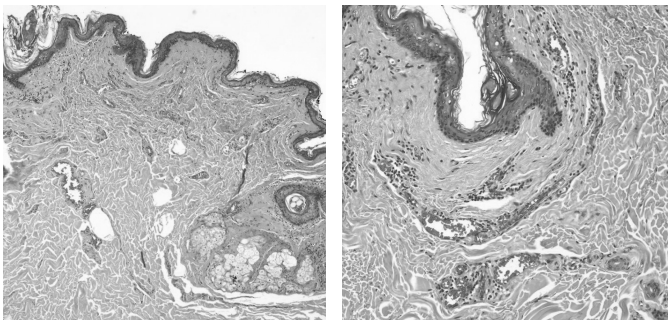

Fig. 5. In areas close to the ligature mark, congestive vessels and mild perivasculary inflammatory infiltrate were observed.

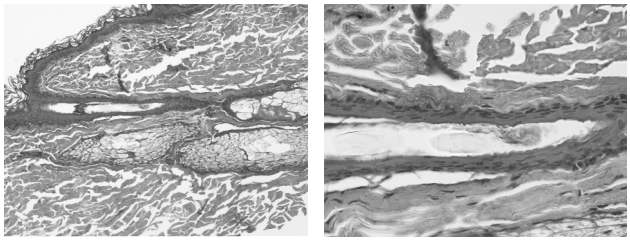

Fig. 6. Necrotic adnexa at the ligature mark from case 2.

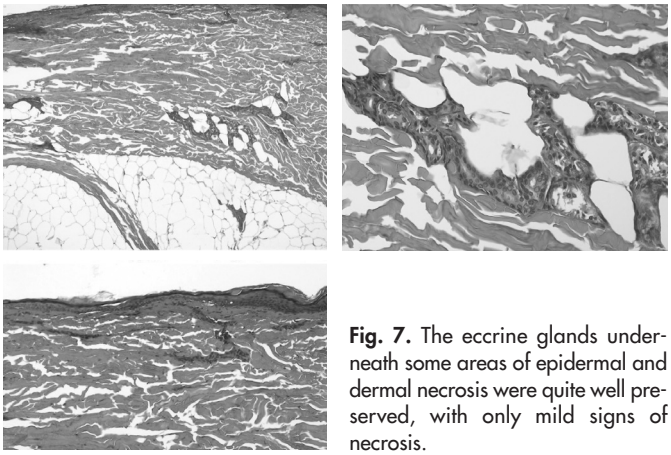

Fig. 7. The eccrine glands underneath some areas of epidermal and dermal necrosis were quite well preserved, with only mild signs of necrosis.

proLékaře.cz | 29.9.2026

of the epidermis, dermis, hypodermis and striated muscle, was seen. Under the areas of necrotic epidermis, we found some sudoripary glands which were only mildly involved by the compression, and did not appear necrotic (Fig. 7). The dermis showed dilated blood vessels with mild inflammatory chronic perivasculary infiltrate.

DISCUSSION

The macroscopic findings of the ligature mark(s) in the neck of people who have committed suicide by hanging themselves, have been previously described in literature (2). However, the microscopic features of such lesions have rarely been reported (1,3). Even so, most of the histopathologic studies have centered on the morphologic changes of the internal structure, such as vessels (Amussat and Otto signs) (4). The dermal changes are less frequently described. In the report by Vock et al., two cases were presented, and while granulation tissue was described in one, a normal corion was evidenced in the other (1). In both cases, death occurred approximately a month after the suicidal attempt. The reason why in one case the granulation tissue was formed and not in the other was, according to the authors, the difference in the degree of strangulation. Our report includes a microscopic study of three cases in which suicidal death was the immediate result from hanging. In that respect, this contains information never published before, to the best of our knowledge.

The changes observed by us were typical of an extreme ischemic area of skin with infarcted zones. We did not see signs typical of burns, although rope burns are sometimes associated to the ligature mark. When the latter are present, they have forensic value, since they indicate an antemortem nature of hanging (2). Such an abrasion is due to compression (5). A different meaning can be attributed to the bullous changes of the skin as well as to the ridge ecchymoses which can be found between the ligature burns. Although once thought to be an antemorten sign, we now know they can appear as a post mortem sign (6).

From a histopathologic point of view, the inflammatory infiltrate at the compressed area, is considered as a premortem sign (3). We saw a mild perivascular inflammatory infiltrate in the 3 cases, but it was seen in the non-necrotic dermis.

In our study, we could see sebaceous glands as well as sudoripary ducts, which appeared preserved underneath the necrotic dermis and hypodermis. This contrasts with the findings in the cutaneous lesions of coma, where the eccrine seat coil, as well as the sweat duct and the sebaceous glands appear necrotic (7–11). Pressure and hypoxia have been considered in literature as determinant factors in cutaneous necrosis due to coma (10), and it was once emphasized how the lesions were more commonly found on pressure areas, such as the extremities and trunk (12). Moreover, similar lesions are found in patients with generalized hypoxia due to carbon monoxide intoxication (13). Nevertheless, such a claim has not been consensus, and others have suggested how other factors could be responsible (8). Certain facts supporting this latter option are that coma-lesions also appear in non-pressure areas. Also, the eruption is sometimes widespread and distributed in an irregular pattern (8).

Moreover, the outer layer of the eccrine duct is more metabolically active than the inner one, but nevertheless, the latter is altered earlier in the necrosis due to coma than the former (8). Even in cutaneous changes in non-drug-induced coma, alterations in the eccrine glands are seen (13,14), and an immunologic pathogenesis has been suggested for this (15). Our study is a good model for observing the changes which are present in extreme pressure and hypoxia located on a specific area of the skin. Since differences with the changes in coma-lesions are obvious, this supports the claim that other factors contribute to the changes seen in coma-induced cutaneous alterations.

CONCLUSIONS

The microscopic features of ligature marks from sucide cases from hanging were mainly coagulative necrosis of the epidermis, dermis, hypodermis and striated muscle.

Some adnexal glands were only mildly involved by the compression, and did not appear necrotic.

Neither pressure nor hypoxia are enough to induce necrosis in cutaneous adnexa.

The epidermis and superficial dermis are damaged in some areas earlier than the subjacent adnexal when pressure on the skin is extreme and constant.

The sequence of events in necrosis, due to external mechanical pressure, seems different to the one seen in coma-induced necrosis, as some have already suggested (8).

REFERENCES

1. **Vock R, Müller V.** Macro- and microscopic findings of cord marks in 2 cases of delayed death by hanging. *Z Rechtsmed* 1987; 99: 211–218.
2. **Mohanty MK, Rastogi P, Kumar GP, Kumar V, Manipady S.** Periligature injuries in hanging. *J Clin Forensic Med* 2003; 10: 255–258.
3. **Concheiro Carro L, Suarez Peñaranda JM.** Asfixias mecánicas. In: **Villanueva Cañadas E,** ed. Medicina legal y Toxicológica de Gisbert Calabuig. Barcelona: Masson SA; 2004: 460–479.
4. **Sibón Olano A, Martínez-García P, Palacios Granero RJ, Romero Palaco JL.** Muerte por ahorcadura. *Cuad Med Forense* 2005; 11: 145–149.
5. **Doichinov ID, Doichinova Y, Spasov SS, Marinov ND.** Suicide by unusual manner of hanging. A case report. *Folia Med (Plovdiv)* 2008; 50: 60–62.
6. **Pollak S, Mortinger H.** Findings intermediate ridges of strangulation marks and their value as signs of vitality. *Arch Kriminol* 1985; 175: 85–94.
7. **Hasson A, Gutiérrez MC, Arias D, et al.** Necrosis epitelialcutánea en el coma: a propósito de dos casos. *Rev Clin Esp* 1991; 189: 115–119.
8. **Sánchez Yus E, Requena L, Simón P.** Histopathology of cutaneous changes in drug-induced coma. *Am J Dermatopathol* 1993; 15: 208–216.
9. **Setterfield JF, Robinson R, MacDonald D, Calonje E.** Coma-induced bullae and sweat gland necrosis following clobazam, *Clin Exp Dermatol* 2000; 25: 215–218.
10. **Miyamoto T, Ikehara A, Kobayashi T, Kitada S, Hagari Y, Mihara M.** Cutaneous eruptions in coma patients with nontraumatic rhabdomyolysis. *Dermatology* 2001; 203: 233–237.
11. **Tsokos M, Sperhake JP.** Coma blisters in a case of fatal theophylline intoxication. *Am J Forensic Med Pathol* 2002; 23: 292–294.
12. **Wenzel FG, Horn TD.** Nonneoplastic disorders of the eccrine glands. *J Am Acad Dermatol* 1998; 38: 1–17.
13. **Torne R, Soyer HP, Leb G, Kerl H.** Skin lesions in carbon monoxide intoxication. *Dermatologica* 1991; 183: 212–215.
14. **Kim KJ, Suh HS, Choi JH, Sung KJ, Moon KC, Koh JK.** Two cases of coma-associated bulla with eccrine gland necrosis in patients without drug intoxication. *Acta Derm Venereol* 2002; 82: 378–380.
15. **Kato N, Ueno H, Mimura M.** Histopathology of cutaneous changes in non-drug-induced coma. *Am J Dermatopathol* 1996; 18: 344–350.