

Multilocular infection caused by hypervirulent *Klebsiella pneumoniae*

Tyll T.¹, Novotný D.¹, Beran O.², Bartáková E.³, Pudil J.⁴, Králová Lesná I.^{1,5}, Rára A.¹

¹Department of Anaesthesiology, Resuscitation and Intensive Care Medicine, 1st Faculty of Medicine of Charles University and Military University Hospital Prague

²Department of Infectious Diseases, 1st Faculty of Medicine of Charles University and Military University Hospital Prague

³Department of Microbiology, Military University Hospital Prague

⁴Department of Surgery, 2nd Faculty of Medicine, Charles University and Military University Hospital Prague

⁵Experimental Medicine Centrum, Institute for Clinical and Experimental Medicine, Prague

ABSTRACT

Hypervirulent strains of *Klebsiella pneumoniae* (hvKP) can cause atypical multilocular infections in otherwise healthy patients. Diagnosis of infection caused by hvKP is based mainly on clinical findings and laboratory results, including detection of virulence genes. It typically manifests as hepatic abscess with metastatic spread. Treatment is based on surgical intervention in combination with targeted antimicrobial therapy. The occurrence of hvKP infection is relatively common in Asia, and while still rare in Europe, incidence is increasing. The article aims to provide a short overview of the issue and increase awareness of the possible occurrence of hvKP infections.

KEY WORDS

hypervirulent – *Klebsiella pneumoniae* – soft tissue infection – sepsis – amputation

SOUHRN

Tyll T., Novotný D., Beran O., Bartáková E., Pudil J., Králová Lesná I., Rára A.: Multilokulární infekce způsobené hypervirulentní *Klebsiella pneumoniae*

Hypervirulentní kmeny *Klebsiella pneumoniae* (hvKP) mohou způsobovat atypické multilokulární infekce u jinak zdravých pacientů. Diagnostika infekce vyvolané hvKP je založena především na klinickém nálezů a laboratorních výsledcích včetně detekce genů virulence. Typicky se projevuje jako jaterní absces s metastatickým šířením. Léčba je založena na chirurgickém řešení v kombinaci s cílenou antimikrobiální terapií. Výskyt infekce hvKP je relativně častý v Asii. V Evropě je sice stále vzácný, ale incidence onemocnění se zvyšuje. Cílem článku je poskytnout stručný přehled problematiky a upozornit na možný výskyt infekcí hvKP.

KLÍČOVÁ SLOVA

hypervirulentní kmen – *Klebsiella pneumoniae* – infekce měkkých tkání – sepse – amputace

Epidemiol Mikrobiol Imunol, 2023;72(1):54–58

INTRODUCTION

Klebsiella pneumoniae (KP) is a species of Gram-negative, non-spore-forming, encapsulated, facultative anaerobic bacteria, a member of the *Enterobacterales* order. KP is a common component of the human and animal gut microbiome and is an opportunistic pathogen. Transmission is by the faecal-oral route or by direct contact. Community strains of KP are usually sensitive to common antibiotics such as aminopenicillins with beta-lactamase inhibitors. Antibiotic resistance is, however, becoming more common [1, 2].

Two main pathotypes have been described – classic (cKP) and hypervirulent (hvKP) *Klebsiella pneumoniae* [2, 3, 4]. Classic KP is typically associated with nosoco-

mial infections in elderly and immunocompromised patients. KP infections are usually unilocular and may be polymicrobial – other microbial strains are often isolated at the same time. Possible manifestations include hospital-acquired pneumonia, urinary tract infections, soft tissue infections and wound infections. In contrast, hvKP is found in community-acquired infections even in young and healthy patients (more commonly in Asian and Hispanic populations). Infections may be multilocular and hvKP is usually the sole cultivated microbe. It typically manifests as hepatic abscess with hematogenic dissemination. Less common infections include endophthalmitis, meningitis, brain abscess, fasciitis and splenic abscess [2]. Hematogenic dissemination is rare for other *Enterobacterales* species [2, 5].

Invasive infections associated with hvKP have been described since the 1980s, mostly in Asia, but globalisation is causing the pathotype to gradually spread worldwide [2]. The reported frequency of hvKP among all KP strains varies depending on location, the methods used in the respective studies, and the particular combination of virulence factors examined. In China hvKP prevalence ranges from 3 to 68%, while in the USA it is under 10% [2]. In France, a combination of mucoid phenotype and aerobactin was identified in only 2% of samples [6] and in another European study colibactin was traced in 3.5% of KP isolates [7].

The degree of pathogenicity is dependent on the presence of numerous virulence factors, which have a role in adherence, colonisation, invasion and development of infection. These factors include, for example, capsulation, siderophores, lipopolysaccharides and fimbriae. One of the most important virulence factors is the formation of a polysaccharide capsule. Among the 79 capsular stereotypes, K1 and K2 are associated with hvKP and severe disease in humans [8]. The regulator of the mucoid phenotype regulates polysaccharide synthesis, which enhances capsule formation by hvKP. The uridine diphosphate galacturonate 4-epimerase (*uge*) gene regulates the synthesis of lipopolysaccharides which protect bacteria from complement-mediated lysis. Siderophores such as yersinibactin or enterobactin enable bacteria to steal iron from host iron-chelating proteins, helping the bacteria to overcome neutralisation by the host [3].

Due to the number of factors that contribute to pathogenicity, a precise definition of hvKP has not yet been established. Clinical presentation is usually combined with microbiological genetic examination to make the diagnosis [2]. A specific recommendation regarding the suitable spectrum of virulence genes to be examined has not yet been published, leading to significant differences in the methods used in published studies [2, 3, 4, 6, 7].

Risk factors for hvKP infection have not yet been thoroughly investigated, but might include ethnicity (Asian, Pacific Islander) with a possible contribution of genetic factors, male sex, immunoglobulin deficiencies and prior treatment with ampicillin or proton pump inhibitors [2]. Poorly controlled diabetes increases the risk for metastatic spread of hvKP infections [8]. Treatment is dependent on controlling the source of the infection, combining surgical intervention with antimicrobial therapy. Due to a lack of published data comparing treatment protocols, an individualized approach is necessary. In the case of abscess formation, percutaneous drainage or open surgical evacuation should be considered, with an emphasis on rapid surgical intervention in the case of infections in high-risk locations (e.g. brain or epidural space), ruptured abscesses, or necrotising fasciitis [2].

To illustrate the clinical implications of hvKP infection, we present a case of a generalised invasive soft tissue

infection with a complicated disease course. A 45-year-old Indonesian male who had been living in central Europe for 2 years was admitted to the hospital with an extensive phlegmon of the pelvis which engulfed the rectum and prostate and spread to the perineum. Contrast CT did not reveal the source of infection, empiric antibiotic therapy was initiated (amoxicillin with clavulanic acid) and trans-perineal drainage was performed. Microbiological examination found a strain of *Klebsiella pneumoniae* sensitive to the administered antibiotics. This therapy led to improvement of the patient's clinical condition and laboratory findings, and the patient was subsequently discharged.

18 days later, the patient presented with a purulent fistula in the armpit, and simultaneous development of systemic signs of infection. Antibiotics were administered (piperacillin/tazobactam) and extensive incision and counterincision were performed. Approximately 1 litre of pus was evacuated from the arm (Figure 1) which was positive for a strain of KP with sensitivity to a range of antibiotics, including piperacillin/tazobactam (Table 1). Septic shock with multiorgan failure developed perioperatively. The infection began to spread to the chest wall and was associated with unilateral flail thorax. Furthermore, bilateral mastoiditis positive for KP was diagnosed.

A CT scan with contrast showed a persisting abscess in the pelvis which was communicating with the rectum (Figure 2), and an axial colostomy was performed. In spite of 4 weeks of targeted antibiotic therapy and surgical treatment (including a left-side mastoidectomy and right-side tympanostomy), KP was repeatedly cultivated from the wounds, moreover, it began producing extended spectrum β -lactamases. This led to a change of antibiotic treatment to meropenem. The course was also complicated by respiratory (*Serratia marcescens*) and urinary tract infection (*Enterococcus faecium*, *Candida tropicalis*) which were treated by targeted antibiotic therapy with cefotaxim, linezolid, anidulafungin and fluconazole.

Treatment eventually led to improvement in the overall condition of the patient. However, he remained dependent on ventilatory support, the wound surfaces did not heal nor produce granulation tissue and function of the hand was severely restricted (see Figure 1). The patient continued to be in a catabolic state and, finally, trans-humeral amputation of the affected limb was performed with the patient's consent. After the amputation, the patient's condition improved, antibiotic therapy was discontinued, and he was successfully weaned off from ventilatory support. Rehabilitation and realimentation were continued and the amputation stump healed completely in one month. Before repatriation to home care in Indonesia, the patient was able to walk without support and had adequate peroral nutrition. The overall length of hospital stay was 148 days, of which 67 were spent in the ICU.

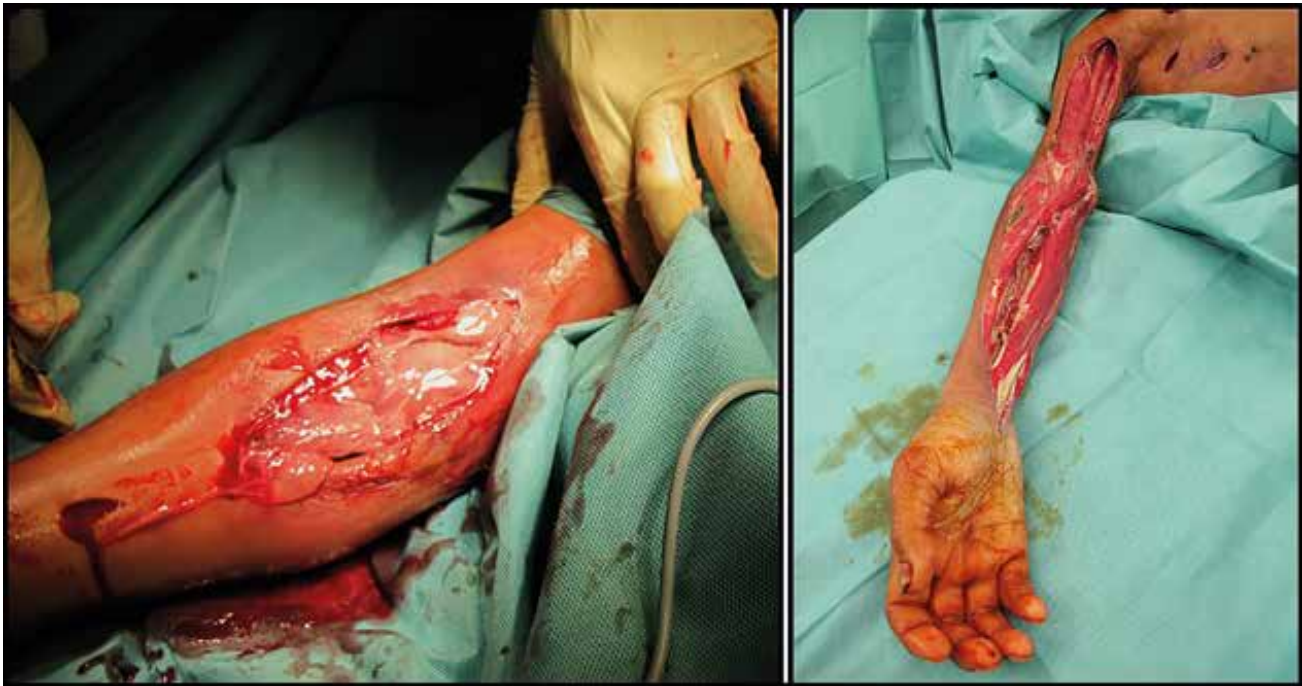


Figure 1. Perioperative photograph of the tissues on the day of the second hospital admission (left) and during one of the final dressings before the transhumeral amputation (right)

Table 1. Antibiotic sensitivity of *Klebsiella pneumoniae* strains in the course of hospitalisation

<i>Klebsiella pneumoniae</i> , selected findings		
Antibiotic sensitivity was assessed using minimal inhibitory concentration test (VITEK® 2, bioMérieux, Marcy-l'Étoile, France)		
Time of sampling	Sampling site	Antibiotic sensitivity
First admission	Perianal abscess	Sensitive to: AMC, COT, CIP, CTX, GEN, AMI, MER, PPT
ICU admission	Haemoculture (antibiogram identical to right arm findings)	Sensitive to: AMC, COT, CIP, CTX, GEN, AMI, MER, PPT CRX, CXT, CPM, CTZ, IMI, ERT, COL (Note: antibiotics in the second line were not test the first time, panel broadened for nosocomial infections)
ICU before amputation	Right arm	Sensitive to: MER, IMI, ERT, COL
Time of sampling	Sampling site	Virulence genes
ICU admission	Haemoculture	Positive: iucA (aerobactin), iroB (salmochelin), peg-344 (putative transporter), prmpA (regulator of the mucoid phenotype), ybtS (yersiniabactin), uge (capsule lipoprotein), mrkD (adhesin type 3 fimbriae) Negative: K1, K2 (capsular stereotypes), clbA (colibactin)

AMC = Amoxicillin-clavulanate, CRX = cefuroxime, CXT = ceftazidime, CPM = cefepime, CTX = cefotaxime, CTZ = ceftazidime, MER = meropenem, IMI = imipenem, ERT = ertapenem, PPT = piperacillin-tazobactam, CIP = ciprofloxacin, GEN = gentamycin, AMI = amikacin, COT = co-trimoxazole, COL = colistin

The microbiological findings are summarized in Table 1. Further analysis of the isolate from haemoculture were conducted at the Department of Public Health of Masaryk University in Brno. To assess the presence of virulence genes, bacterial DNA was extracted from the sample by the boiling lysis method. KP isolates were confirmed by multiplex polymerase chain reaction (PCR) and subsequently, PCR was used to diagnose the presence of individual virulence genes. The products of the PCR were detected via

electrophoresis on 2% agarose gel. This examination revealed positivity for 7 out of 9 investigated virulence genes (Table 1). The results enable definition of the strain as hypervirulent in combination with the clinical course of the illness. A combination of such a number of virulence genes is rare – in a study of 10 virulence factors (partially different from the ones investigated by our laboratory), only 1.4 % of isolates had 7 or more positive factors. Table 2 describes the development of selected

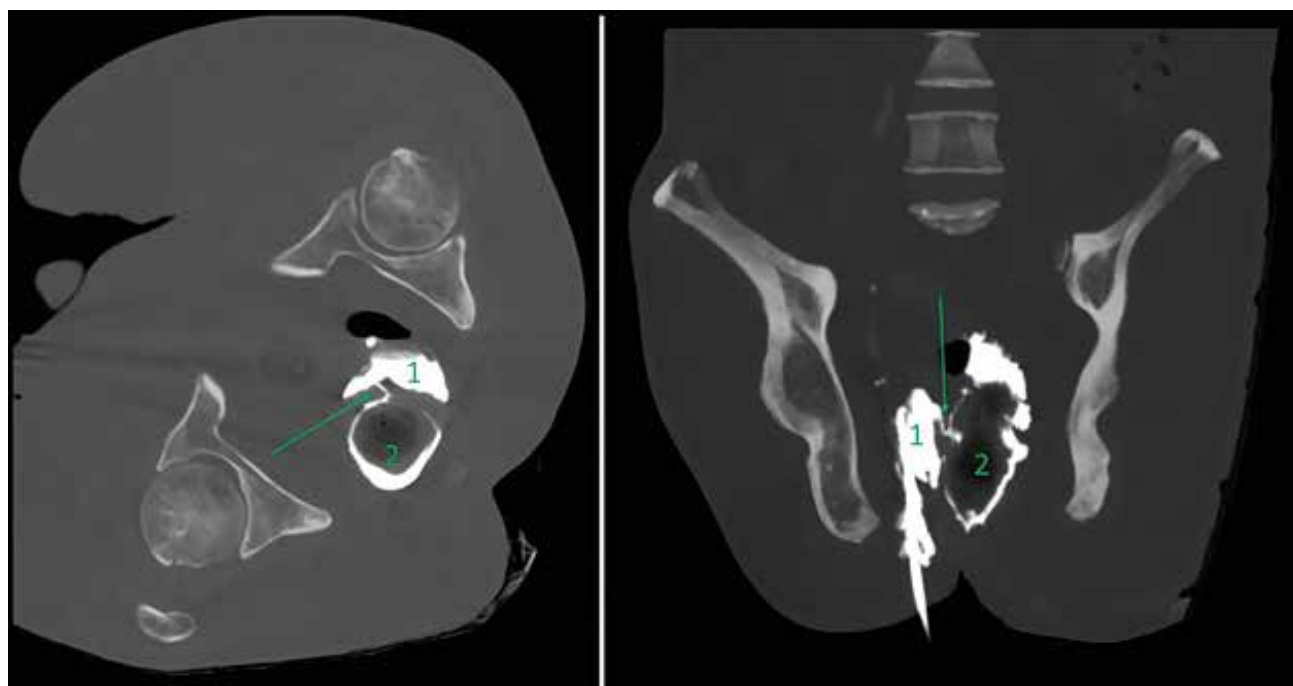


Figure 2. CT scan of pelvis with contrast revealing the fistula (marked with a green arrow) between the perirectal abscess (1) and rectum (2)
Axial plane – left, coronal plane – right.

Table 2. Overview of selected laboratory findings

	Perineal infection admission	Discharge	Arm infection admission	ICU transfer	Transfer to long term care
White blood cells [$\times 10^9/l$]	25.2	9.7	21.7	7.8	8.2
Haemoglobin [g/l]	86	91	85	81	112
Thrombocytes [$\times 10^9/l$]	311	454	61	14	244
Glycaemia [mmol/l]	9.5	7.8	30.5	compensated (5–10)	slightly decompensated (4–16)
CRP [mg/l]	203	16	169	217	9.7
Procalcitonin [$\mu g/l$]	0.167	N/A	N/A	0.86 (2 days later)	0.297 (several days before)

laboratory findings from the patient over the course of hospitalization. Supplementary immunologic examination did not reveal any significant deficiencies of cellular immunity.

DISCUSSION

Infections caused by hypervirulent *Klebsiella pneumoniae* are an emerging phenomenon in Europe. As

opposed to classic KP infections, hvKP tends to cause multilocular infections that can be life-threatening even in otherwise healthy patients. Therefore, it is advisable to consider hvKP as an etiological agent in similar clinical scenarios and strive for early confirmation.

We assume that our patient was a carrier of hvKP as a part of his intestinal flora. The cause of the rectal defect was not confirmed, but it was likely a complication of diverticulitis. A crucial part of treatment is controlling the source of infection. This was supported

by our experience. As was shown by the course of the disease, initial improvement after surgical intervention and 10 days of antibiotic therapy during the first hospital stay did not imply complete healing of the primary focus in the pelvis, even though the recommended duration of treatment was met [9]. A series of case studies have demonstrated the effectiveness of local antibiotic therapy in cases of hvKP [10]. The uncontrollable soft tissue infection of the arm then became a persistent source of the bacteria, enabling spread to the thorax and haematogenous metastasis.

The metastatic potential of hvKP may be increased in poorly compensated diabetes mellitus [8]. Our patient did suffer from Latent Autoimmune Diabetes in Adults (LADA), and while hyperglycaemic on initial assessment, we do not suspect a significant influence of diabetes in the overall course of the disease, due to patient's good long-term compensation.

Throughout the course of the hospital stay, the microbial findings revealed increasing antibiotic resistance of KP. We suspect that the original strain acquired multi-resistance via gene exchange with other nosocomial bacteria or by mutations, which is frequently observed during prolonged antibiotic treatment. Replacement of the original hypervirulent strain with a nosocomial multi-resistant KP strain is another explanation, but considering the course of the disease, we do not find it very probable. Repeated genetic typing of the bacteria would not have changed the treatment plan, therefore it was done only from a single specimen of KP-positive haemoculture.

Amputation of the affected arm marked a turn in the course of the disease. Amputation of a dominant arm is a disabling procedure the indication of which is, of course, difficult for the physician. The surgical team considered amputation early in the course, but the delay was justified by the initial partial improvement of the patient's condition and subsequent efforts to save the limb. The initial progress of the disease was surely aggravated by a significant language barrier, as the patient hesitated to come in for early check-ups when his clinical condition worsened.

CONCLUSION

Infections caused by hypervirulent *Klebsiella pneumoniae* are still rare in central Europe. However, in cases of an atypical location (including multifocal) or course of KP infection, especially in patients from Asia, it is

appropriate to consider hvKP. After the identification of the pathotype, it is crucial to treat the patient thoroughly, complexly, and sufficiently aggressively.

REFERENCES

1. Navon-Venezia S, Kondratyeva K, Carattoli A. *Klebsiella pneumoniae*: a major worldwide source and shuttle for antibiotic resistance. *FEMS Microbiol Rev*, 2017;41(3):252–275.
2. Russo TA, Marr CM. Hypervirulent *Klebsiella pneumoniae*. *Clin Microbiol Rev*, 2019;32(3): e00001–19.
3. Remya PA, Shanthi M, Sekar U. Characterisation of virulence genes associated with pathogenicity in *Klebsiella pneumoniae*. *Indian J Med Microbiol*, 2019;37(2):210–218.
4. Wang G, Zhao G, Chao X, Xie L, Wang H. The Characteristic of Virulence, Biofilm and Antibiotic Resistance of *Klebsiella pneumoniae*. *Int J Environ Res Public Health*, 2020;17(17):6278.
5. Gupta A, Bhatti S, Leytin A, Epelbaum O. Novel complication of an emerging disease: Invasive *Klebsiella pneumoniae* liver abscess syndrome as a cause of acute respiratory distress syndrome. *Clin Pract*, 2017;8(1):1021.
6. Vernet V, Madoulet C, Chippaux C, Philippon A. Incidence of two virulence factors (aerobactin and mucoid phenotype) among 190 clinical isolates of *Klebsiella pneumoniae* producing extended-spectrum beta-lactamase. *FEMS Microbiol Lett*, 1992;75(1):1–5.
7. Putze J, Hennequin C, Nougayrède JP, Zhang W, Homburg S, Karch H, Bringer MA, Fayolle C, Carniel E, Rabsch W, Oelschlaeger TA, Oswald E, Forestier C, Hacker J, Dobrindt U. Genetic structure and distribution of the colibactin genomic island among members of the family Enterobacteriaceae. *Infect Immun*, 2009;77(11):4696–4703.
8. Wang G, Zhao G, Chao X, Xie L, Wang H. The Characteristic of Virulence, Biofilm and Antibiotic Resistance of *Klebsiella pneumoniae*. *Int J Environ Res Public Health*, 2020;17(17):6278.
9. Vogel JD, Johnson EK, Morris AM, et al. Clinical Practice Guideline for the Management of Anorectal Abscess, Fistula-in-Ano, and Rectovaginal Fistula. *Dis Colon Rectum*, 2016;59(12):1117–1133.
10. Himeno D, Matsuura Y, Maruo A, Ohtori S. A novel treatment strategy using continuous local antibiotic perfusion: A case series study of a refractory infection caused by hypervirulent *Klebsiella pneumoniae*. *J Orthop Sci*, 2022;27(1):272–280.

Acknowledgement

doc. MVDr. Renáta Karpíšková, Ph.D., Department of Public Health of Masaryk University in Brno; MUDr. Vojtěch Sedlák, Department of Radiodiagnostics, MUDr. Martin Pochop, Department of Anaesthesiology, Resuscitation and Intensive Care Medicine, Military University Hospital Prague.

Founding

The article was supported by Military University Hospital Grant MO 1012.

Do redakce došlo dne 1. 7. 2022.

Adresa pro korespondenci:

MUDr. Aleš Rára, Ph.D.

Klinika anesteziologie a intenzivní medicíny,

1. lékařská fakulta Univerzity Karlovy

a Ústřední vojenská nemocnice

U Vojenské nemocnice 1200

169 02 Praha 6

e-mail: raraales@uvn.cz