proLékaře.cz | 16.10.2026

Severe hypophosphatemic osteomalacia as a complication of antiviral treatment for hepatitis B: a case report

Ťažká hypofosfatemická osteomalácia ako komplikácia antivirotickej liečby hepatitídy B: kazuistika

Martina Škamlová[1,2], Ľubomír Skladaný[1], Zlata Kmečová[1]

[1]Department of Internal medicine II of Slovak Medical University, F. D. Roosevelt University Hospital in Banská Bystrica, Slovakia
[2]Department of Rheumatology, Medical Faculty of Slovak Medical University and National Institute of Rheumatic Diseases, Piešťany, Slovakia

✉ **Martina Škamlová, MD** | mskamlova@nspbb.sk | www.fnspfdr.sk

Received | Doručené do redakcie | Doručeno do redakce 1. 2. 2021
Accepted | Prijaté po recenzii | Přijato po recenzi 10. 3. 2021

Abstract
Chronic antiviral therapy with adefovir and related drugs (tenofovir, cidofovir) is a potential cause of severe hypophosphatemic osteomalacia. We present a case report of a 68 years old woman with chronic B hepatitis and long-term antiviral treatment with adefovir. The patient presented with generalized bone pain, height drop and muscle adynamia. Subcapital fractures of both femurs, pelvic, ribs, metatarsal fractures and multiple vertebral fractures gradually manifested. The laboratory findings consisted of severe hypophosphatemia, normocalcemia, mild hypokalemia and significant elevation of ALP (alkaline phosphatase). The urinary finding was proteinuria and glycosuria. Bone densitometry displayed mild osteoporosis. Whole-body scintigraphy of the skeleton showed numerous foci of increased osteogenesis. Hypophosphatemic osteomalacia as a consequence of adefovir-induced tubulopathy with excessive phosphate loss was suspected. The therapy consisted of a change in antiviral treatment and supplementation of elementary phosphate, vitamin D and calcium. The subsequent course was characterized by the gradual improvement of clinical, laboratory and morphological findings.

Key words: adefovir – hypophosphataemia – osteomalacia – tubulopathy

Abstrakt
Chronická antivirotická liečba adefovirom a jemu príbuznými liekmi (tenofovir, cedofovir) je potencionálna príčina ťažkej hypofosfatemickej osteomalácie. Uvádzame popis prípadu 68-ročnej pacientky s chronickou hepatitídou typu B, dlhodobo na antivirotickej liečbe adefovirom. Prítomná generalizovaná kostná algia, pokles výšky, svalová adynamia. Postupne sa manifestovali subkapitálne fraktúry oboch femurov, fraktúry panvy, rebier, metatarzov, multietážové vertebrálne fraktúry. Laboratórne nálezy pozostávali z ťažkej hypofosfatémie, normokalcémie, ľahkej hypokalémie a významnej elevácie ALP (alkalickej fosfatázy). Močový nález tvorila proteinúria a glykozúria. Denzitometricky v pásme miernej osteoporózy. Celotelová gamagrafia skeletu preukázala početné ložiská zvýšenej osteogenézy. Bola vyslovená suspekcia na hypofosfatemickú osteomaláciu ako dôsledok adefovirom indukovanej tubulopatie s excesívnou stratou fosfátov. Terapia pozostávala zo zmeny antivirotickej liečby, suplementácie fosfátov, vitamínu D a vápnika per os. Následný priebeh bol charakterizovaný postupným zlepšovaním klinického, laboratórneho aj morfologického nálezu.

Kľúčové slová: adefovir – hypofosfatémia – osteomalácia – tubulopatia

prolékaře.cz | 16.10.2026

Introduction

Osteomalacia is a metabolic bone disease characterized by the failure of mineralization of the newly formed osteoid at sites of bone turnover and periosteal or endosteal apposition [1]. Mineralization of the synthesized osteoid is prolonged from several days to 3 months [1,2]. Numerous causes of osteomalacia can be broadly divided into two basic groups – osteomalacia due to abnormal vitamin D metabolism and osteomalacia due to phosphate homeostasis disorders (table 1) [1–3]. One of the possible causes of osteomalacia is chronic antiviral therapy used in the treatment of viral hepatitis and HIV infection. The basic mechanism is the renal tubules damage with excessive loss of phosphates in the urine (a form of acquired Fanconi syndrome). Late diagnosis and treatment can lead to severe disabling osteomalacia.

Case description

We present a case report of a 68-year-old woman with a history of chronic hepatitis B. The patient had no other significant comorbidities. She was diagnosed with hepatitis in 1985 at the age of 33. As a part of the therapy, the patient received treatment with interferon and, since 2007, adefovir has been used at a dose of 10 mg/day. Over the years, chronic hepatitis has progressed to the stage of liver cirrhosis (Child-Pugh A). HBV DNA was undetectable for a long time. She reached menopause at 45 years, without subsequent hormone replacement therapy. In the year 2013, the patient suffered bilateral subcapital fractures of the femur, treated surgically, by bilateral total hip arthroplasty. Numerous rib infractions were diagnosed in 2014 and in 2015 fractures of the pelvis, metatarsus, metacarpus, forearm and compression fractures of thoracic and lumbar vertebrae Th12, L1, L2 were added. Generalized skeletal pain was the dominant symptom. Persistent pain was accented in the ribs, spine, hips, lower legs and forearms. Due to chest pain, the patient complained of shortness of breath, insomnia and depression. Hypomobility gradually increased for both pain and muscle weakness. The patient observed a decrease in height of up to 10 cm over 2 years. Symptoms have gradually escalated since 2013. In 2013, the patient underwent a series of out-

Table 1 | Causes of osteomalacia. According to [1–3]

vitamin D dependent osteopathy	
low bioavailability	nutritional deficit
	low sunlight exposition
	malabsorption (Crohn disease, hepatobiliary and pancreatic disorders, others)
abnormal metabolism of vitamin D	hepatobiliary diseases
	chronic kidney diseases
	drugs (anticonvulsives...)
receptor defects	defect of vitamin D receptor
abnormal phosphate homeostasis	
chronic phosphate malabsorption	aluminium antacids
renal losses	familial hypophosphatemic rachitis
	Fanconi syndromes -hereditary forms
	acquired tubulopathy (systemic lupus, Sjogren´s syndrome
	drug toxicity, paraproteinemia
	monoclonal gammopathies, metals)
	oncogenic hypophosphatemic osteomalacia
	drugs
various defects of mineralization	
inhibitors of mineralization	fluorides, bisphosphonates
	chronic renal failure (aluminium)
hypophosphatasia	

prolékaře.cz | 16.10.2026

patient examinations in regional health facilities. The serum laboratory findings were normocalcemia, mild hypophosphatemia and hypokalemia, more significantly increased alkaline phosphatase (ALP) levels. Slightly elevated creatinine levels have been documented intermittently. Small proteinuria was present in the urine. Hypovitaminosis D and normal PTH levels were diagnosed from the endocrinology panel. Axial skeletal densitometry performed in 11/2014 showed bone density in the osteoporosis range (T-total -2.5 SD). Hematological examination with repeated trepanobiopsy of the bone marrow ruled out myeloproliferative syndromes. The condition was concluded in 2014 as osteoporosis of combined etiology (postmenopausal and secondary to liver cirrhosis) and recalcification treatment with calcium, vitamin D and antiresorptive treatment with denosumab was initiated. The patient's condition did not improve; on the contrary, after denosumab administration, the patient reported worsening of symptoms and refused further administration.

For differential diagnosis, the patient was hospitalized at our inpatient clinic on 11/2015. The crucial **symptom** was diffuse skeletal pain, general weakness and hypomobility. Pain and muscle adynamia disrupted normal

Table 2 | Laboratory findings

examination	value	normal range
basic biochemistry (serum)	**phosphate 0,57 mmol/l**	0.65–1.6 mmol/l
	ALP 10,4 µkat/l	0.05–2.0 µkat/l
	calcium 2.52 mmol/	2.25–2.75 mmol/l
	calcium, ionized 1.46 mmol/l	1.15–1.27 mmol/l
	albumin 44 g/l	35–45 g/l
	protein 72 g/l	65–82 g/l
	glomerular filtration > 1ml/s	0.9–1.8 ml/s
	creatinin 85 µmol/l	49–90 µmol/l
	glucose 5.5 mmol/l	3.3–6.1 mmol/l
	ethanol 0 g/dl	0–50 mg/dl
acid-base parameters (capillary)	pH 7,375	7,36–7,44
	pCO_2 4.29 kPa	4,8–5,9 kPa
	pO_2 8.75 kPa	9,9–14,4 kPa
	HCO^{3-} 18.4 mmol/l	22–26 mmol/l
	base excess (BE-) -5.3 mmol/l	-2,5–2,5 mmol/l
hematology	quick time 87 %	80–120 %
	hemoglobin 132 g/l	120–155 g/l
	red cell count 4.1 × 10^{12}/l	3.9–5.03 x 10^{12}/l
	white cell count 6.9 × 10^{9}/l	3.5–10.5 x 10^{9}/l
	platelets 210 × 10^{9}/l	150–450 x 10^{9}/l
bone turnover (serum)	beta-crosslap 1.76 ng/ml	0–1.008 ng/ml
	P1NP total 184 ng/ml	16.27–73.87 ng/ml
endocrinology	PTH 24,9 pg/ml	12–88 pg/ml
	vitamin D 106 nmol/l	75–250 nmol/l
	TSH 0,72 mIU/ml	0.34–5.6 IU/ml
urine analysis	proteinuria 0,6 g/l	0–0.2 g/l
	phosphaturia 40 mmol/12 hours	23–48 mmol/12 hours
	glycosuria (dipstick test 1+)	trace

prolékaře.cz | 16.10.2026

self-service activities. The **clinical examination** showed generalized bony tenderness, with particular involvement of the ribs, vertebrae, pelvis, lower legs and forearms. Apparent atrophy of the proximal muscle groups was present. The depressive syndrome was manifest. The patient's height was 162 cm (174 cm in 2011). **Laboratory tests** showed significant hypophosphatemia (0.57 mmol/l), increased total ALP (10.4 µkat / l), mild hypokalemia (K + 3.4 mmol/l). Glycemia, total and ionized calcium, total protein, albumin, prothrombin time, creatinine, urea, vitamin D_3, parathormone (PTH), thyroid-stimulating hormone (TSH), free thyroxin (fT4) were at normal levels. Serum protein electrophoresis was free of pathology. The urinary finding consists of glycosuria, mild proteinuria (0.6 g/l), without proven hyperphosphaturia, hypercalciuria and paraprotein (table 2). We demonstrated high bone turnover (Beta-Crosslap 1.76 ng/ml, ALP 10.4 µkat/l, total P1NP 184 ng/ml). Borderline positivity of antigliadin antibodies was detected, but enterobiopsy ruled out celiac disease. **X-ray of the skeleton** described wedge-shaped deformations of vertebral bodies, multiple fractures and infractions of ribs and pelvic fracture (figure 1–3). Bone densitometry showed low bone density for the axial skeleton (T score -2.8 SD). **Whole-body scintigraphy** visualised diffusely increased uptake in the facial skeleton, numerous small foci were presented in the ribs, as well as in the vertebrae of the thoracic and lumbar spine, and around sacroiliac and knee joints (figure 4). In the context of the clinical picture of osteopathy compatible with osteomalacia, hypophosphatemia and signs of nephropathy, hypophosphatemic osteomalacia was suspected. After a review of the medical history (many years of adefovir use), adefovir appeared to be a probable aetiological factor. One of the known side effects of adefovir is the development of proximal tubular nephropathy (Fanconi syndrome) with excessive phosphate loss and development of hypophosphatemic osteomalacia and myopathy. A diagnosis of hypophosphatemic osteomalacia secondary to adefovir therapy was made. We subsequently continued the recalcification treatment of the patient (calcium and vitamin D supplementation) and started the supplementation of elemental phosphate. Adefovir could only be discontinued after receiving adequate alternative therapy due to the risk of exacerbation of hepatitis and decompensation of cirrhosis upon abrupt discontinuation (3/2016 adefovir was replaced by entecavir). The subsequent course was characterized by a gradual improvement of the clinical, laboratory and morphological findings. During the following

Figure 1 | Wedge-shaped vertebral deformations

Figure 2 | Rib fractures

Figure 3 | Pelvic fracture

prolékaře.cz | 16.10.2026

weeks to months, there was a gradual reduction in skeletal pain and muscle weakness. Significant decrease to a gradual normalization of ALP, normalization of phosphatemia and disappearance of glycosuria, proteinuria was evident (graph 1–2). The improvement of laboratory findings occurred gradually and lagged behind the clinical effect. Morphological findings on repeated whole-body scintigraphy of the skeleton after 2 years of treatment were characterized by regression of foci with high uptake (figure 5).

Figure 4 | Whole-body scintigraphy (before treatment)

Graph 1 | Serum phosphate

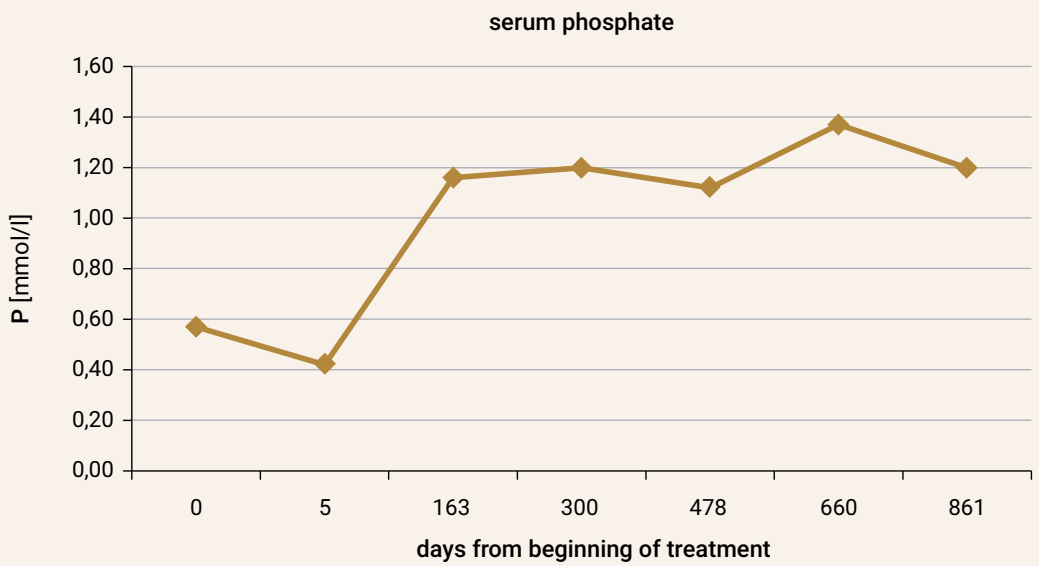

prolékaře.cz | 16.10.2026

Discussion

Renal tubular toxicity has been described as a possible adverse effect of chronic antiviral therapy with adefovir, tenofovir, and cidofovir [4–7]. These are nucleotide reverse transcriptase inhibitors that are incorporated into the DNA of the virus and subsequently inhibit the replication of the virus. They are effective against hepatitis B and HIV viruses. Adefovir is currently being replaced by more potent tenofovir. Adefovir-induced renal toxicity has been reported predominantly with the daily

Graph 2 | Total alkaline phosphatase

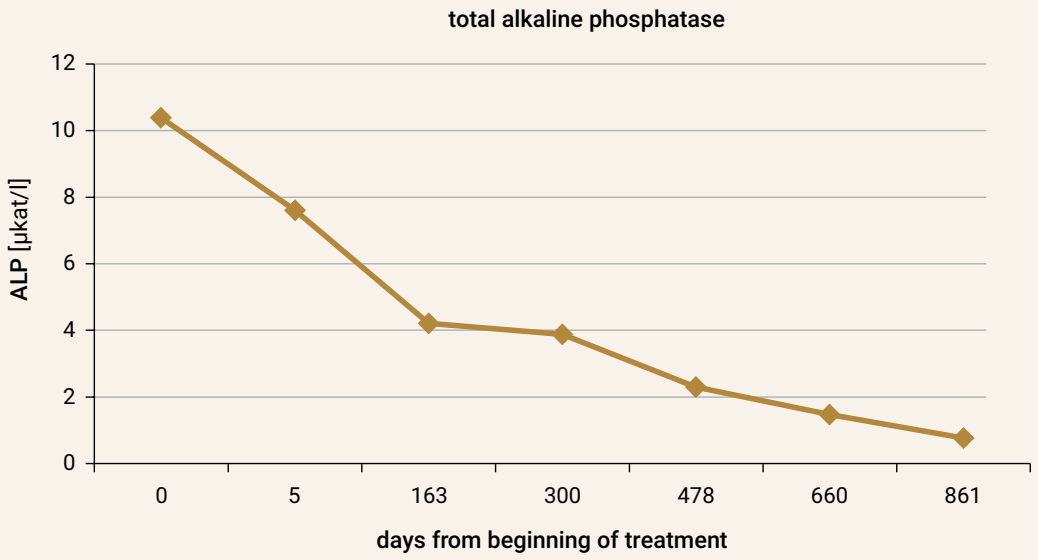

Figure 5 | Whole-body bone scintigraphy (2 years of treatment)

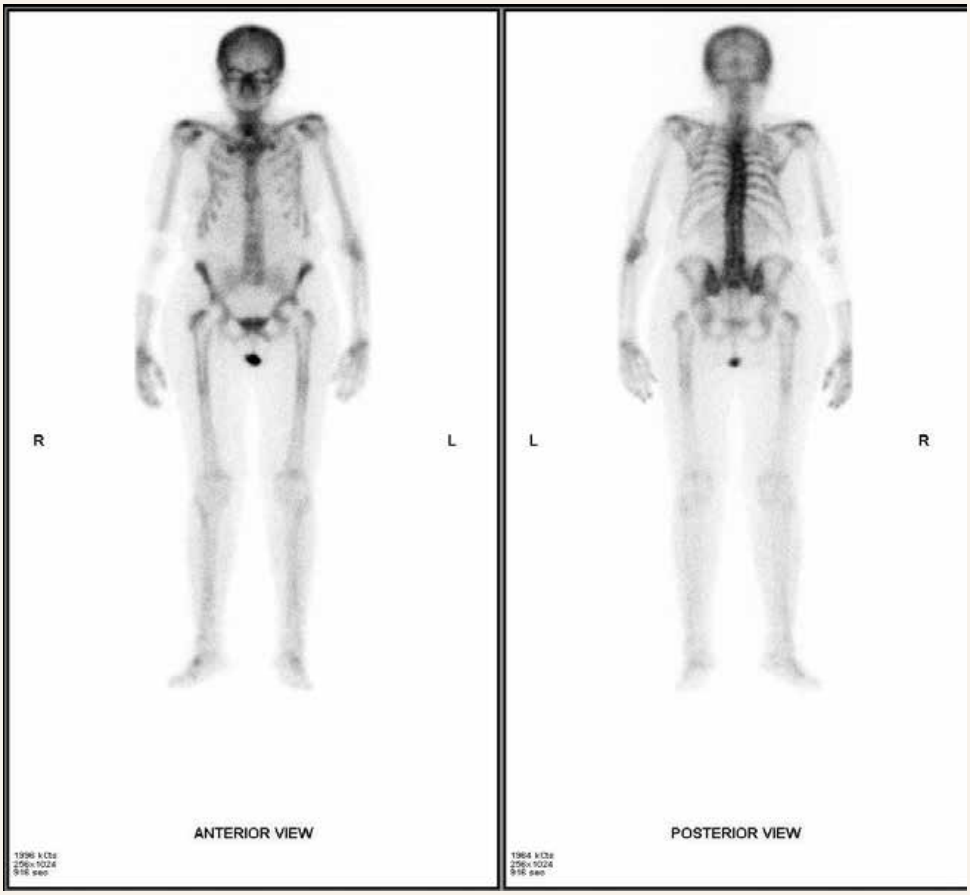

prolékaře.cz | 16.10.2026

dose of 30 mg, with no or only a very small percentage of cases during the long-term administration of 10 mg [8–10]. Manifest Fanconi syndrome due to generalized dysfunction of the proximal tubule as a consequence of the direct toxic effect of the antiviral drug is rarely described in the literature in the form of isolated case reports. The pathophysiology of tubular damage is primarily dependent on the transport of the drug into tubular cells (organic anion transporter) with consequent mitochondrial toxicity [11]. The effect of tubular dysfunction on the development of osteomalacia is multifactorial. The primary mechanism is caused by an excessive loss of phosphate in the urine followed by insufficient osteoid mineralization. As a contributing factor, metabolic acidosis is thought to have a negative effect on bone mineralization. Reduced activity of the alpha-1 hydroxylase in tubular cells with the resulting reduced level of 1,25-dihydroxyvitamin D can also be involved [5]. In the case described, adefovir treatment was administered for 8 years. Osteopathy started to manifest after 6 years of treatment as multiple fractures at various sites. Initial diagnostic findings in the phase of the incomplete clinical picture captured hypophosphatemia, hypovitaminosis D and osteoporosis. Persistent diffuse skeletal pain and muscle adynamia gradually became the dominant symptom, suggesting the osteoporosis secondary to cirrhosis will not be the diagnosis. For a clear diagnosis, a series of laboratory testing and imaging was necessary during the diagnostic hospital stay. The basic laboratory findings showed hypophosphatemia and signs of tubular nephropathy, demonstrated as glycosuria and proteinuria. The combination of osteopathy, hypophosphatemia and tubular nephropathy suggested hypophosphatemic osteomalacia due to tubular nephropathy as the most probable diagnosis. The urinalysis did not show presumed hyperphosphaturia, which can be explained by chronic hypophosphatemia, decreasing absolute phosphaturia. The therapy consisted of elemental phosphate supplementation, discontinuation of adefovir and supplementation of vitamin D with calcium. Adefovir could be discontinued only after adequate alternative was obtained due to the risk of exacerbation of hepatitis with possible fatal decompensation of liver cirrhosis. In the order of weeks to months after the initiation of treatment, the clinical, laboratory and morphological findings gradually improved.

Conclusion

Long-term antiviral therapy (adefovir and its equivalents) may in rare cases lead to the development of tubular nephropathy and severe hypophosphatemic osteomalacia with a disabling course. The key to a correct diagnosis and specific treatment, in this case, is the knowledge of the side effects of the drug, the correct interpretation of the laboratory findings and, last but not least, close interdisciplinary cooperation. Physicians prescribing antiviral therapy should be aware of this rare but serious complication.

Declaration of conflict of interest: there is no conflict of interest.

References

1. Holick MF. Osteomalacia and rickets. In: Hochberg M, Silman A et al (eds). Rheumatology. 5th ed. Mosby Elsevier: 2010: 1997–2006. ISBN 978–0323065511.

2. Masaryk P. Osteomalácia a rachitída. Via Pract 2009; 6(1): 13–15.

3. Lane NE. Metabolic Bone Disease. In: Firestein G, Budd R (eds) et al. Kelley´s Textbook of Rheumatology. Vol 2. 9th ed. Elsevier: 2013: 1660–1679.

4. Earle KE, Seneviratne T, Shaker J et al. Fanconi's Syndrome in HIV+ Adults: Report of Three Cases and Literature Review. J Bone Miner Res 2004; 19(5): 714–721. Dostupné z DOI: <http://dx.doi.org/10.1359/jbmr.2004.19.5.714>.

5. Girgis CM, Wong T, Ngu MC et al. Hypophosphataemic Osteomalacia in Patients on Adefovir Dipivoxil. J Clin Gastroenterol 2011; 45(5): 468–73. Dostupné z DOI: <http://dx.doi.org/10.1097/MCG.0b013e3181e12ed3>.

6. Kim DH, Sung DH, Min YK. Hypophosphatemic osteomalacia induced by low-dose adefovir therapy: focus on manifestations in the skeletal system and literature review. J Bone Miner Metab 2013; 31(2): 240–246. Dostupné z DOI: <http://dx.doi.org/10.1007/s00774–012–0384-y>.

7. Mateo L, Holgado S, Mariñoso ML, et al. Hypophosphatemic osteomalacia induced by tenofovir in HIV-infected patients. Clin Rheumatol 2016; 35(5): 1271–1279. Dostupné z DOI: <http://dx.doi.org/10.1007/s10067–014–2627-x>.

8. Hadziyannis SJ, Tassopoulos NC, Heathcote EJ et al. Adefovir Dipivoxil for the Treatment of Hepatitis B e Antigen–Negative Chronic Hepatitis B. N Engl J Med 2003; 348(9): 800–807. Dostupné z DOI: <http://dx.doi.org/10.1056/NEJMoa021812>.

9. Hadziyannis SJ, Tassopoulos NC, Heathcote EJ et al. Long-Term Therapy with Adefovir Dipivoxil for HBeAg-Negative Chronic Hepatitis B. N Engl J Med 2005; 352(26): 2673–2681. Dostupné z DOI: <http://dx.doi.org/10.1056/NEJMoa042957.>.

10. Ha NB, Ha NB, Garcia RT et al. Renal dysfunction in chronic hepatitis B patients treated with adefovir dipivoxil. Hepatology 2009; 50(3): 727–734. Dostupné z DOI: <http://dx.doi.org/10.1002/hep.23044>.

11. Ho ES, Lin DC, Mendel DB et al. Cytotoxicity of Antiviral Nucleotides Adefovir and Cidofovir Is Induced by the Expression of Human Renal Organic Anion Transporter 1. J Am Soc Nephrol 2000; 11(3): 383–393.