

## The Desmoid Tumor – A Locally Aggressive Neoplasm

Schwartz R. A., Trovato M. J., Lambert P. C.

Dermatology, New Jersey Medical School,  
Newark, New Jersey USA

### Souhrn

#### Desmoid – lokálně agresivní tumor

Desmoidy jsou benigní, ale lokálně agresivní vazivové nádory vycházející ze svalové aponeurózy. Desmoidy jsou tuhé, nebolestivé hyperproliferace vazivové tkáně. Mohou patřit k projevům vzácného autosomálně dominantního Gardnerova (familiální adenomatózní polypóza) (FAP) syndromu. Léčba těchto poměrně vzácných vazivových nádorů je komplikována jejich klinickým průběhem a tendencí k recidivě.

**Klíčová slova:** muskuloaponeurotická fibromatóza – agresivní fibromatóza – hluboká fibromatóza – nemetastazující fibrosarkom – fibrosarkom grade 1 – fibrosarkom grade 1/2

### Summary

#### The Desmoid Tumor – A Locally Aggressive Neoplasm

Desmoid tumors are benign but locally aggressive fibrous neoplasms originating from a muscle aponeurosis. Desmoid tumors are firm, nontender overgrowths of fibrous tissue. They may be a feature of the rare autosomal dominant Gardner [familial adenomatous polyposis (FAP)] syndrome. Their clinical course and the tendency for recurrence make the treatment of these relatively rare fibrous tumors difficult.

**Key words:** musculoaponeurotic fibromatosis – aggressive fibromatosis – deep fibromatosis – nonmetastasizing fibrosarcoma – grade 1 fibrosarcoma – grade 1/2 fibrosarcoma

## INTRODUCTION

Desmoid tumors are histologically benign fibrous neoplasms originating from the muscle aponeuroses (6, 9, 21, 33–35). They may occur anywhere throughout the body, and may occur as a feature of the rare Gardner [familial adenomatous polyposis (FAP)] syndrome (14, 26, 27). The term desmoid, coined by Muller in 1838, is derived from the Greek word – desmos – which means tendon-like. These lesions may be viewed as an exuberant reactive phenomenon, a hyperplasia of muscle/connective tissue analogous to the keloid.

Desmoid tumors often appear as infiltrative firm overgrowths of fibrous tissue, and are locally aggressive. The synonym “aggressive fibromatosis” conveys their characteristic marked cellularity, usually well-differentiated, and aggressive local behavior, tending to invade adjacent striated muscle and other tissues. This course and the tendency for recurrence may make the treatment of these relatively rare fibrous tumors challenging.

## STRUCTURE AND BIOLOGY

Although desmoid tumors most commonly arise from the rectus abdominis muscle in postpartum women and in scars due to abdominal surgery, they may occur alongside any skeletal muscle (7). These tumors tend to infiltrate adjacent muscle bundles, frequently entrapping them and causing their degeneration. Although fixation to musculoaponeurotic structures is apparent, the overlying skin is normal. The myofibroblast is the cell considered to be responsible for the development of desmoid tumors (16).

Despite their benign histologic appearance and negligible metastatic potential, the tendency of desmoid tumors to infiltrate locally is significant. These lesions produce deformity, morbidity, and mortality resulting from direct interference in function as well as pressure effects and potential obstruction of vital structures and organs.

## EPIDEMIOLOGY

Overall, desmoid tumors are reported to account for 0.03% of all neoplasms (35). They most commonly occur in women after childbirth. In children, the sex incidence is equal (9). Sixty patients were recently described with an average age at diagnosis of 41.3 years and a female-to-male sex ratio of 1.2:1 (23). In patients with familial adenomatous polyposis (FAP), the prevalence of desmoid tumors is as high as 15% (22).

## GENETICS

Gardner syndrome (FAP) is characterized by colorectal adenomatous polyps and soft and hard tissue neoplasms. The former may number in the hundreds to thousands. Gardner syndrome was regarded as a separate disease until the identification of the APC (adenomatous polyposis coli) gene, at which point it was recognized that mutations in the APC gene are the underlying cause of both Gardner syndrome and familial adenomatous polyposis (FAP)(4). Some authors regard Gardner syndrome as a subset of FAP. It has even been suggested that the term "Gardner syndrome" be replaced by FAP (4). There is also evidence for genetic predisposition to desmoid tumors in FAP independent of the APC mutation, however (36).

FAP results from a germline mutation in the APC gene. Desmoids are associated with a biallelic APC mutation in the affected tissue. This usually results from a spontaneous somatic mutation in the unaffected APC gene of a single cell in a patient with the FAP syndrome. This process is an example of the Knudsen "two hit" hypothesis, proposed in 1974, in which a tumor suppressor gene, such as APC, must be biallelically mutated in order for a specific type of tumor to occur (3, 11). In genetically normal individuals, with normal germ line genes, this requires a rare combination of events, such that at least two somatic mutations must occur in both alleles of a single tumor suppressor gene, in this case the APC gene. In patients with the FAP syndrome, however, one APC germline gene is already mutated, so that this gene is mutated in every cell in the body (barring a rare reverse somatic mutation in some cells), and, therefore, only one new somatic mutation is required in the opposite APC gene for the tumor to develop.

In desmoid tumors, one of the two mutations usually occurs distal to the second  $\beta$ -catenin binding/degradation repeat of the gene (3' to codon 1399) (8,36). Catenin and catenin-binding genes have been found to be associated with neoplastic processes in a number of ways (30). Independent predictors of increased desmoid risk in one study were said to be: germline mutation distal to codon 1399, any family history of gastrointestinal disease, and

a strong family history of desmoid tumors (36). The relationship between certain extracolonic manifestations and sites of the APC mutation suggests specific roles of the APC protein in different tissues. These different roles may correspond to specific sites of missense mutations in the APC gene. For example, It has been suggested that dental manifestations of Gardner syndrome are associated with mutations at or near codon 1556 (28). However, the influence of unknown genetic factors independent of APC in susceptibility to desmoid tumors in FAP needs to be explored.

Desmoid tumors occur with an incidence of 10 to 15 % in patients affected by FAP, an autosomal inherited disease caused by germline mutations in the APC gene, whereas sporadic forms have no hereditary background (6). APC germline mutations in apparently sporadic desmoid tumor patients without clinical or familial signs of familial adenomatous polyposis but with a family history of colorectal carcinoma in at least one family member were evaluated (6). The results indicate that patients with sporadic desmoids and no clinical signs of familial adenomatous polyposis detected on careful examination, esophagogastroduodenoscopy, and complete colonoscopy may not need to be tested routinely for germline mutations of the APC gene. However, it might be more time and cost effective to perform an APC mutational analysis instead of all of these other tests.

FAP may be associated with mutations in the APC gene, but mutations in several other genes, particularly "mismatch" DNA repair genes, which are primarily responsible for ensuring integrity of polymerases responsible for DNA replication, may also result in familial colonic polyposis (5, 10, 12). These cases of familial colonic polyposis typically do not show other manifestations of Gardner syndrome. Conversely, extracolonic manifestations characteristic of Gardner syndrome may occur independent of intestinal polyps or a mutation in the APC gene (20).

## CLINICAL PRESENTATION

Peripheral desmoid tumors are firm, smooth, non-tender and mobile. They are often adherent to surrounding structures, and tend to be bulky at presentation. The overlying skin is usually unaffected. They are slow growing, but may enlarge up to 25 cm (17). They are usually solitary, but may be multiple. Intra-abdominal desmoid tumors usually remain asymptomatic until their growth and infiltration cause visceral compression. Desmoids may also be responsible for pancreatic cysts and pseudocysts (29). Symptoms of intestinal, vascular, ureteric, or neural involvement may be their initial manifestations (24, 25, 31). Desmoid tumors must be distinguished from other neoplasms, including fibrosarcomas (25).

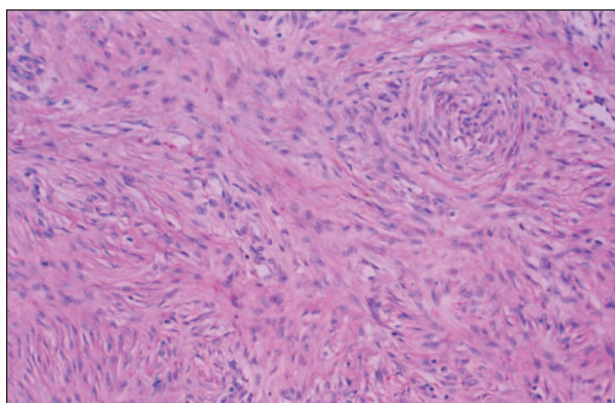
Although desmoid tumors can arise in any skeletal

muscle, they most commonly develop in the anterior abdominal wall and shoulder girdle. Retroperitoneal desmoid tumors are more common in familial colon polyposis (Gardner syndrome) after abdominal surgery than in other conditions (18, 32). However, familial clusters without evidence of any associated syndromes have also been described (13). A history of trauma, often surgically-induced, to the site of the tumor may be elicited (24). Desmoid tumors tend to occur either spontaneously or in abdominal scars after colectomy.

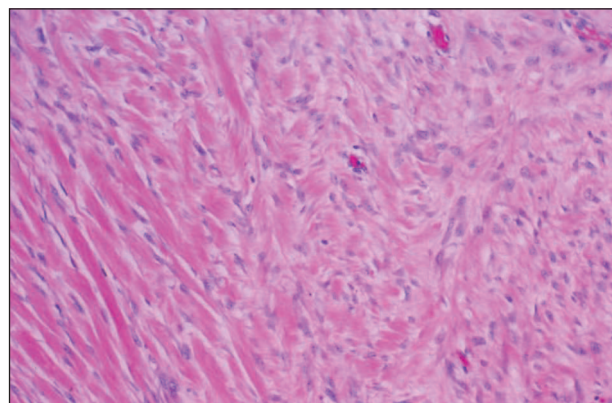
The presence of desmoid tumor mandates obtaining a family history for evidence of FAP (Gardner syndrome) (6, 8, 34). This syndrome consists of colonic polyposis (with malignant transformation), epidermal inclusion cysts, osteomas, fibrous neoplasms of the skin, subcutaneous tissue and abdominal cavity, and characteristic ocular manifestations (37). The epidermoid inclusion cysts may show changes resembling the benign hair bulb mimicking hamartoma, pilomatricoma (38).

## HISTOPATHOLOGY

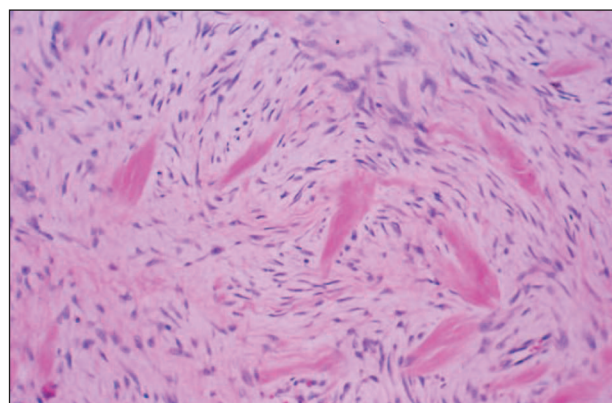
Microscopically, one sees a tumor composed of fibroblasts that produce abundant collagen, the latter surrounding poorly circumscribed bundles of spindle cells (Fig. 1) (16, 35). These dense bundles of eosinophilic spindle cells contain regular nuclei and pale cytoplasm with neither mitoses nor giant cells. Macrophages, giant cells, and lymphocytes are evident peripherally. The aforementioned features are in contrast to those in a fibrosarcoma, which has greater mitotic activity, an increased nuclear-to-cytoplasm ratio, greater vascularity, less collagen production, and a paucity of lymphocytes (35). Immunostaining with vimentin,  $\alpha$  smooth muscle actin, muscle actin, and desmin are helpful in distinguishing desmoid tumors from other neoplasms. On electron microscopic examination, the spindle cells of desmoid tumors appear to be myofibroblasts (16). Tumor



**Fig. 1. Bland fibrocytic cells growing in a haphazard to storiform manner and producing collagen (hematoxylin and eosin, x 100).**



**Fig. 2. Spindle cells of a desmoid tumor invading skeletal muscle (hematoxylin and eosin, x 100).**



**Fig. 3. Spindle cells of a desmoid tumor surrounding and destroying skeletal muscle cells (hematoxylin and eosin, x 100).**

cells tend to surround (Fig. 2) and destroy (Fig. 3) skeletal muscle and in more advanced cases can also invade smooth muscle of viscera.

## PATIENT EVALUATION

CT scan and MRI are used for the diagnosis and follow-up of desmoid tumors (1, 9, 23). They can help determine the extent of the tumor and its relationship to nearby structures, especially prior to surgical removal. MRI is superior to CT scan in defining the pattern and extent of involvement as well as in determining if recurrence has occurred after surgery. MRI features have been correlated with pathologic findings in sixty patients (23). Twenty lesions were extraabdominal; six, intraabdominal; and three, in the abdominal wall (classic desmoid). On MRI, homogeneous isointensity or mild hyperintensity on T1-weighted images and heterogeneous high signal on T2-weighted or STIR images were evident, all of which were enhanced after IV gadolinium, usually avidly. Histologically, there were sheets of bland spindle cells in dense collagen which did not vary with the MRI signal characteristics of the lesion. Thus, the accurate diagnosis and



staging of desmoid tumors by MRI have treatment and prognostic implications.

## MANAGEMENT

Desmoid tumors exhibit a wide range of local aggressiveness, from largely indolent to locally destructive (21, 34). The optimal treatment is unclear, but a multidisciplinary approach including surgery, chemotherapy, and radiation therapy has been employed. Several novel pharmacologic and biologic treatment approaches, including the use of antiestrogens and prostaglandin inhibitors, are actively being developed (2, 15, 19, 25). Aggressive, wide surgical resection is the treatment of choice. Complete surgical excision of desmoid tumors is the only effective method of cure.

In cases of extra-abdominal desmoid tumors in which surgery is contraindicated or in cases of recurrence, a chemotherapeutic regimen of doxorubicin, dacarbazine, and carboplatin may be effective. The goals of pharmacotherapy are to induce remission, to prevent complications, and to reduce morbidity (25). The efficacy of a chemotherapeutic regimen involving doxorubicin and dacarbazine for inoperable FAP-associated desmoid tumors has been evaluated and should be considered for use as first-line chemotherapy in symptomatic desmoid tumors that are unresponsive to conventional medical therapy (19). Pharmacologic agents result in objective response rates of approximately 40% to 50%; duration of response is variable.

Local recurrences are frequent after surgery, particularly if margins are positive. Radiation therapy may be used as a treatment of recurrent disease or as primary therapy to avoid mutilating surgical resection (21). Radiotherapy alone for gross disease or after a microscopically incomplete resection yields local control rates of approximately 75% to 80%. A small fraction of patients have Gardner's syndrome, and a significant proportion of patients with desmoid tumor have had at least one recurrence before referral to a tertiary care center. The overall 10-year actuarial recurrence rate of 33% was determined in a number of studies (2). Desmoid tumors can be fatal in FAP patients if they are not suitable for surgery or radiation therapy (15).

## REFERENCES

1. ABDELKADER, M., RIAD, M., WILLIAMS, A. Aggressive fibromatosis of the head and neck (desmoid tumours). *J Laryngol Otol*, 2001; 115: 772–776.
2. BALLO, MT., ZAGARS, GK., POLLACK, A., et al. Desmoid tumor: prognostic factors and outcome after surgery, radiation therapy, or combined surgery and radiation therapy. *J Clin Oncol*, 1999; 17: 158–167.
3. BERTRAM, JS. The molecular biology of cancer. *Mol Aspects Med*, 2001; 21: 167–223.
4. BISGAARD, ML., BULOW, S. Familial adenomatous polyposis (FAP): Genotype correlation to FAP phenotype with osteomas and sebaceous cysts. *Am J Hum Genet*, 2006; 140(3): 200–204.
5. BRONNER, MP.: Gastrointestinal syndromes. *Am J Mol Genet A*, 2003; 122: 335–341.
6. BRUECKL, WM., BALLHAUSEN, WG., FORTSCH, T., GUNTHER, K., FIEDLER, et al. Genetic testing for germline mutations of the APC gene in patients with apparently sporadic desmoid tumors but a family history of colorectal carcinoma. *Dis Colon Rectum*, 2005; 48: 1275–1281.
7. BUITENDIJK, S., VAN DE VEN, CP., DUMANS, TG. Pediatric aggressive fibromatosis: a retrospective analysis of 13 patients and review of literature. *Cancer*, 2005; 104: 1090–1099.
8. CASPARI R, OLSCHWANG S, FRIEDL W, et al. Familial adenomatous polyposis: desmoid tumours and lack of ophthalmic lesions (CHRPE) associated with APC mutations beyond codon 1444. *Hum Mol Genet*, 1995; 4: 337–340.
9. DORMANS, JP., SPIEGEL, D., MEYER, J., et al. Fibromatoses in childhood: the desmoid/fibromatosis complex. *Med Pediatr Oncol*, 2001; 37: 126–31.
10. FEARHEAD, NS. Familial adenomatous polyposis and MYH. *Lancet*, 2003; 352(9377): 39–41.
11. FEARHEAD, NS., BRITTON, MP., BODNER, WF. The ABC of APC. *Hum Mol Genet*, 2001; 10: 721–233.
12. FEARHEAD, NS., WILDING, JL., WINNER, B., et al. Multiple rare variants in different genes account for multifactorial inherited susceptibility to colorectal adenomas. *Proc Natl Acad Sci USA*, 2004; 101: 15992–15997.
13. GACHES, C., BURKE, J. Desmoid tumour (fibroma of the abdominal ) occurring in siblings. *Br J Surg*, 1971 Jul; 58(7): 495–8.
14. GALIATSATOS, P., FOULKES, WD. Familial adenomatous polyposis. *Am J Gastroenterol*, 2006; 101: 385–398.
15. GEGA, M., YANAGI, H., YOSHIKAWA, R., NODA, M., IKEUCHI, H. et al. Successful chemotherapeutic modality of doxorubicin plus dacarbazine for the treatment of desmoid tumors in association with familial adenomatous polyposis. *J Clin Oncol*, 2006; 24: 102–5.
16. GOELLNER, JR., SOULE, EH.: Desmoid tumors. An ultrastructural study of eight cases. *Human Pathol*, 1980; 11: 43–50.
17. GONATAS, K. Extra-abdominal desmoid tumors: Report of six cases. *Arch Pathol*, 1961; 71: 214–221.
18. GURBUZ, AK., GIARDIELLO, FM., PETERSEN, GM. Desmoid tumours in familial adenomatous polyposis. *Gut*, 1994; 35: 377–81.
19. HAMILTON, L., BLACKSTEIN, M., BERK, T., et al. Chemotherapy for desmoid tumours in association with familial adenomatous polyposis: a report of three cases. *Can J Surg*, 1996; 39: 247–5.
20. HERMANN, SM., ALDER, YD., SCHMIDT-PETERSEN, K., et al. The concomitant occurrence of multiple epidermal cysts, osteomas and thyroid gland nodules is not diagnostic for Gardner syndrome in the absence of intestinal polyposis: A clinical and genetic report. *Br J Dermatol*, 2003; 149: 877–883.
21. HOSALKAR, HS., FOX, EJ., DELANEY, E., et al. Desmoid tumors and current status of management. *Orthop Clin North Am*, 2006; 37: 53–63.

22. KLEMMER, S., PASCOE, L., DECOSSE, J. Occurrence of desmoids in patients with familial adenomatous polyposis of the colon. *Am J Med Genet*, 1987; 28: 385–92.
23. LEE, JC., THOMAS, JM., PHILLIPS, S., FISHER, C., MOSKOVIC, E. Aggressive fibromatosis: MRI features with pathologic correlation. *AJR Am J Roentgenol*, 2006; 186: 247–54.
24. LOPEZ, R., KEMALYAN, N., MOSELEY, HS., et al. Problems in diagnosis and management of desmoid tumors. *Am J Surg*, 1990 May; 159(5): 450–3.
25. MENDENHALL, WM., ZLOTECKI, RA., MORRIS, CG. Aggressive fibromatosis. *Am J Clin Oncol*, 2005; 28: 211–5.
26. MICHAL, M., BOUDOVA, L., MUKENSNABL, P. Gardner's syndrome associated fibromas. *Pathol Int*, 2004; 54: 523–526.
27. NANDAKUMAR, G., MORGAN, JA., SILVERBERG, D., et al. Familial polyposis coli: Clinical manifestations, evaluation, management and treatment. *Mt Sinai J Med*, 2004; 71: 384–391.
28. OKU, T., TAKAYAMA, T., SATO, Y., et al. A case of Gardner syndrome with a mutation at codon 1556 of APC: A suggested case of genotype-phenotype correlation in dental abnormality. *Eur J Gastroenterol Hepatol*, 2004; 16: 101–105.
29. PHO, LN., COFFIN, CM., BURT, RW. Abdominal desmoid in familial adenomatous polyposis presenting as a pancreatic cystic lesion. *Fam Cancer*, 2005; 4: 135–138.
30. POLAKIS, P.: More than one way to skin a catenin. *Cell*, 2001; 105: 563–566.
31. PORRU, D., STANCATI, S., GILIBERTO, GL., et al. Bilateral ureteral compression by multiple abdominal desmoid tumors in Gardner syndrome: Case report and literature review. *Urology*, 2004; 64: 1031.
32. RAYNHAM, WH., LOUW, JH. Desmoid tumours in familial polyposis of the colon. *S Afr J Surg*, 1971; 9: 133–40.
33. SCHLEMMER, M. Desmoid tumors and deep fibromatoses. *Hematol Oncol Clin North Am*, 2005; 19: 565–571.
34. SCHWARTZ, RA., TROVATO, MJ., LAMBERT, PC. Desmoid tumor. *eMedicine Dermatology* [Journal serial online]. 2007.  
Available at: <emedicine.com/derm/topic778.htm>
35. SHIELDS, CJ., WINTER, DC., KIRWAN, WO., REDMOND, HP.: Desmoid tumours. *Eur J Surg Oncol*, 2001; 27: 701–706.
36. STURT, NJ., GALLAGHE, MC., BASSETT, P., PHILIP, CR., NEALE, KF., et al. Evidence for genetic predisposition to desmoid tumours in familial adenomatous polyposis independent of the germline APC mutation. *Gut*, 2004; 53: 1832–1836.
37. TRABOULSI, EL.: Ocular manifestations of familial adenomatous polyposis (Gardner syndrome). *Ophthalmol Clin North Am*, 2005; 18: 163–166.
38. URABE, K., XIA, J., MASUDA, T., et al.: Pilomatricoma-like changes in the epidermoid cysts of Gardner syndrome with an APC mutation. *J Dermatol*, 2004; 31: 255.

Došlo do redakce: 24. 4. 2006

R.A. Schwartz  
Professor and Head, Dermatology  
New Jersey Medical School Newark, NJ 07103, USA  
E-mail: roschwar@cal.berkeley.edu