dermatologie_2_06 3.4.2006 12:55 Str. 102
proLékaře.cz | 23.11.2026

Čes.-slov. Derm. 81, 2006, No. 2, p. 102–106

The Contribution of Hermann Pinkus to Dermatology

Mehregan D.

Wayne State University, Dept. of Dermatology, Monroe, Michigan, USA

Souhrn

Přínos Hermanna Pinkuse pro dermatologii

Tento soubor článků tvoří průřez dílem dr. Hermanna Pinkuse zahrnující mnoho publikací, které jsou považovány v oboru dermatologie za významné. V těchto pracích je možné nalézt počátky pojmů, které jsou stále rozvíjeny a diskutovány v současné dermatologii a často představují základní předpoklad studia dermatologie. Opětovné zhodnocení původních článků představuje jediný způsob jak lze dosáhnout toho, aby čtenář dokázal posoudit dílo člověka, ale, v širším smyslu, i mnoha průkopníků dermatologie.

Klíčová slova: **prekancerózní fibroepitelové tumory kůže – alopecia mucinosa – ekrinní porom – epidermotropní ekrinní karcinom – velkobuněčný akantom – trichodiskom – „Tape Stripping"**

Summary

The Contribution of Hermann Pinkus to Dermatology

These articles represent a small cross section of Dr. Hermann Pinkus' work. They include many of the papers which he considered important contributions to dermatology. In them we can see the beginnings of concepts, which continue to be discussed in dermatology today and often represent fundamental knowledge in the study of dermatology. By presenting them it is hoped that the reader not only gains an appreciation for one man's work, but in a broader sense, gains an appreciation for the work of many of the pioneers in dermatology, which can only be gained by reviewing their original articles.

Key words: **premalignant fibroepithelial tumors of skin – alopecia mucinosa – eccrine poroma – epidermotropic eccrine carcinoma – large cell acanthoma – trichodiscoma – Tape Stripping**

Hermann Pinkus was well-known for his many contributions to dermatology and dermatopathology. However, many of his original publications are often underappreciated by modern students of dermatology. We will review some of Dr. Pinkus' original papers and discuss the observations as they relate to dermatology today.

Dr. Pinkus was born in Germany, the son of a prominent Berlin dermatologist, Dr. Felix Pinkus. During medical school, Dr. Pinkus worked with Dr. Rhoda Erdmann in the relatively new field of tissue culture (1). After finishing medical school, he was trained in dermatology at the University Skin Clinic in Breslau under Dr. Josaph Jadassohn (1). After finishing his dermatology residency, Dr. Pinkus left pre-World War II Germany and arrived in the United States. After fellowship in anatomy at the University of Michigan, Dr. Pinkus set up a clinical practice in Monroe, Michigan and became an attending dermatologist at Detroit Receiving Hospital. Eventually, he became Chairman at the Wayne State University, Department of Dermatology in Detroit, Michigan.

PREMALIGNANT FIBROEPITHELIAL TUMORS OF SKIN

The fibroepithelioma of Pinkus was originally described in 1953 (2). It is often noted by prominent speakers in dermatopathology today that the fibroepithelioma of Pinkus merely represents a variety of basal cell carcinoma. However, it must be noted that in the introduction to this landmark paper, Pinkus himself notes, "these tumors do not constitute a truly new entity, but, rather, they are an unusual variety of basal cell epithelioma" (2). Clinically, the lesions are marked by fleshy,

Předneseno na 11. Pražském dermatologickém sympoziu 15.–17. 9. 2005

dermatologie_2_06 3.4.2006 12:55 Str. 103
proLékaře.cz | 23.11.2026

broad-based papules and nodules that are pink, red, or tan in color. Histologically, the findings show features of basaloid masses sharply demarcated from the epidermis and surrounded by extensive fibrovascular stroma (Fig. 1). Pinkus noted a striking similarity to the intracanalicular fibroadenoma of the breast (2). As Pinkus stated, the purpose of this paper was not to propose a new tumor, however, he used this as an opportunity to discuss the origin of basal cell and squamous cell carcinomas. At the time of publication of this paper, many dermatopathologists considered basal cell epithelioma (carcinoma) to be derived from adnexal epithelium either in its adult form or from embryonic rests (2). Whereas, squamous cell carcinoma was considered to arise from the epidermis proper. However, Pinkus noted that both the basal cell layer, spinous cell layer, and adnexal epithelium are equally potent sources of epidermal regeneration after ulceration (2). He further reasoned that since this is true, he could not explain the difference between squamous cell carcinoma and basal cell tumors by different potentiality of their cells of origin. He further went on to state, "as it is believed that all epitheliomas of the skin may originate from adult pluri-potential cells rather than from one or the other specific part of the epithelial system or from embryonic rests, a descriptive classification of organoid tumors is based on resemblance to, rather than derivation from the epidermis or adnexa" (2). This is a belief, which is still espoused today by dermatopathologists lecturing on adnexal tumors, however, few if any of these speakers can name the source.

ALOPECIA MUCINOSA

Dr. Pinkus described alopecia mucinosa in 1957. The original case had been sent to Dr. Pinkus by Dr. Herb Lund, a prominent dermatopathologist himself (1). At the time, both experts agreed that they were unsure as to the significance of the reaction pattern. Five years later, a ten-year-old girl presented to Pinkus' practice in Monroe with what appeared to be tinea faciei. After the patient failed to respond to therapy, a biopsy was performed. This biopsy showed features similar to Dr. Lund's and Dr. Pinkus proceeded to put together a collection of similar cases for publication (1). The original publication presented a series of patients ranging in ages from eight to sixty-four with one to several lesions predominantly on the head and neck (3). Histologically, the specimens showed intercellular edema affecting the hair follicles with presence of mucin deposition in the external root sheath and sebaceous lobules (3). The cells of the sebaceous glands became stellate and separated and were found surrounded by the presence of mucin (Fig. 2). The process primarily affected the middle portions of the hair follicles with a variable amount of cellular infiltrate. Follow-up was available in four of the six cases. In three of the cases, Pinkus noted that the lesions resolved with a very small amount of superficial x-ray therapy and one case resolved without therapy. Clinically and histologically, the findings suggested to Pinkus an inflammatory reaction, particularly an infectious process (3). Pinkus suspected an as yet unidentified virus to be the possible cause (3). A follow-up study done by Coskey and Mehregan of fifty

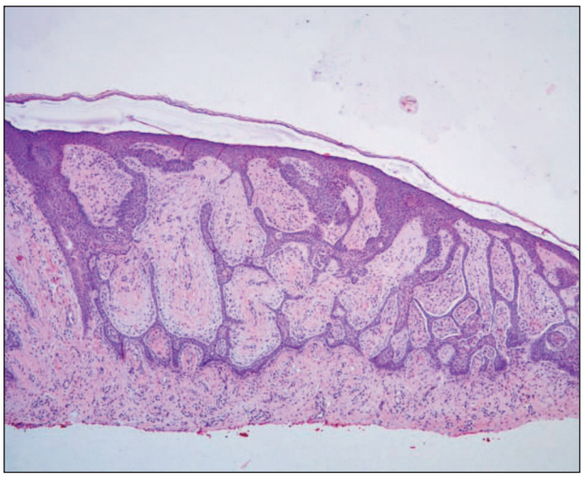

Fig. 1. Fibroepithelioma of Pinkus characterized by anastomosing basaloid strands surrounded by fibrovascular stroma (H&E; 40x).

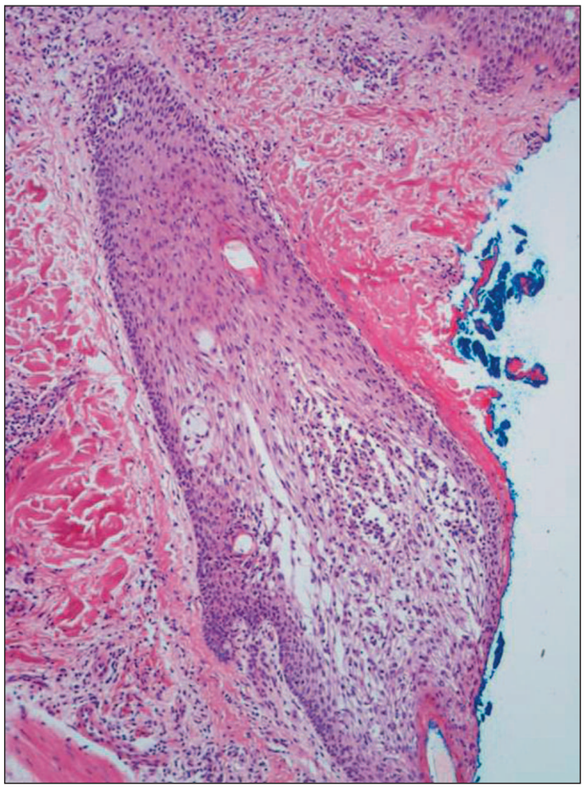

Fig. 2. Alopecia mucinosa marked by stellate epithelial cells in follicular infundibulum surrounded by mucin and mixed inflammation (H&E; 100x).

dermatologie_2_06 3.4.2006 12:55 Str. 104
proLékaře.cz | 23.11.2026

patients diagnosed at Pinkus' laboratory with alopecia mucinosa showed development of lymphoma in seven of these patients (4). Most of these cases were older patients with generalized skin involvement. In retrospect, Pinkus came to classify follicular mucinosis as a reaction pattern, which may be a primary inflammatory disease, which he termed "alopecia mucinosa" or may be secondary to an underlying lymphoma (1). The difficulty we still have today is in separating these two groups histologically. Both groups may show the presence of monoclonal rearrangement of the T-cell receptor. Therefore, clinical features and long term follow-up of these patients is important.

ECCRINE POROMA

In 1939, Pinkus presented a description of the acrosyringium, the intraepidermal portion of the eccrine duct (5). Prior to this it was believed that eccrine sweat diffused through the epidermal cells to the surface. However, Pinkus presented a description including a single layer of luminal cells surrounded by a single or multiple layers of poral epithelium. These cells were marked by the presence of intercellular desmosomes and the absence of tonofibrils. The nucleoli were inconspicuous and glycogen was present within the poral cells. In the very center of the eccrine duct was a PAS positive cuticle (5). Pinkus presented a series of five patients with papular lesions, which had been previously diagnosed as unusual variants of basal cell carcinoma (6). However, he felt that these lesions represented a tumor with features of poral differentiation. He cited the following features as suggestive of poral differentiation; the epithelium remained in close contact with the epidermis, but was relatively sharply delineated, and the cells were connected by desmosomes, however, there was absence of tonofibrils (6). Sweat ducts could be seen entering the tumor from below and the tumors were surrounded by a vascular stroma (Fig. 3). He classified the eccrine poroma as a benign tumor structurally related to the eccrine sweat gland (6).

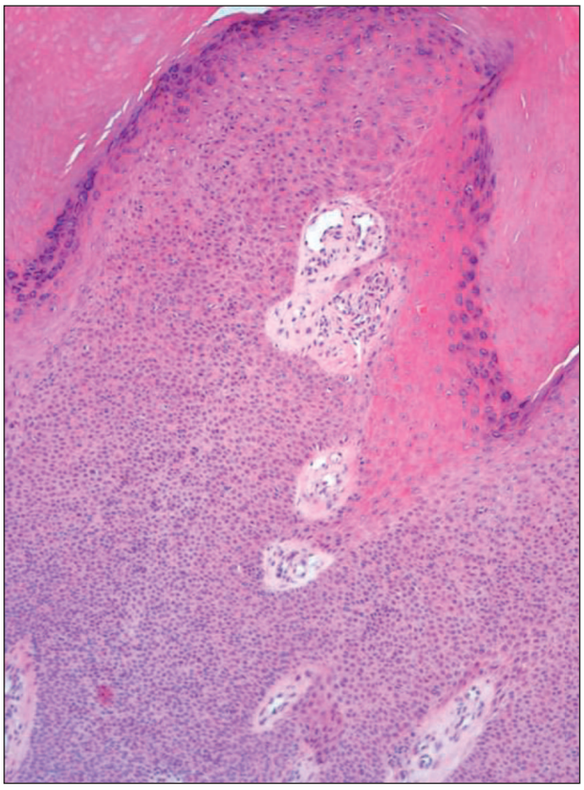

Fig. 3. Eccrine poroma shows sharp demarcation between uniform glycogen containing cells and adjacent epidermis (H&E; 100x).

EPIDERMOTROPIC ECCRINE CARCINOMA

Pinkus and Mehregan had the opportunity to view sections of an 82-year-old patient with a lesion on the left ankle, which spread to involve the leg and inguinal lymph nodes (7). Histologically, this patient's tumor featured nests of malignant cells in the epidermis and dermis, which formed a bridge to the epidermis, but were sharply demarcated from the adjacent epidermis. The cells showed no evidence of keratinization and had pale staining cytoplasm containing glycogen (Fig. 4). Intercellular desmosomes were present and tonofibrils were absent. Pinkus reasoned, "the eccrine duct, however, has all of the characteristics of a normal prototype of these tumor cells; glycogen content, absence of tonofibrils and presence of intercellular bridges. If we take into consideration that the primary tumor was on the foot, it seems not unreasonable to accept the metastatic tumors as epidermotropic eccrine carcinoma, or more precisely as malig-

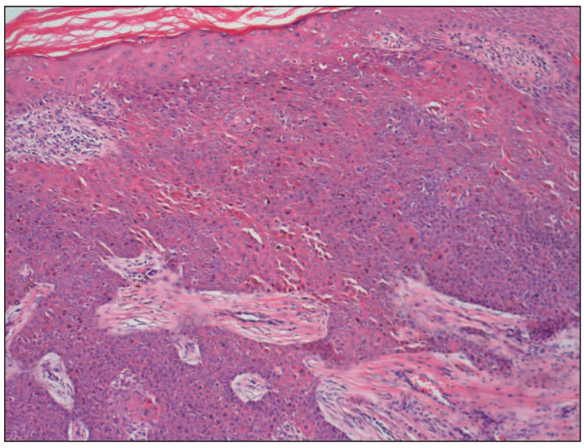

Fig. 4. Eccrine porocarcinoma showing sharp demarcation with epidermis. The lesion combines features of eccrine poroma with invasive growth pattern and nodular pleomorphism (H&E; 100x).

dermatologie_2_06 3.4.2006 12:55 Str. 105
proLékaře.cz | 23.11.2026

nant eccrine poroma" (7). However, Pinkus did not merely use this interesting case as an opportunity to present a new tumor. He used this as an opportunity to discuss the epidermal involvement by tumor cells, which he saw as being analogous to the situation seen in Paget's disease. He discussed the origin of Paget cells and used the term "Paget's phenomenon" as a parasitic existence of carcinoma cells of an extra-epidermal nature (7). The concept of colonization of the epidermis by cancer cells arose from his previous concept of the biologic independence of the epidermis and the adnexa. Pinkus proposed that the pale cells present in Paget's dermatoses and extramammary Paget's arose from migration from underlying breast glands or sweat ducts, a relatively new concept at the time of his discussion (7).

LARGE CELL ACANTHOMA

The large cell acanthoma represents another example of a neoplasm originally described by Dr. Pinkus, which was used to illustrate the larger concept of epidermal mosaicism (8). Pinkus had noted that when areas of epidermis are lost through ulceration, epithelium from adjacent hair follicles and sweat ducts helps to reconstitute the epidermis, which is indistinguishable from the original (8). He also noted that the epidermis in different parts of the body varies from region to region, for example, the epidermis in the palm of the hand is thicker with the presence of a well-developed stratum lucidum, whereas the dorsal hand reveals a relatively thinner epidermis without a stratum lucidum. Pinkus proposed two hypotheses to account for the preservation of the distinctive properties of various types of epidermis (8). The first possibility was that cells of the entire stratum germinativum are similar in all respects, and their distinctive differentiation is the result of inductive influence of the underlying dermis. The second possibility was that there are intrinsic differences of developmental origin between the germinal cells of various regions of the epidermis, that the epidermis is a mosaic. Pinkus used this opportunity to discuss several examples of two types of epidermal keratinocytes, each with its own morphologic and inheritable characteristics, which maintain their identity within an area of skin. The first example used was that of actinic keratosis [keratosis senilis], which shows a sharp border between dysplastic epidermal keratinocytes and the normal adnexal keratinocytes of the acrosyringium and acrotrichium. Pinkus presented the large cell acanthoma, a benign epidermal lesion marked by cells with larger than normal nuclei and cytoplasm (8). He noted that these cells undergo normal keratinization rather than parakeratosis as seen in actinic keratosis (Fig. 5). Dyskeratosis and nuclear pleomorphism are not present. Pinkus noted, "these cells give evidence of being genetically different from their surroundings, not only in their cytoplasm, but in the size and hyperchromasia of their nuclei" (8). Later authors have confirmed the presence of an increased amount of DNA in the nuclei of large cell acanthoma (9). Pinkus used this example of the newly described large cell acanthoma to illustrate this possibility of epidermal mosaicism (8).

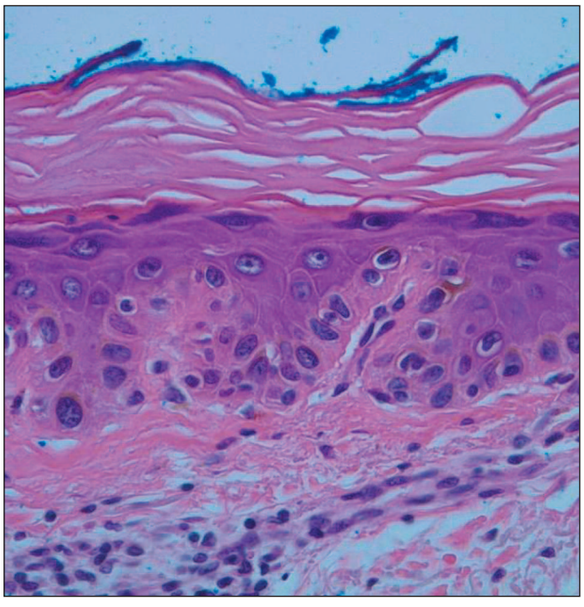

Fig. 5. Large cell acanthoma with large nuclei and increased cytoplasm, however, there is no evidence of nuclear atypia (H&E; 100x).

TRICHODISCOMA

Dr. Felix Pinkus first described the hair disc [Haarsheibe] in 1902 as a small round disc found in close association with hairs (10). It was found to consist of a richly vascularized dermal pad covered by thick epidermis containing Merkle cells and supplied by a thick myelinated nerve. Later Dr. Hermann Pinkus presented three patients with multiple papular tumors, which were asymptomatic (11). These were marked by a dome-shaped architecture, which was sharply limited by several rete ridges (11). The tumor was filled by fine fibrillar collagen, which contained numerous blood vessels and variable increased mucin deposition. These lesions were seen in close association with an adjacent hair follicle. A myelinated nerve branch may be seen at the base of the lesion. One of the patients presented with a combination of tumors including trichodiscoma, perifollicular fibroma, and acrochordons (11). In a short follow-up, there was no history of malignancy in this patient. However, several years later Birt, Hogg, and Dube' described patients with multiple hereditary fibrofolliculomas, trichodiscomas, and acrochordons associated with malignancy (12). The authors of this paper

dermatologie_2_06 3.4.2006 12:55 Str. 106
proLékaře.cz | 23.11.2026

had sent histologic slides of their patient to Dr. Pinkus who suggested the name fibrofolliculoma to describe the tumor of a well-formed hair follicle with surrounding anastomosing epithelial strands and a mucinous stroma.

TAPE STRIPPING

Pinkus was interested in the mechanism of epidermal renewal. As a medical student, tissue culture experiments initiated his interest in epidermal cell growth. In 1949, Dr. Warren Andrew postulated that the mitotic activity in the epidermis was inadequate to explain its renewal and that the epidermis was continually replenished by immigration of lymphocytes into the epidermis and transformation of these cells into keratinocytes (1). Pinkus' own work with tissue cultures led him to believe that this was unlikely, however, he could find no quantitative research on the mitotic activity of the epidermis (1). He turned to a technique first described by an anatomist in Prague, Dr. Jan Wolf (1). This technique involved stripping off layers of skin by repeated application of adhesive tape (1). Pinkus then reviewed biopsies of his own forearm after repeated tape stripping to see that there was an increased mitotic rate at 12, 24, 48, and 72 hours. Thus, Pinkus was able to illustrate that an increased mitotic rate along the basal cell layer was sufficient for regeneration of the epidermis (1).

REFERENCES

1. PINKUS, H. Etiology of an anatomist's discoveries in dermatology. *Am J Dermatopathol,* 1982, 4(2), p. 127–135.
2. PINKUS, H. Premalignant fibroepithelial tumors of skin. *AMA Arch Derm & Syph,* 1953, 67, p. 598–615.
3. PINKUS, H. Alopecia Mucinosa. *AMA Arch Derm & Syph,* 1957, 76, p. 419–426.
4. COSKEY, RJ., MEHREGAN, AH. Alopecia mucinosa. A follow-up study. 1970, 102(2), p. 193–194.
5. PINKUS, H. The wall of the intra-epidermal part of the sweat duct. *J Invest Derm,* 1939, 2, p. 175–186.
6. PINKUS, H, ROGIN, JR., GOLDMAN, P. Eccrine poroma. Tumors exhibiting features of the epidermal sweat duct unit. 1956, 74, p. 511–521.
7. PINKUS, H, MEHREGAN, AH. Epidermotropic eccrine carcinoma. A case combining features of eccrine poroma and Paget's dermatosis. *Arch Derm,* 1963, 88, p. 597–606.
8. PINKUS, H. Epidermal mosaic in benign and precancerous neoplasia (with special reference to large-cell acanthomas). *Acta Derm,* 1969–70, 64, 65, p. 53–59.
9. ARGENYI, ZB, HUSTON, BM, ARGENYI, EE, MAILLET, MW, HURT, MA. Large-cell acanthoma of the skin. A study by image analysis cytometry and immunohistochemistry. *Am J Dermatopathol,* 1994, 16(2), p. 140–144.
10. PINKUS, H. Pinkus' Haarscheibe and tactile receptors in cats. Science, 1964, 144, p. 891.
11. PINKUS, H, COSKEY, R, BURGESS, G. Trichodiscoma. A benign tumor related to Haarscheibe (Hair Disk). *J Invest Derm,* 1974, 63, p. 212–218.
12. BIRT, AR, HOGG, GR, DUBE, WJ. Hereditary multiple fibrofolliculomas with trichodiscomas and acrochordons. *Arch Dermatol,* 1977, 113(12), p. 1674–1677.

Došlo do redakce: 29. 9. 2005

Darius Mehregan, M.D.
Associate Clinical Professor of Dermatology
Wayne State University
Pinkus Dermatopathology Laboratory
1314 North Macomb St.
Monroe, Michigan, 48162, USA
E-mail: Darmehregan@Pinkuslab.com

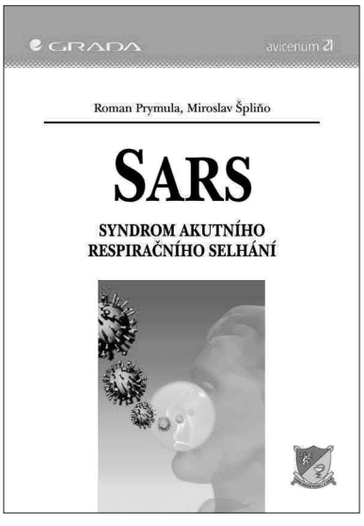

SARS – Syndrom akutního respiračního selhání

Roman Prymula, Miroslav Šplíňo

Publikace přináší ucelené a kvalitní zpracování mimořádně aktuálního tématu – průběhu pandemie 21. století. Zároveň dává důležité informace o hrozbě SARS v kombinaci s rizikem bioterorizmu, hrozící pandemií chřipky či ptačí chřipky… Určeno nejen epidemiologům, mikrobiologům a infekcionistům – ale i široké zdravotnické veřejnosti, která v ní najde poučení i informace, jak postupovat a jak se chránit při pandémii nejen SARS.

Vydala Grada Publishing v roce 2005, ISBN 80-247-1550-3, kat. číslo 1062, formát 15x21, brožovaná vazba , 144 stran, cena 195 Kč.

Objednávku můžete poslat na adresu: Nakladatelské a tiskové středisko ČLS JEP, Sokolská 31, 120 26 Praha 2, fax: 224 266 226, e-mail: nts@cls.cz