

Treatment of Patients with Central Serous Chorioretinopathy using Navigated Laser Photocoagulation

Tesař Jan, Šín Martin

Department of Ophthalmology, 1st Faculty of Medicine of Charles University and Military University Hospital, Prague, Czech Republic

Submitted to the editorial board: October 7, 2024

Accepted for publication: December 10, 2024

Available on-line: February 13, 2025

The authors of the study declare that no conflict of interests exists in the compilation, theme and subsequent publication of this professional communication, and that it is not supported by any pharmaceuticals company. The study has not been submitted to any other journal or printed elsewhere, with the exception of congress abstracts.



MUDr. Jan Tesař, FEBO

Correspondence address:

Oční klinika, Ústřední vojenská nemocnice – všeobecná fakultní nemocnice v Praze

U Vojenské nemocnice 1200

Praha 6

Česká republika

E-mail: jan.tesar@uvn.cz

SUMMARY

Aim: To report the results of treatment of patients with central serous chorioretinopathy treated with a Navilas laser.

Material and Methods: We retrospectively evaluated the results of the treatment of 39 eyes of 37 patients with acute form of central serous chorioretinopathy, who did not respond to conventional treatment. In these patients we performed focal laser treatment at the point of leakage (hotspot) using a Navilas guided laser. Results: 3 patients did not report for the check-up, of the remaining 36 eyes, complete liquid absorption was achieved in 32. Retreatment was necessary in 2 patients, choroidal neovascularization developed in one patient, and in one patient fluid absorption was not achieved even after retreatment.

Conclusion: Focal laser treatment of hotspots in patients with central serous chorioretinopathy is still a very effective treatment method. Juxtafoveolar lesions can also be treated with a high degree of safety using a Navilas navigation laser.

Key words: central serous chorioretinopathy, pachychoiridea, Navilas, hotspot

Čes. a slov. Oftal., 81, 2025, No. x, p.

INTRODUCTION

Central serous chorioretinopathy (CSC) is a disease of the macula characterized by serous ablation of the sensory epithelium (SE), often in association with ablation of the retinal pigment epithelium (RPE). It is classified within the group of pachychoroid diseases of the retina, characterized by dilation and hyperpermeability of the choroidal vessels, with an increase of hydrostatic pressure causing a disintegration of the Bruch's membrane and RPE [1]. The acute form of CSC is manifested in typical ablation of the SE without more pronounced changes in the outer segments of the photoreceptors, and has a high rate of spontaneous healing; 30–50% heal within 3 months [2]. The recurrent form is manifested in numerous repeating episodes of ablation of the sensory epithelium with spontaneous resorption, in which the length of duration of ablation is usually 3–6 months. Approximately 5–10% of patients transition to the chronic form, which is typified by the constant presence of serous fluid beneath the SE (3–6 months and longer), with its subsequent atrophy, irreversible changes in the RPE and permanent

deterioration of visual acuity. Choroidal neovascularization (CNV) [3] or cystoid macular edema (CME) may also appear.

The symptoms of the disease are typical and in the acute form incorporate central scotoma, frequently copying the shape of ablation of the SE in the macula. Patients often complain of experiencing vision as if "through water", flashing and reduction of contrast, or also reduction of image size (micropsia).

Risk factors include personality type A [4]. These individuals are described as having a more aggressive, competitive and nervous disposition. In most patients the level of catecholamines is raised, which leads to a higher permeability of the choroidal vessels [5]. Another risk factor is exogenous intake of corticosteroids. Cases have been described following systemic oral, inhalation and intravenous use [6–8]. A higher incidence of this disease has also been described in the case of Cushing's syndrome and pregnancy [9]. Central serous chorioretinopathy has also been described following the use of other pharmaceuticals, e.g. MEK inhibitors [10], phosphodiesterase inhibitors [11], pseudoephedrine [12] or oxymetazoline.

Epidemiologically this concerns the fourth most common retinal cause of deterioration of visual acuity. Men are affected approximately 6x more frequently than women [13]. The pathology most often affects the group of patients aged 39–51 years. In women the average age is higher. The disease is generally unilateral, but changes are frequently present in the RPE also in the other eye [14].

In pathophysiology the main changes are manifested in blood circulation in the choroid. Dilation occurs, with subsequent hyperpermeability of the choroidal vessels, which is well visible on ICG angiography (indocyanine green) [15]. With the aid of EDI (enhanced-deep imaging) we can illustrate thickening of the choroid often beyond a value of 300 μm [16].

Possibilities of therapy are focal laser treatment (ideally yellow laser with wavelength of 577 nm, which is absorbed in the RPE), as well as microsecond pulse laser (MSP) and photodynamic therapy (PDT) with the use of the photosensitive substance Visudyne (verteporfin).

MATERIAL AND METHODS

In our retrospective study we observed 39 eyes of 37 patients in the period between 2018 and 2022 (Table 1). The ratio of men to women was 31:6, the average age was 46 years ± 6.7 (range 33–62, median 44). The study included eyes with acute form of central serous chorioretinopathy treated using a conservative approach with the application of nonsteroidal anti-inflammatory drugs (NSAID) in the form of drops and antiedematous therapy (e.g. Aescin tbl.), in which resorption of the fluid beneath the sensory epithelium was not achieved even after 3 months. A scan was performed on the patients by means of optical coherence tomography (OCT) and fluorescence angiography using the instrument OCT Spectralis (Heidelberg Engineering, Germany). Patients in whom choroidal neovascularization (CNV) developed or in whom there was presence of a larger area of RPE atrophy with diffuse infiltration unsuitable for focal laser treatment were excluded from the study. Patients meeting the criteria were treated using the retinal laser Navilas 577s (OD – OS, Germany) with the aid of a visible spot in the place of hyperfluorescence, i.e. the “hotspot”. Scans from the early venous phases of angiogram, where localizations of the hotspot were the most precise, were transposed to the Navilas instrument with the aid of a USB disk. Fundus photography was performed on this instrument, after which laser treatment was planned (Table 2). The size of the spot was always 100 μm , the duration of the pulse 100 ms. The average energy was 90.7 mW ± 25.7 (range 60–160, median 80), the average number of spots was 3.46 ± 2.54 (range 1–12, median 3). The power of the laser was first of all titrated outside the macular region, and after determination of the ideal energy of the laser the treatment itself was performed in the place of the hotspot until a visible whitish spot was created on the scan. After the procedure the patients did not receive any further treatment, either local or general. A follow-up

Table 1. Characteristics of study group

Characteristics of study group	Results
Sex male:female	31:6
Average age	46 years ± 6.7
Entry visual acuity ETDRS	76.8 ± 5.4
Final visual acuity ETDRS	81.2 ± 4.4
CRT before LFK	403 μm ± 115.5
CRT after LFK	258 μm ± 32.3
Average duration of fluid resorption	47 days ± 24.1

Table 2. Laser parameters

Laser parameters	Values
Energy	90.7 mW ± 25.7
Number of laser spots	3.46 ± 2.54
Spot size	100 μm
Pulse duration	100 ms
Duty cycle (DC %)	10%
Hotspot distance from fovea	1591 μm ± 909.4

examination was conducted 1 month and 3 months after treatment, and subsequently according to the finding.

Navilas

The Navilas instrument is a retinal laser developed by the company OD – OS (Berlin, Germany). This is a yellow laser with a wavelength of 577 nm. As in the case of a classic laser, it provides the option of selecting the size of the spot, energy of the pulse and time duration of the laser. The laser works in continuous and micropulse mode. It has an exchangeable head with a lens for focal and peripheral treatment of the retina. Its advantage in comparison with other lasers is the possibility of obtaining a photograph of the patient's ocular fundus with subsequent interlay of the images from fluorescence angiography, angioOCT or classic OCT scans. The Navilas laser is equipped with highly effective tracking, which ensures the precision of placement of the laser in the required localization, which is especially important upon treatment of a lesion in close proximity to the fovea. Another advantage of Navilas is its clearly presented report on patient treatment (Figures 1 and 2).

RESULTS

Out of our cohort of 39 eyes only 36 (92%) were observed, because 3 patients failed to report for the check-up. It is reasonable to assume that their condition had improved to such an extent that they did not require further examination or treatment. From the observed cohort we record a high success rate of treatment. Only 4 patients recorded no improvement, and consequently required repeated tre-

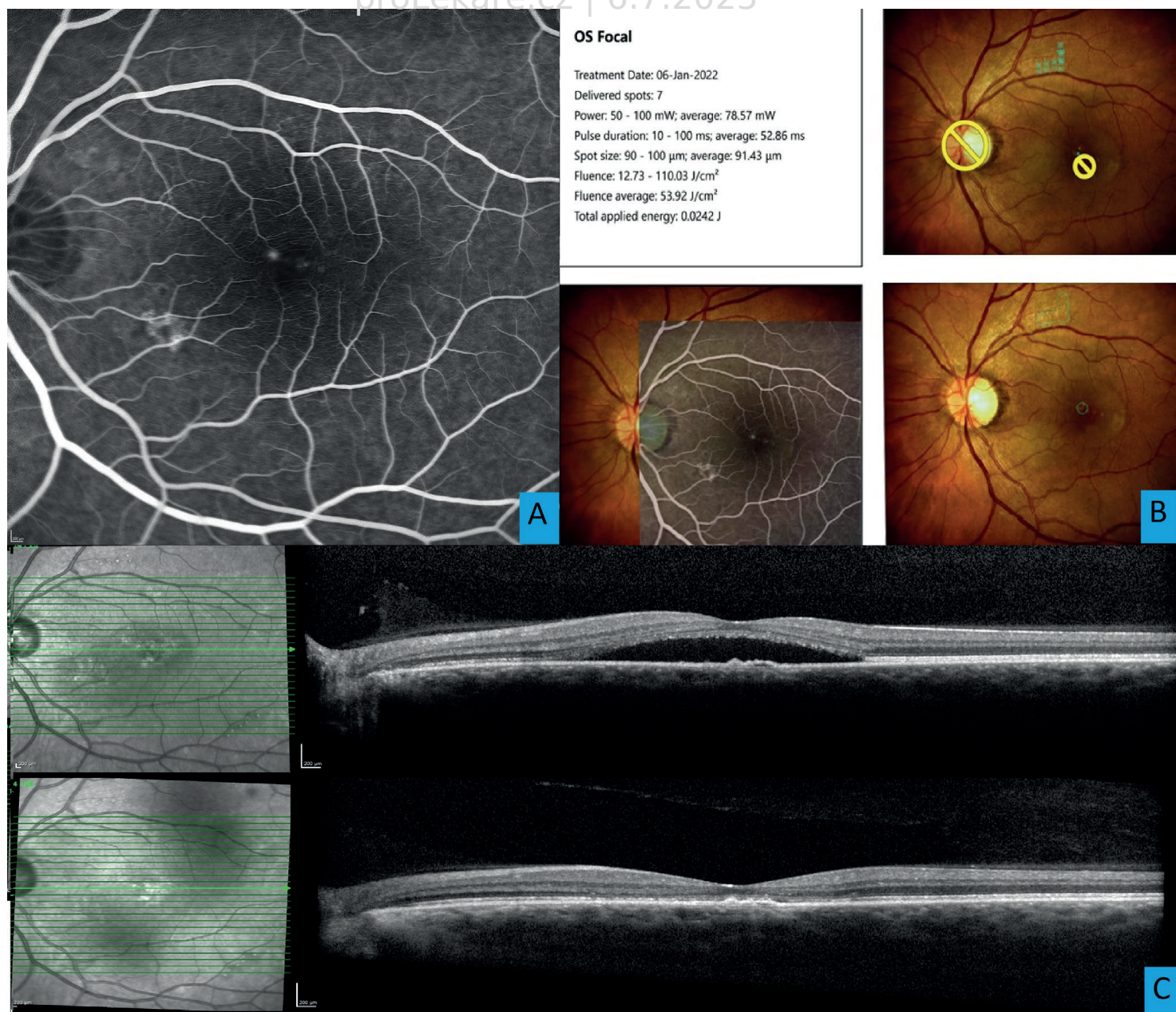


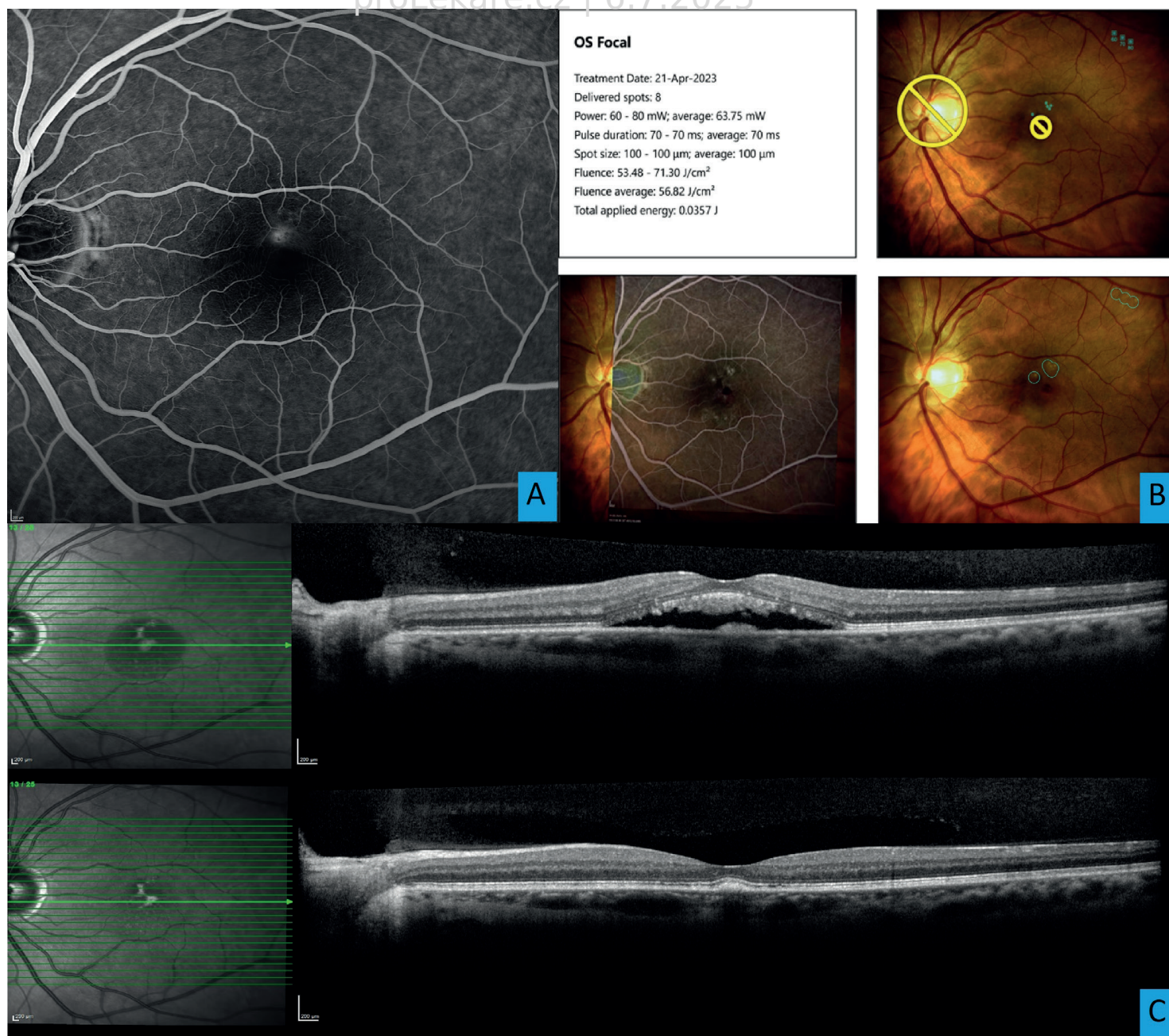
Figure 1. (A) Fluorescein angiography of a patient with central serous chorioretinopathy with an apparent juxtafoveolar hotspot, (B) Patient treatment report from Navilas– laser values, treatment plan and photo of the fundus after treatment, (C) Follow-up optical coherence tomography image (OCT) of a patient with sensory epithelium ablation before and after laser treatment

atment. In two of these patients resorption of the fluid was eventually achieved. In one of them CNV developed and it was necessary to commence anti-VEGF therapy. In the last patient resorption was not achieved even despite repeated laser treatments. In 5 patients recurrence of the condition occurred several months after complete resorption. The average time of resorption of fluid was 47 days \pm 24.1 (range 27–110, median 37), even though this parameter is influenced by the date of examination of the patient. Average central retinal thickness (CRT) was 403 μ m \pm 115.5 (range 237–624, median 387), after treatment this was reduced to 258 μ m \pm 32.3 (range 208–314, median 259), thus the difference was statistically significant ($p < 0.05$). We also observed thinning of central choroidal thickness from 419 μ m \pm 97.5 (range 227–573, median 411) to 379 μ m \pm 94.6 (range 190–543, median 392). It is necessary to note that in a large number of patients, even in EDI mode it was not possible to

image the outer limit of the choroid. Average best corrected visual acuity (VA) before treatment was 76.8 letters of ETDRS chart (range 60–80, median 78), after treatment 81.2 letters of ETDRS chart (range 67–90, median 82). This difference was also statistically significant ($p < 0.05$). We used a paired t-test for evaluation of the cohorts. An interesting measured parameter in this cohort was distance of the hotspot from the fovea. The average value was 1591 μ m (range 437–3935, median 1513). In the case that two or more hotspots were treated, the shorter of the distances is stated.

DISCUSSION

For a long time the standard treatment was photodynamic therapy (PDT), which in many publications serves as a comparative method. At present its use is decreasing mainly due to the inaccessibility of verteporfin and due to



Obrázek 2. (A) Fluorescein angiography of a patient with central serous chorioretinopathy with an apparent juxtafoveal hotspot, (B) Patient treatment report from Navilas– laser values, treatment plan and photo of the fundus after treatment, (C) Follow-up optical coherence tomography image (OCT) of a patient with sensory epithelium ablation before and after laser treatment

improvements in the field of micropulse laser treatment. Another disadvantage of PDT is potential atrophy in the location of application of the laser and potential general reaction to the photosensitive substance. Nevertheless, in several studies PDT has proven to be a superior method in comparison with observation [17], placebo [18], and in comparison with anti-VEGF [19].

The PLACE study compared PDT in a reduced (half-dose) regimen with a micropulse yellow laser. PDT was superior in terms of attained best corrected visual acuity, absorption of subretinal fluid, contrast sensitivity and also in change on the micropertimeter and the time at which the changes occurred [20].

However, in other studies a micropulse laser was demonstrated to be equally [21] or even more effective than photodynamic therapy [22].

The number of publications about treatment of patients with CSC using a visible spot with the aid of a Navilas laser is limited. In one of these studies, Zhou retrospectively investigated the results of treatment of 19 eyes. Best corrected VA improved from 0.37 to 0.62 decimally. Average subfoveal retinal thickness was reduced from $443.9 \pm 79.5 \mu\text{m}$ to $232.9 \pm 48.4 \mu\text{m}$. Absorption of the subretinal fluid was achieved in 13 out of 19 eyes (68%) after 3 months. All the observed parameters were statistically significant [23].

In another study Müller retrospectively analyzed data in 32 eyes with CSC treated with a visible spot with the aid of a Navilas laser. After 1 month the fluid was absorbed in 50% of patients, after 3 months in as many as 75%. There was also a significant improvement of VA [24]. The results were similar in other studies [25–27].

In the case of lasering with an above-threshold value of the laser, a question arises concerning the onset of a defect in the RPE and subsequent scotoma in the patient's visual field. Again, very few studies have been conducted on this subject, but in the majority of them no more pronounced effect was observed on the retina or on the patient's vision [28]. It appears that the use of a laser with a wavelength of 810 nm has a greater impact on generating a defect of the RPE and subsequent scotoma [29]. By contrast, other studies have demonstrated a clearly negative impact on the generation of defects in the RPE in comparison with micropulse mode [30]. In our cohort no greater defect of the RPE was observed that would cause subjective complaints, even though no microperimetric examination was conducted. One patient in our cohort developed CNV, but it is debatable as to whether this was in connection with treatment or with the underlying pathology.

Although the micropulse laser mode is the new gold standard in the treatment of patients with CSC, focal laser with the aid of a visible spot in the location of the hot-spot remains a highly effective and safe method of treatment for these patients. It is especially advantageous in patients with a clearly bordered hotspot. Upon the use of a navigation system, the precision and efficacy of treatment is dramatically increased. At our center we also

use treatment in micropulse mode, the results of which shall be included in further publications. The mechanism of absorption of the subretinal fluid after laser treatment has not been clarified to date. Possibilities are stimulation of the membrane pumps in the RPE cells, stimulation of healing and annealing of the RPE defect [31].

CONCLUSION

Even despite the amount of new therapeutic modalities, focal laser therapy remains an effective method of choice for the treatment of patients with central serous chorioretinopathy. In patients with a juxtafoveally deposited location of infiltration, use of the navigated laser Navigas is an advantage. In a large proportion of patients a suitable combination of methods such as focal treatment, micropulse laser, PDT and anti-VEGF can prevent irreversible changes in the outer layers of the retina and the subsequent deterioration of quality of vision which we can see in the case of long-untreated chronic forms. It is necessary to point out that regimen measures and a holistic approach to the patient are an essential component of treatment. The above-mentioned methods most probably concentrate rather on addressing the consequences and not on the fundamental basis of the disease itself.

REFERENCES

- Maruko I, Iida T, Sugano Y, Ojima A, Ogasawara M, Spaide RF. Subfoveal choroidal thickness after treatment of central serous chorioretinopathy. *Ophthalmology*. (2010) 117(9):1792-1799.
- Gilbert CM, Owens SL, Smith PD, Fine SL. Long-term follow-up of central serous chorioretinopathy. *Br J Ophthalmol*. 1984;68:815-820.
- Manethová K, Ernest J. Retrospective analysis of the presence of choroidal neovascularisation using optical coherence tomography angiography in the treatment of chronic central serous chorioretinopathy with the aid of photodynamic therapy. *Cesk Slov Oftalmol*. 2021;77(3):122-131.
- Yannuzzi LA. Type A behavior and central serous chorioretinopathy. *Trans Am Ophthalmol Soc*. 1986;84:799-845.
- Iida T, Yannuzzi LA, Spaide RF, Borodoker N, Carvalho CA, Negrão S. Cystoid macular degeneration in chronic central serous chorioretinopathy. *Retina*. 2003 Feb;23(1):1-7.
- Carvalho-Recchia CA, Yannuzzi LA, Negrão S, et al. Corticosteroids and central serous chorioretinopathy. *Ophthalmology*. 2002 Oct;109(10):1834-1837.
- Daruich A, Matet A, Dirani A, et al. Central serous chorioretinopathy: Recent findings and new physiopathology hypothesis. *Prog Retin Eye Res*. 2015 Sep;48:82-118.
- Karadimas P, Kapetanios A, Bouzas EA. Central serous chorioretinopathy after local application of glucocorticoids for skin disorders. *Arch Ophthalmol*. 2004 May;122(5):784-786.
- Haimovici R, Koh S, Gagnon DR, Lehrfeld T, Wellik S. Central Serous Chorioretinopathy Case-Control Study Group. Risk factors for central serous chorioretinopathy: a case-control study. *Ophthalmology*. 2004 Feb;111(2):244-249.
- McCannel TA, Chmielowski B, Finn RS, et al. Bilateral subfoveal neurosensory retinal detachment associated with MEK inhibitor use for metastatic cancer. *JAMA Ophthalmol*. 2014 Aug;132(8):1005-1009.
- Aliferis K, Petropoulos IK, Farpour B, Matter MA, Safran AB. Should central serous chorioretinopathy be added to the list of ocular side effects of phosphodiesterase 5 inhibitors? *Ophthalmologica*. 2012;227(2):85-89.
- Pierce KK, Lane RG. Central serous chorioretinopathy associated with the use of ephedra. *Retin Cases Brief Rep*. 2009 Fall;3(4):376-378.
- Kitzmann AS, Pulido JS, Diehl NN, Hodge DO, Burke JP. The incidence of central serous chorioretinopathy in Olmsted County, Minnesota, 1980-2002. *Ophthalmology*. 2008 Jan;115(1):169-173.
- Kim YT, Kang SW, Bai KH. Choroidal thickness in both eyes of patients with unilaterally active central serous chorioretinopathy. *Eye (Lond)*. 2011 Dec;25(12):1635-1640.
- Uyama M, Matsunaga T, Matsubara I, Fukushima I, Takahashi K, Nishimura T. Indocyanine green angiography and pathophysiology of multifocal posterior pigment epitheliopathy. *Retina*. 1999;19(1):12-21.
- Imamura Y, Fujiwara T, Margolis R, Spaide RF. Enhanced depth imaging optical coherence tomography of the choroid in central serous chorioretinopathy. *Retina*. 2009;29(10):1469-1473.
- Lai TY, Wong RL, Chan WM. Long-Term Outcome of Half-Dose Verteporfin Photodynamic Therapy for the Treatment of Central Serous Chorioretinopathy (An American Ophthalmological Society Thesis). *Trans Am Ophthalmol Soc*. 2015;113:T8.
- Chan WM, Lai TY, Lai RY, Liu DT, Lam DS. Half-dose verteporfin photodynamic therapy for acute central serous chorioretinopathy: one-year results of a randomized controlled trial. *Ophthalmology*. 2008 Oct;115(10):1756-1765.
- Lee JY, Chae JB, Yang SJ, Kim JG, Yoon YH. Intravitreal bevacizumab versus the conventional protocol of photodynamic therapy for treatment of chronic central serous chorioretinopathy. *Acta Ophthalmol*. 2011;89:e293-e294.
- van Dijk EHC, Fauser S, Breukink MB, et al. Half-dose photodynamic therapy versus high-density subthreshold micropulse laser treatment in patients with chronic central serous chorioretinopathy: the PLACE trial. *Ophthalmology*. 2018;125:1547-1555. doi: 10.1016/j.ophtha.2018.04.021
- Roca JA, Wu L, Fromow-Guerra J, et al. Yellow (577 nm) micropulse laser versus half-dose verteporfin photodynamic therapy in eyes with chronic central serous chorioretinopathy: results of the Pan-American Collaborative Retina Study (PACORES) Group. *Br J Ophthalmol*. 2018;102(12):1696-1700. doi:10.1136/bjophthalmol-2017-311291
- Ntomoka CG, Rajesh B, Muriithi GM, Goud A, Chhablani J. Comparison of photodynamic therapy and navigated microsecond laser for chronic central serous chorioretinopathy. *Eye (Lond)*. 2018;32(6):1079-1086. doi:10.1038/s41433-018-0029-z

23. Zhou F, Yao J, Jiang Q, Yang W. Efficacy of Navigated Laser Photocoagulation for Chronic Central Serous Chorioretinopathy: A Retrospective Observational Study. *Dis Markers*. 2022 Apr;20;2022.
24. Müller B, Tatsios J, Klöner J, Pilger D, Jousen AM. Navigated laser photocoagulation in patients with non-resolving and chronic serous chorioretinopathy. *Graefes Arch. Clin. Exp. Ophthalmol*. 2018;256:1581-1588.
25. Menghani R, Lu S. Case Series of Central Serous Chorioretinopathy (CSR) Treated with the Novel Navilas Navigated Laser System. *Invest. Ophthalmol. Vis. Sci*. 2012;53(14):5846.
26. Jay C, Padmaja KR, Annie M, Subhadra J, Kozak I. Navigated focal laser photocoagulation for central serous chorioretinopathy, *Clinical Ophthalmology*, 2014;8:543-1547.
27. Maltsev DS, Kulikov AN, Chhablani J. Clinical Application of Fluorescein Angiography-Free Navigated Focal Laser Photocoagulation in Central Serous Chorioretinopathy. *Ophthalmic Surg Lasers Imaging Retina*. 2019 Apr 1;50(4):e118-e124. doi: 10.3928/23258160-20190401-16
28. Chhablani, J, Kalra, G, Alkwatli, L. et al. Safety of various parameter sets with navigated microsecond pulsing laser in central serous chorioretinopathy. *Int J Retin Vitro*. 2021;7:62. doi.org/10.1186/s40942-021-00335-3
29. Hirano T, Iesato Y, Imai A, Toriyama Y, Kikushima W, Murata T. Effect of Laser wavelength on delivering appropriate laser burns through the opaque lens using a pattern scan laser. *Ophthalmic Res*. 2014;51(4):204-209.
30. Wang J, Quan Y, Dalal R, Palanker D. Comparison of Continuous-Wave and Micropulse Modulation in Retinal Laser Therapy. *Invest Ophthalmol Vis Sci*. 2017 Sep 1;58(11):4722-4732. doi: 10.1167/iov.17-21610
31. Kaye R, Chandra S, Sheth J, Boon CJF, Sivaprasad S, Lotery A. Central serous chorioretinopathy: an update on risk factors, pathophysiology and imaging modalities. *Prog Ret a Eye Res*. 2020;79:p. 100865. doi: 10.1016/j.preteyeres.2020.100865