

Recurrent Congenital Cytomegalovirus Chorioretinitis in a Newborn. A Case Report

Kašpráková Martina¹, Timkovič Juraj^{1,2}, Širůček Petr^{3,4},
Matyáščíková Iveta⁵, Němčanský Jan^{1,2}

¹Clinic of Ophthalmology, University Hospital Ostrava, Czech Republic

²Department of Craniofacial Surgery, Faculty of Medicine, University of Ostrava, Czech Republic

³Clinic of Infectious Medicine, University Hospital Ostrava, Czech Republic

⁴Department of Clinic Subjects, Faculty of Medicine, University of Ostrava, Czech Republic

⁵Department of Neonatology, University Hospital Ostrava, Czech Republic

Submitted to the editorial board: October 13, 2024

Accepted for publication: February 18, 2025

Available on-line: May 5, 2025

The authors of the study declare that no conflict of interests exists in the compilation, theme and subsequent publication of this professional communication. The study has not been submitted to any other journal or printed elsewhere, with the exception of congress abstracts and recommended procedures. It is not supported by any pharmaceuticals company.



MUDr. Martina Kašpráková

Correspondence address:

Oční klinika Fakultní nemocnice Ostrava
17. listopadu 1790/5
708 52 Ostrava – Poruba
Czech Republic
E-mail: martina.kasprakova@fno.cz

SUMMARY

Purpose: To describe the clinical course, treatment, and subsequent care of a full-term newborn with atypical, unilateral, recurrent cytomegalovirus chorioretinitis.

Case report: The perinatal period of a full-term newborn girl was complicated by the development of petechiae on the skin. The initial laboratory findings were notable for thrombocytopenia, hyperbilirubinemia, and polycythemia. An ultrasound of the brain revealed cystic changes in the area of the lateral ventricles. MRI confirmed pseudocystic periventricular changes with periventricular calcifications. PCR testing confirmed CMV positivity, and the condition was diagnosed as congenital CMV infection requiring systemic treatment with ganciclovir. Indirect ophthalmoscopy revealed nonspecific lucency in the central area of the right eye, with several small hemorrhages on the retinal periphery. Although systemic therapy was initiated promptly, the original lesion reactivated multiple times on its periphery over the following months. The lesions were gradually healed, with pigmented scarring limiting the visual function of the affected eye.

Conclusion: In contrast with the focal changes in the peripheral retina observed in adults, congenital CMV infection affecting children is characterized by macular involvement. The degree of visual impairment is directly proportional to the extent of reparative scarring affecting the central retina. From the perspective of prognosis and prevention of potential late retinal complications, screening and regular ophthalmological examinations are essential.

Key words: cytomegalovirus, chorioretinitis, childhood, ganciclovir

Čes. a slov. Oftal., 81, 2025, No. x, p.

INTRODUCTION

Congenital cytomegalovirus chorioretinitis (cCMV) is the most common viral infection, affecting 0.5–2% of live born children. The human cytomegalovirus (CMV), known also as human herpes virus 5, belongs to the group of betaherpetic viruses of the Roseolovirus genus [1]. cCMV is characterized by vertical, intrauterine transmission, in which the source of infection for the fetus is the mother who has experienced CMV primo-infection, less frequently upon reactivation of the infection during pregnancy. Vertical transmission may also occur during or after birth, for example through the means of infected mother's milk [1–3].

The symptoms of infection appearing after birth may be of varying severity, in which clinical symptoms are

present in only 10% of children. Their incidence is directly proportionate to the probability of infection of the mother in the early phases of pregnancy. The most serious form of congenital infection is termed cytomegalic inclusion body disease. The symptoms are similar to other congenital infections from the TORCH group (toxoplasmosis, rubeola, cytomegalovirus, herpes simplex virus). They include prematurity, hypertrophy, hepatosplenomegaly, prolonged newborn jaundice, thrombocytopenic purpura, intracerebral calcification, neurological symptomatology (hypertonia or hypotonia, cramps), mental retardation and retarded growth. Infection with cCMV may also be the cause of repeated miscarriages [2–5].

Ocular manifestations of the infection include changes on the anterior segment of the eye – microphthalmia, an-

terior polar cataract, corneal stromal scarring and changes on the posterior segment – chorioretinitis with or without hemorrhagic component, peripheral vasculitis, retinal scarring and atrophy of the optic nerve papilla [4].

Laboratory diagnosis is based on demonstrating positivity of IgM, IgG antibodies in serum with low avidity and positivity of PCR (DNA) CMV in blood and urine. Auxiliary parameters may include raised level of lactate dehydrogenase (LD), alanine aminotransferase (ALT) and aspartate aminotransferase (AST), as well as relative lymphocytes in leukogram and thrombocytopenia.

Treatment consists in parenteral administration of ganciclovir in a dose of 6 mg/kg twice per day at an interval of 12 hours over a period of six weeks. In connection with the further development of the clinical finding it is possible to continue up to six months with valganciclovir perorally (individually prepared capsules from pharmacy) in a dose of 16 mg/kg twice per day at an interval of 12 hours perorally until negativity of viremia and ideally also viruria. Passive immunization with the anti-CMV IgG antibody is not available in the Czech Republic.

CASE REPORT

The girl under observation was born from the mother's third uncomplicated pregnancy in the 37th week of gestation, spontaneously head first, without complications, with a birth weight of 2150 grams and a length of 43 centimeters. Screening of the mother for *Streptococcus agalactiae* was negative. At the initial pediatric examination the girl was cardiopulmonary compensated, spontaneously ventilating, the overall physical finding was without any remarkable features. The development of petechiae on the skin appeared one day after birth. Laboratory tests determined thrombocytopenia (70 billion/L), polycythemia and positive inflammation markers (IL-6 > 842 pg/ml), as a result of which the girl was transferred to the University Hospital in Ostrava. The infant was administered general parenteral nutrition, as well as a dual combination of antibiotic treatment (ampicillin, gentamicin). Phototherapy was commenced due to hyperbilirubinemia. Ultrasonography of the brain detected a finding of a porencephalic cyst in the parenchyma. Blood samples were taken for serological examination to a TORCH panel (*Toxoplasma gondii*, Rubella, Cytomegalovirus, Herpes simplex virus). Serologically (Complement fixation reaction 128, positive IgM and IgG with avidity 51%) and using the PCR method, positivity of cytomegalovirus (CMV) 3.5×10^4 IU/ml was confirmed in the blood. The infection specialist evaluated the finding as congenital cytomegalovirus infection and indicated intravenous therapy with ganciclovir. A subsequent MR examination of the CNS demonstrated pseudocystic periventricular reconstruction in the left parietal region, small periventricular pseudocysts with calcifications and bilateral dilation of the temporal horns of the lateral ventricles. (Figure 1.) The image was taken during a brain MRI scan.

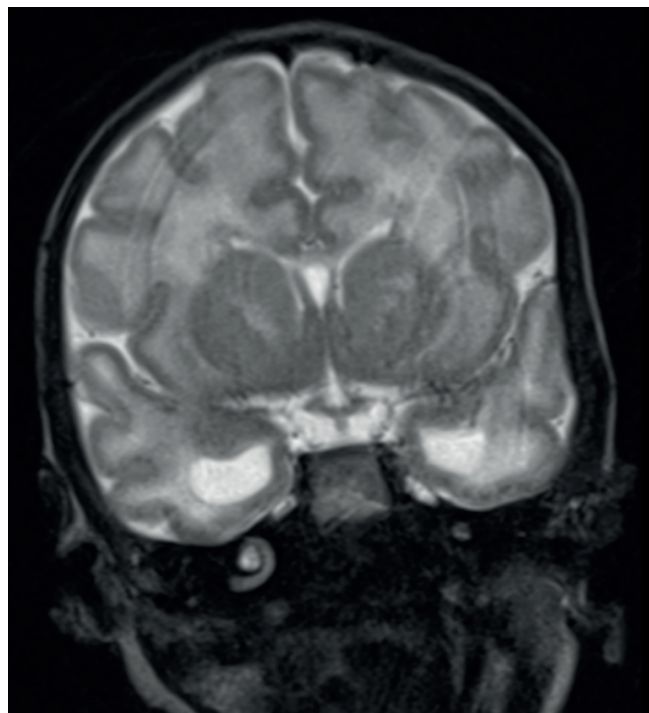


Figure 1. Bilateral dilation of the temporal horns of the lateral ventricles on the brain MRI

The first ophthalmological examination of the infant was conducted as part of interdisciplinary cooperation in the 40th week after conception. The finding on the anterior segment was physiological. Indirect ophthalmoscopy determined nonspecific clarification in the area of the central landscape of the right eye, with a number of small hemorrhages on the retinal periphery (Figure 2). With regard to positivity of PCR for cytomegalovirus infection, the finding on the ocular fundus was evaluated as an active chorioretinal lesion process.

The administered peroral therapy with valganciclovir brought about a progressive stabilization of the finding on the ocular fundus in the form of a finely pigmented scar (Figure 3). Images 2, 3 and 4 obtained using the instrument Phoenix Icon.

In the seventh month of life the girl was acutely hospitalized due to the repeat development of full-body petechiae. CMV (DNA) PCR in blood was 57 000 IU/ml, in urine 1 000 000 IU/ml. A follow-up examination of the ocular fundus demonstrated reactivation on the periphery of the original lesion. After a seven-day parenteral cycle with ganciclovir, viremia decreased to 3640 IU/ml and current long-term stabilization of the local retinal finding took place in the form of a pigmented scar, which limits the girl's visual functions in the right eye (Figure 4). At the end of the observation period we examined visual acuity with a preferential looking test, with an unreliable result. The child fixed her gaze on a moving object and turned towards the light. At the last follow-up examination by the infection specialist, the level of viremia had decreased to < 30 IU/ml and viruria was negative, which led to the termination of virostatic peroral medication in the 10th month of life.

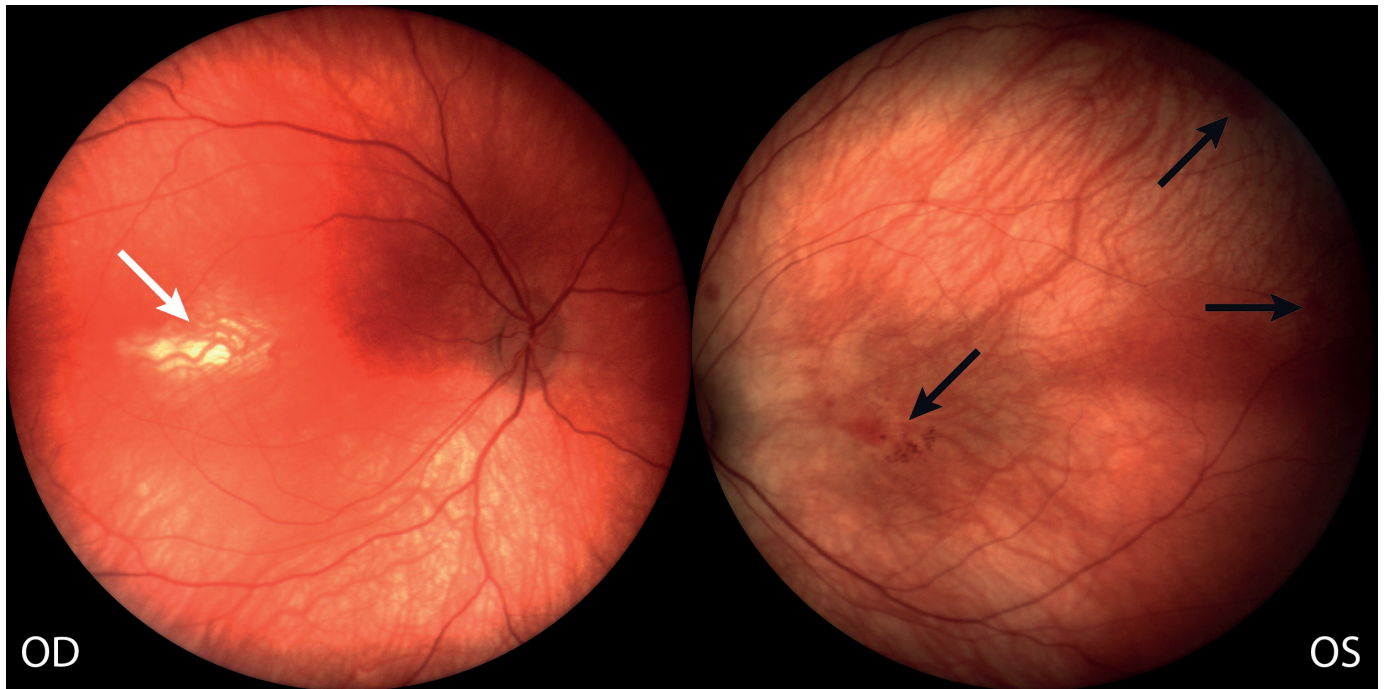


Figure 2. Nonspecific hyperintensity in the central region of the right eye (white arrow), with several small hemorrhages in the central area and periphery of the retina of the left eye (black arrows)

OD – right eye, OS – left eye

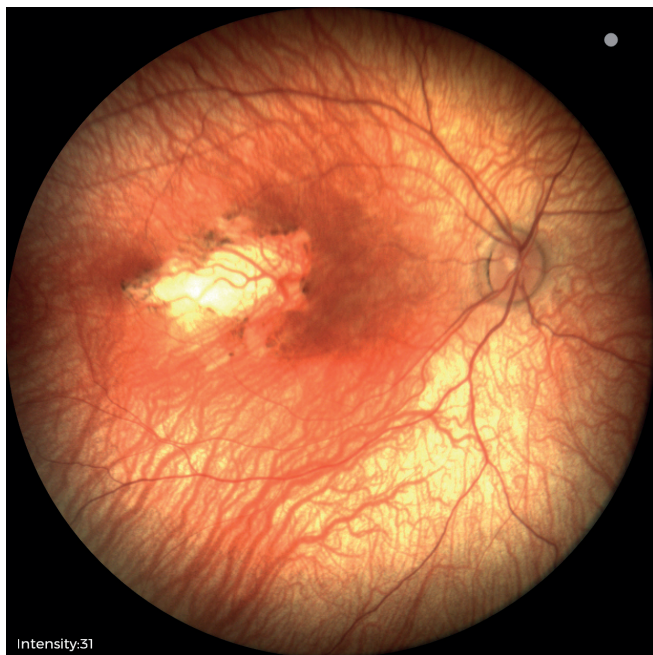

Figure 3. Partially pigmented scar in the central region of the right eye

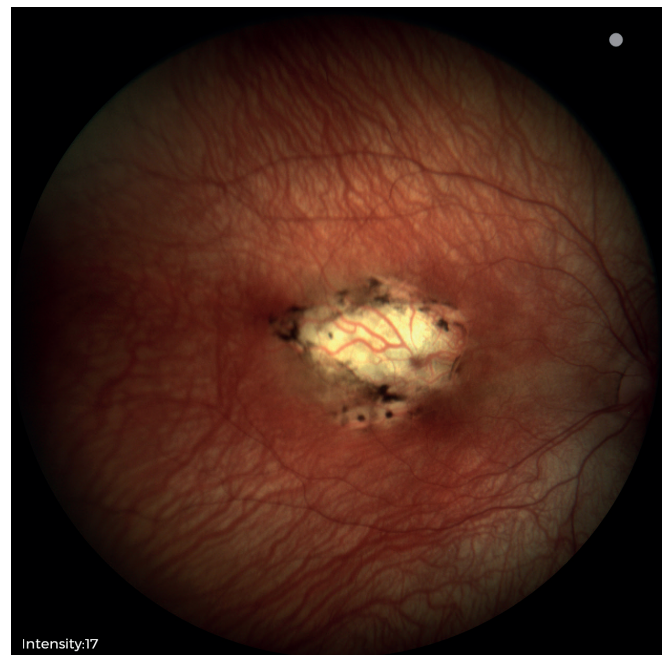

Figure 4. Pigmented retinal scar in the right eye after several reactivations and parenteral ganciclovir treatment

DISCUSSION

Congenital CMV infection has an asymptomatic course in approximately 90% of infected children. According to the available data, in 8–15% of cases of originally asymptomatic children manifestations may appear at a later age. In approximately 50–60% of symptomatic children we can observe general and ocular manifestations, in

which ocular complications can be expected in 5–30% of infected children [1,4,6]. The most common ocular manifestation of cCMV infection is central chorioretinitis, occurring in 25–28% of symptomatic individuals [6,7].

In the literature it is also possible to find isolated cases associated with severe malformations or an atypical course on the ocular fundus. In 1987 a case of a child with cyclopia, holoprosencephaly associated with cCMV

infection was described. In holoprosencephaly this concerns a developmental defect of the brain, characterized by an undeveloped or incomplete separation of one hemisphere of the brain [8]. This concerned a child without prenatally detected complications, born in the 36th week of gestation with a birth weight of 2400 grams. It was born with a single, centrally localized orbital cavity, containing a solitary eyeball with two irises, two upper and two lower eyelids, with no nose [8].

A rare case of ocular manifestation of cCMV was also observed by doctors from Japan, who described severe vascular retinal occlusion with arterio-venous anastomoses in a boy born in the 36th week of gestation with a birth weight of 1860 grams. The finding dramatically regressed following general therapy with ganciclovir [6].

In women infected with CMV infection, either primary or recurrent, diagnosis is difficult, since most women are asymptomatic. If symptomatology appears it is very nonspecific, often dominated only by increased fatigue and subfebrile condition. After illness the virus is excreted over a long period through urine or saliva [1–3].

Most infants with confirmed cCMV infection are born to women with preexisting seroimmunity to CMV. As a result, routine prenatal screening in the sense of sampling the amniotic fluid for PCR examination is not recommended due to its low yield. Furthermore, this concerns an invasive examination which is associated with a higher risk of premature termination of pregnancy [9].

Treatment of newborn cCMV infection consists in the administration of six-month virostatic therapy with valganciclovir, commencing already in the first month of the child's life. An extended length of treatment demonstrated better results in preventing severe affliction of hearing and neurological development in newborns with medium-severe to severe symptomatic infection. Treatment with valganciclovir and CMV hyperimmune globulin has the potential to reduce the viral load. Both medications have been used as potential therapeutic options for reducing vertical transmission of the infection during pregnancy [9].

Another option to be discussed is the administration of treatment intravitreally. A case of partial regression of a local retinal finding has been described in a girl with cCMV infection in the form of peripheral vasculitis following intravitreal administration of Foscarnet (virostatic, pyrophosphate analogue of DNA polymerase inhibitor) in a dose of 0.05 ml of solution with a concentration of 2.4 mg/ml, which was administered in three injections together with general parenteral therapy. However, even despite combined therapy, after an initial regression of peripheral vasculitis a reactivation of the infection took place during the further course in the form of central chorioretinitis, which after a further cycle of parenteral therapy was healed with a pigmented scar [10]. In the Czech Republic the indication criteria for the Foscarnet preparation are regulated by the State Institute for Drug Control. The medication can be administered in the case of sight-threatening illness caused by cytomegalovirus only in patients with acquired immune deficiency syndrome

(AIDS). Furthermore, to date this type of treatment can only be used in an off-label regime in intraocular administration. However, it shall be necessary in future to further verify the optimal timing, use, dosage and systemic safety of this type of treatment in this indication in children in the form of larger, ideally multicentric trials.

In 2012 a similar case of a newborn was described also by authors from the USA who had used ganciclovir administered intravitreally in the treatment of cCMV infection. In this case the infection was manifested in hemophthalmos in one eye and peripheral vasculitis in the other. The treatment was commenced with parenteral ganciclovir in a dose of 6 mg/kg 2x per day and intravitreal application of ganciclovir in a concentration of 2 mg in 0.04 ml of saline solution [11]. After three intravitreal injections and general treatment, the finding in the eye affected with hemophthalmos remained unchanged, while in the eye with peripheral vasculitis the authors recorded suppression of inflammatory infiltration of the blood vessels. However, reliable data resting upon a larger, ideally multicentric study are still lacking in order to verify the effectiveness of intravitreal application of ganciclovir in this indication in newborns. It is possible to assume that all these options could represent a good alternative for patients with adverse effects or allergies to general therapy, which could substantially reduce the time of administration of general therapy and thereby improve patient compliance. With reference to the favorable therapeutic response to parenteral therapy, intravitreal application of these medications was not indicated in the case of our patient.

An important aspect of general treatment of cCMV is not only virostatic therapy, but also extensive interdisciplinary cooperation, including essential follow-up care. Among other factors it is necessary to ensure regular follow-up examinations, ideally by an experienced pediatric ophthalmologist, to plan visual stimulation and in the case of necessity also follow-up pleoptic care. In the case of a poor prognosis of affliction of sight, it is recommended to inform the parents of options for support, inclusion of the child in associations or organizations caring for children with special needs, so that they have access to special optic or assisting aids, thus ensuring minimal impairment of the child's psychological, emotional and social development [12].

The fact that timely detection of ocular complications caused by cCMV infection is of crucial importance for preventing loss of sight and improving the long-term quality of life of children affected with this disease is also confirmed by a study conducted in Italy during the period of 2002 to 2022. The study observed 250 patients with confirmed cCMV infection, of whom 123 (49%) had symptoms of the disease. The patients underwent a series of visual, hearing and neurodevelopmental examinations. In 13% of the symptomatic patients, the pathology was verified on the posterior segment, where chorioretinitis (62.5%) and retinal scarring mainly predominated. A bilateral finding of chorioretinitis was described in 25%

of patients. Asymptomatic newborns did not have any described ocular abnormalities either in the short or long term. It is necessary to keep in mind the fact that chorio-retinal lesions are a relatively common finding at birth in newborns with symptomatic cCMV infection [13].

CONCLUSION

cCMV infection affecting children is characterized by a predilection for macular affliction, in contrast

with the affliction of the peripheral parts of the retina in adults. Screening and regular ophthalmological examinations for children with suspected cCMV infection are of fundamental importance with regard to timely detection, commencement of treatment, prognosis and prevention of potential development of later retinal complications. The degree of affliction of visual functions is directly proportionate to the extent of reparative scarring processes affecting the central retinal landscape.

REFERENCES

- Gabrani C, Mitsikas D, Giannakou K, Lamnisis D. Congenital Cytomegalovirus Infection and Ophthalmological Disorders: A Systematic Review. *J Pediatr Ophthalmol Strabismus*. 2023;60(2):86-94.
- Bale JF, Miner L, Petheram SJ. Congenital Cytomegalovirus Infection. *Curr Treat Options Neurol*. 2002;4(3):225-230.
- Bartošová D. Kongenitální cytomegalovirová infekce: diagnostika a terapie. *Pediatric pro praxi*. 2011;12(1):16-17.
- Ghekiere S, Allegaert K, Cossey V, Van Ranst M, Cassiman C, Castels I. Ophthalmological findings in congenital cytomegalovirus infection: when to screen, when to treat? *J Pediatr Ophthalmol Strabismus*. 2012;49(5):274-282.
- Lanzieri TM, Dollard SC, Bialek SR, Grosse SD. Systematic review of the birth prevalence of congenital cytomegalovirus infection in developing countries. *Int J Infect Dis*. 2014;22:44-48.
- Tagami M, Honda S, Morioka I, Iijima K, Yamada H, Nakamura M. An unusual case of congenital cytomegalovirus infection-related retinopathy. *BMC Ophthalmol*. 2016;16(1):81.
- Ozen Tunay Z, Derme T, Erginturk Acar D, Beser E. Retinal findings similar to retinopathy of prematurity in a term-infant with congenital cytomegalovirus infection. *Eur J Ophthalmol*. 2023;33(1).
- Byrne PJ, Silver MM, Gilbert JM, Cadera W, Tanswell AK. Cyclopia and congenital cytomegalovirus infection. *Am J Med Genet*. 1987;28(1):61-65.
- Pinninti S, Boppana S. Congenital cytomegalovirus infection diagnostics and management. *Curr Opin Infect Dis*. 2022;35(5):436-441.
- Tawse KL, Bauman CR. Intravitreal foscarnet for recurring CMV retinitis in a congenitally infected premature infant. *J AAPOS*. 2014;18(1):78-80.
- Oschman A, Murthy V, Kollipara R, Lord RK, Oluola O. Intravitreal Ganciclovir for Neonatal Cytomegalovirus-Associated Retinitis. A Case Report. *J Perinatol*. 2013;33(4):329-331.
- Němčanský J, Timkovič J. Vitreoretinální chirurgie v dětském věku. In: Šin M, editor. *Vitreoretinální chirurgie*. Praha: Maxdorf; 2022. p. 189.
- Salomè S, Ciampa N, Giordano M, et al. Ophthalmological impairment in patients with congenital cytomegalovirus infection. *Front Pediatr*. 2023;11:1251893.