

Two-year Results of Preserflo Microshunt use in Open-angle Glaucoma Surgery

Fialová Veronika^{1,2}, Váša Martin¹, Rozsival Pavel^{1,2,3},
Kalinová Jitka^{1,4}, Studnička Jan^{1,2,3}

¹VISUS, spol. s.r.o.

²Medical Faculty of Charles University in Hradec Králové, Czech Republic

³Department of Ophthalmology, University Hospital in Hradec Králové, Czech Republic

⁴Department of Thomayer Hospital, Prague, Czech Republic



MUDr. Veronika Fialová

Submitted to the editorial board: August 8, 2024

Accepted for publication: January 7, 2025

Available on-line: February 13, 2025

The authors of the study declare that no conflict of interest exists in the compilation, theme and subsequent publication of this professional communication, and that it is not supported by any pharmaceuticals company. The study has not been submitted to any other journal or printed elsewhere.

The study was presented in abbreviated form at Futurum Ophthalmologicum 2023, Špindlerův Mlýn.

Correspondence address:

VISUS, spol. s.r.o.,

Němcové 738

547 01 Náchod

Czech Republic

E-mail: veronika.fialova@ocni-visus.cz

Two-year results of Preserflo Microshunt use in Open-angle Glaucoma Surgery

Aim: To evaluate the safety and efficacy outcomes of PRESERFLO™ MicroShunt implantation in patients with primary open-angle glaucoma.

Material and Methods: Retrospective data analysis of 19 eyes of 12 patients, comprising 5 females and 7 males. The patients underwent surgery between August 2020 and February 2022. The follow-up period was 24 months after surgery. During the follow-up period, intraocular pressure (IOP), the need to apply topical antiglaucoma medication and its spectrum, visual field status, optic nerve target findings and postoperative complications were recorded. The indication for PRESERFLO™ MicroShunt implantation was primary open angle glaucoma (POAG), poorly controlled with maximum tolerated medical therapy.

Results: Average IOP was reduced from 19.05 ± 5.58 mmHg preoperatively to 11.47 ± 2.48 mmHg at 3 months postoperatively, 12.26 ± 2.48 mmHg at 6 months postoperatively, 14.0 ± 2.43 mmHg at 12 months postoperatively, 11.78 ± 2.37 mmHg at 18 months postoperatively, and 12.73 ± 2.51 mmHg at 24 months postoperatively ($p < 0.001$).

No antiglaucoma medication was required in 19 eyes 3 months after surgery, in 19 eyes 6 months after surgery, 19 eyes 12 months after surgery, 16 eyes 18 months after surgery and 15 eyes 24 months after surgery. One eye (5.26%) required monotherapy 18 months after surgery, and 2 eyes (10.52%) 24 months after surgery. Dual combination therapy was required 18 months after surgery in 2 eyes (10.52%) and 24 months after surgery in 2 eyes (10.52%). In the early postoperative period we found a loose conjunctival suture in 3 eyes, which was followed by resuturing in 1 eye. In the late postoperative period we found an obturated implant in 1 eye, which required implant replacement.

Conclusion: Our initial results suggest that the PRESERFLO™ MicroShunt glaucoma implant is an effective surgical technique with minimal postoperative complications, resulting in a statistically significant reduction in average IOP and discontinuation or reduction of topical antiglaucoma medication for 2 years after surgery.

Key words: primary open-angle glaucoma, minimally invasive glaucoma surgery, Preserflo MicroShunt, intraocular pressure

Čes. a slov. Oftal., 81, 2025, No. x, p.

INTRODUCTION

Glaucoma is a multifactorial, irreversible and progressive optic neuropathy [1–3]. It is characterized by a loss of retinal ganglion cells that form the optic nerve and transmit the electrophysiological signal of the visual circuit to the brain. It progressively causes atrophy of the optic nerve [2–3]. The pathology is manifested clinically in deterioration of visual acuity, loss of the visual field and ultimately blindness [1–3].

The most widespread type of glaucoma is primary open-angle glaucoma [5]. The sole modifiable factor

is intraocular pressure [3,5,6]. Conservative therapy is currently the treatment of first choice [4]. Patient compliance with pharmacotherapy need not be optimal. Laser and surgical methods can ensure a reduction of IOP if reducing pharmacotherapy is not sufficient [1,3,5]. Trabeculectomy and tube shunts are invasive surgical procedures which require thorough postoperative care, and for this reason minimally invasive glaucoma surgery (MIGS) has been developed, which provides a safer, simpler and less invasive alternative with quick postoperative convalescence, with the aim of completely removing or minimizing the need for local medication [1,3,5–7].

MIGS is capable of reducing IOP by various means through the aid of different anatomical pathways: (1) by increasing drainage of the trabecular meshwork and direct engagement of the Schlemm's canal, (2) by increasing uveoscleral drainage through the suprachoroidal pathways, or (3) by creating a link between the anterior chamber and the subconjunctival space for improving the drainage of intraocular fluid [1,3].

PRESERFLO™ MicroShunt uses a sub-Tenon's pathway by creating an artificial channel between the anterior chamber and the sub-Tenon's space, where the fluid is reabsorbed.

In 2012 PRESERFLO™ MicroShunt (Santen, Osaka, Japan) (MicroShunt, formerly known as InnFocus MicroShunt) obtained the Conformité Européenne mark, and in 2021 received the approval of Health Canada and Therapeutic Goods Administration of Australia for progressive primary open-angle glaucoma which is poorly controlled with the maximum possible tolerated anti-glaucoma medication. PRESERFLO™ MicroShunt is a 8.5 mm long (70 µm lumen and 350 µm external diameter) glaucoma filtration surgical implant composed of poly(styrene-block-isobutylene-block-styrene), highly biocompatible and bioinert material. The MicroShunt is inserted by an ab externo procedure. After implantation the proximal end of the implant is in the anterior chamber parallel to the iris, and the distal end is located beneath the conjunctiva and Tenon's fascia, approximately 6 mm behind the limbus, which enables filtration of the intraocular fluid via the lumen implant in order to form a filtration cushion (Fig. 1). Implantation of a PRESERFLO™ MicroShunt can be performed separately or in combination with cataract surgery, and is supplemented with the application of mitomycin C into the sub-Tenon's space in order to prevent postoperative scarring and failure of filtration [8]. The most important innovation is self-regulating drainage based on the Hagen-Poiseuille equation via the smaller lumen [1,3,5,9–13].

The current indication is progressively mild to medium-severe open-angle glaucoma which is poorly controlled with the maximum possible tolerated anti-glaucoma medication and a healthy, freely mobile conjunctiva. Adverse effects are rare. The most common include transitional hypotonia, shallow anterior chamber, choroidal ablation and hyphema. All these complications, if treated correctly, subside within a short time without the risk of threat to sight [1,3,5,9,10].

COHORT AND METHOD

A total of 19 eyes of 12 patients, comprising 5 women and 7 men with an average age of 72 years (61–84 years), were evaluated as part of a retrospective study. The follow-up observation period for all patients was set at 24 months, at intervals of 3, 6, 12, 18 and 24 months in the case of evaluating intraocular pressure and the need for anti-glaucoma medication, and 6, 12, 18 and 24 months in the case of evaluating visual acuity, stabilization of the visual field and changes of the optic nerve.

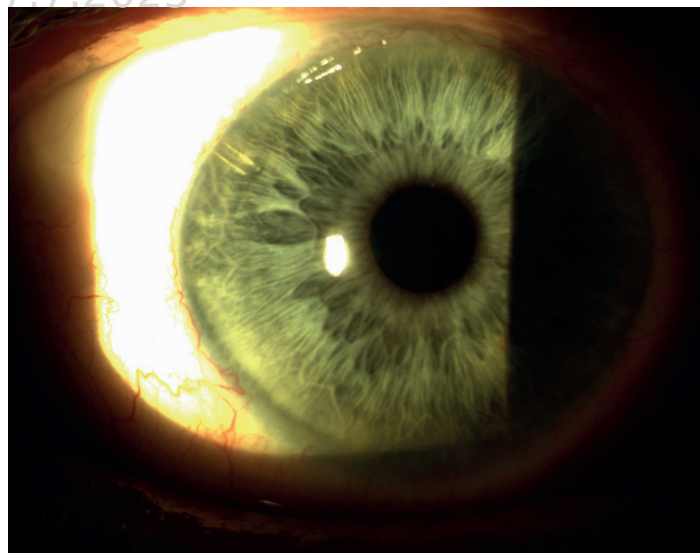


Figure 1. Patient with Preserflo implant at 10 o'clock

The average duration of glaucoma therapy before implantation of a PRESERFLO™ MicroShunt was 14.5 years. In all patients the average frequency of check-ups before the implantation of PRESERFLO™ MicroShunt was a minimum of once per 3 months, and in all cases progression was determined in the preoperative period on perimetry or on OCT. The operations were performed from August 2020 to February 2022 at the eye center VISUS, spol. s.r.o. in Náchod, Czech Republic. The indication for implantation was incipient to advanced primary open-angle glaucoma (POAG) which was poorly controlled with the maximum possible tolerated medication and a healthy, freely mobile conjunctiva in the place of implantation, most preferably in the superior temporal quadrant. Before surgery all 19 eyes had anti-glaucoma medication applied (Table 1). Within the cohort 8 eyes had undergone previous anti-glaucoma surgery (Table 2). The time period between primary anti-glaucoma surgery and implantation of a PRESERFLO™ MicroShunt ranged from 3 months to 7 years, on average 30.87 months \pm 28.52. Implantation was performed in 17 arterphakic eyes with an implanted posterior chamber intraocular lens, and 2 phakic eyes. The time period between cataract surgery and the implantation of PRESERFLO™ MicroShunt ranged from 1 month to 11 years, on average 36.05 months \pm 39.34.

Surgical procedure

Preoperative preparation

One month before surgery we discontinued prostaglandins and brimonidine, and started applying hydrocortisone (Softacort, Laboratoires THEA, Clermont-Ferrand, France) drops 5x per day in order to reduce inflammatory reaction of the conjunctiva and to improve postoperative filtration beneath the conjunctiva. One day before surgery we discontinued the hydrocortisone drops and instead applied tobramycin with dexamethasone (Tobradex, Novartis, Basel, Switzerland) drops 5x per day in the operated eye.

Table 1. Antiglaucoma medication and its frequency before surgery

Frequency of antiglaucoma medication	Number of eyes
Monotherapy	2
Double Combination	2
Triple Combination	10
Quads	5

Table 2. Types of antiglaucoma surgery before Preserflo MicroShunt implantation

Antiglaucoma surgery	Number of eyes
Trabeculectomy	1
EX-PRESS implant	1
Laser iridectomy	1
Selective laser trabeculoplasty	5

Surgical procedure

We implanted the PRESERFLO™ MicroShunt by an ab externo procedure parallel to the iris. The operations were performed under subconjunctival anesthesia using articaine hydrochloride/epinephrine 1ml (Supracain, Zentiva, Prague, Czech Republic). The surgical procedure incorporated opening of the conjunctiva on the limbus in the temporal or nasal superior quadrant, and relaxation of the Tenon's fascia by means of a blunt preparation beyond the equator. Mitomycin C was then applied into this prepared space with the aid of a damper in a concentration of 0.4 mg/ml for a period of 2–3 minutes for the purpose of reducing the risk of failure of filtration. After copious rinsing with physiological solution, we used a marker to indicate the place of incision on the sclera, which is 3 mm from the corneal limbus. With the aid of a prepared knife with a diameter of 1 mm we created a shallow scleral tunnel of a length of 2 mm in a distally indicated position. We subsequently opened the peak of the scleral pocket with a 25G needle in order to create a transscleral tunnel into the anterior chamber for placing of the implant. We then implanted the PRESERFLO™ MicroShunt by this channel, in order to insert its flaps into the scleral pocket, its proximal end in this case is in the anterior chamber of the eye. We inserted the distal end of the PRESERFLO™ MicroShunt beneath the Tenon's fascia so that it was lying evenly on the sclera. Before closing the Tenon's fascia it is important to evaluate the flow through the MicroShunt. Successful through-flow is visually determined when infiltration of the chamber fluid can be seen from the distal end of the implant. We reinforced the Tenon's fascia and the conjunctiva with Vicryl 8-0 sutures. In all cases we performed the operations separately without combination with cataract surgery. The operations were performed by 3 surgeons: 7 eyes (MV), 6 eyes (PR) and 6 eyes (JK).

Postoperative care

In the postoperative period we applied tobramycin with dexamethasone (Tobradex, Novartis, Basel, Switzer-

land) drops locally 5x per day for one week, after which we applied hydrocortisone (Softacort, Laboratoires THEA, Clermont-Ferrand, France) drops 6x per day for 5–6 weeks with subsequent reduction of the dose to 5x per day over a period of 2 months and subsequently according to vascularization of the filtration cushion, with reduction to 4x per day over a period of 6 months from the operation or if applicable longer. All pharmaceuticals reducing intraocular pressure in the operated eye were discontinued with the PRESERFLO™ MicroShunt implant operation.

During the first months, the patients were examined every week, after which they were examined also outside the regular observation times in the case of patient complaints, in order to ensure timely diagnosis of potential early postoperative complications.

We evaluated the degree of reduction of intraocular pressure in millimeters of the mercury column measured by Goldmann applanation tonometry (Haag-Streit, Bern, Switzerland) on a slit lamp CSO SL-980 (C.S.O, Scandicci-Firenze, Italy), reduction of local anti-glaucoma medication and its spectrum, best corrected visual acuity on Snellen charts (NIDEK SC-1600, Gamagori, Japan), the degree of stabilization on the perimeter according to the mean deviation indicator (MD, mean deviation of sensitivity of all points in comparison with the norm for the relevant age) on computer perimetry (TT 30-2) HFA 740i (Carl Zeiss Meditec AG, Oberkochen, Germany), the degree of stability of thickness of the retinal nerve fiber layer (RNFL) on OCT and excavation of the optic nerve papillae on OCT (Carl Zeiss Meditec AG, Oberkochen, Germany), and the incidence of adverse effects of surgery. At the individual follow-up examinations, changes on the anterior segment of the operated eye were also evaluated.

The success of the operation was determined to be complete if intraocular pressure was within the range of 6–21 mmHg and reduction of IOP was by $\geq 20\%$ from the baseline value, with no reoperation for glaucoma (defined as requiring a procedure in the operating theatre), no chronic hypotonia defined as $IOP \leq 6$ mmHg in 2 consecutive follow-up visits at an interval of 3 months, and no use of anti-glaucoma therapy. Qualified success was defined similarly to "complete success", but with the additional use of complementary glaucoma therapy. In patients who have not attained a reduction of intraocular pressure by $\geq 20\%$ even despite the necessary application of anti-glaucoma medication or despite necessary reoperation, the operation was considered unsuccessful.

The aim of evaluating safety was to assess the incidence of all adverse effects in connection with the implant during the operation or postoperative follow-up observation period.

Statistics

Descriptive statistics were used for interpretation of the data. Nonparametric tests were used for pair and inter-group comparison. The dependencies between the parameters were evaluated with the aid of a Friedman test and Bonferroni correction. Shapiro-Wilk and

Kolmogorov-Smirnov tests were used for testing normality. The analysis was conducted within the program environment IBM SPSS Statistics 29.0.1.

RESULTS

The cohort comprised 19 eyes of 12 patients, of whom 5 were women and 7 men with an average age of 72 years (61–84 years). The follow-up observation period of 24 months was completed in the case of all eyes in the cohort. Preoperative average IOP was 19.05 ± 0.58 mmHg, with minimum of 11 mmHg and maximum of 28 mmHg, in which 8 eyes manifested preoperative IOP of ≥ 21 mmHg. All the eyes had preoperatively applied maximum possible tolerated anti-glaucoma medication. The average number of preoperative anti-glaucoma medications was 2.95 per patient.

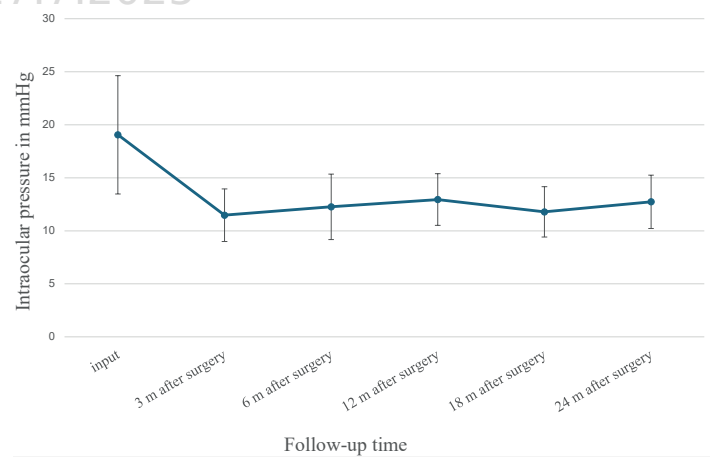
Average IOP at 3 months postoperatively was 11.47 ± 2.48 mmHg, reduced by 40% in comparison with the average preoperative IOP value, at 6 months postoperatively 12.26 ± 2.48 mmHg, reduced by 35.7%, at 12 months postoperatively 14.0 ± 2.43 mmHg, reduced by 26.5 %, at 18 months postoperatively 11.78 ± 2.37 mmHg, reduced by 38.2 % and at 24 months postoperatively 12.73 ± 2.51 mmHg, reduced by 33.2% against the average baseline value (Graph 1). The postoperative reduction of the average IOP value was statistically significant throughout the entire follow-up observation period ($p < 0.001$).

The results of the paired test of comparison show that a statistically significant reduction of intraocular pressure was achieved 3 months after surgery, and this reduction remained statistically significant throughout the entire period of 24 months after surgery. The Friedman test did not demonstrate statistically significant differences in the measured value of IOP between the individual time periods from 3 months to the time of 24 months after surgery ($p = 0.686$). The results indicate that the initial improvement of intraocular pressure observed soon after the operation remained relatively stable, and that no significant changes occurred during the course of the following 24 months.

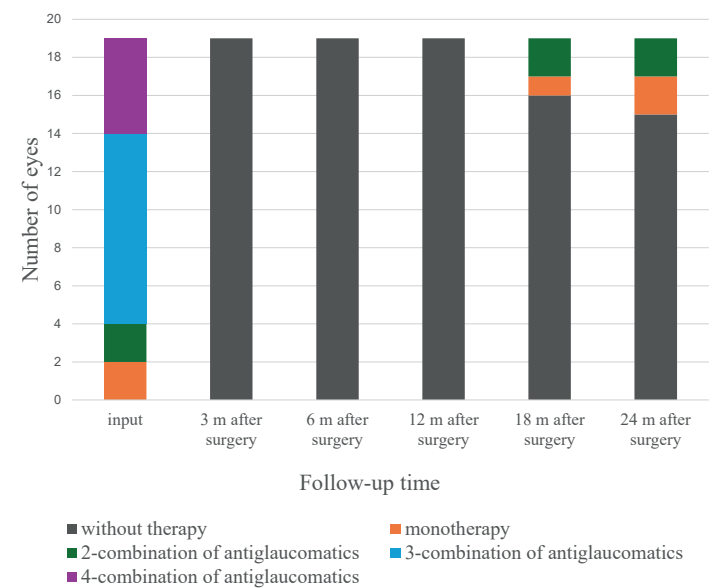
Upon determining the success of the operation from the perspective of the set criteria for resulting intraocular pressure at the end of the follow-up observation period (24 months after surgery), we found complete success in 13 eyes, which represents 68.5%, qualified success in 2 eyes, thus 10.5%, and lack of success in 4 eyes, thus 21%.

Upon an evaluation of the application of preoperative anti-glaucoma therapy, complete discontinuation was demonstrated in all eyes 3, 6 and 12 months after surgery, in 16 eyes 18 months after surgery and in 15 eyes 24 months after surgery. Monotherapy was applied in 1 eye (5.26 %) 18 months after surgery and in 2 eyes (10.52%) 24 months after surgery. A dual combination of anti-glaucoma drugs was indicated 18 months after surgery in 2 eyes (10.52%) and 24 months after surgery in 2 eyes (10.52 %) (Graph 2).

The percentual reduction of applied anti-glaucoma drugs at the end of the follow-up observation period (24 months after surgery) was 89.2 %.



Graph 1. Mean intraocular pressure (IOP) in mmHg during the follow-up period

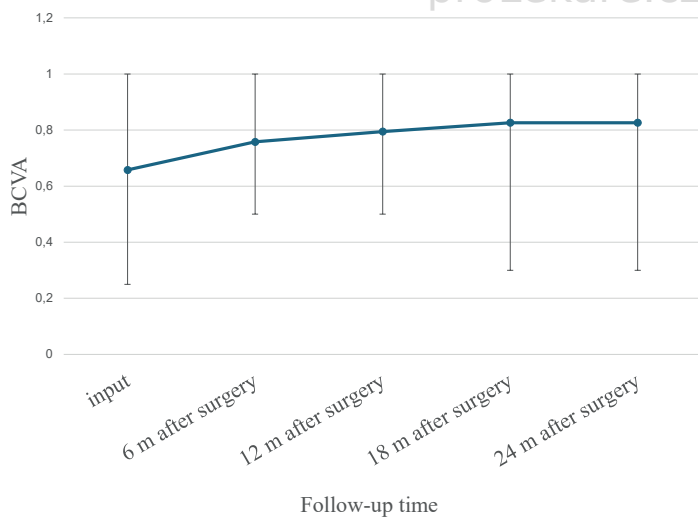


Graph 2. Antiglaucoma therapy before surgery versus after surgery

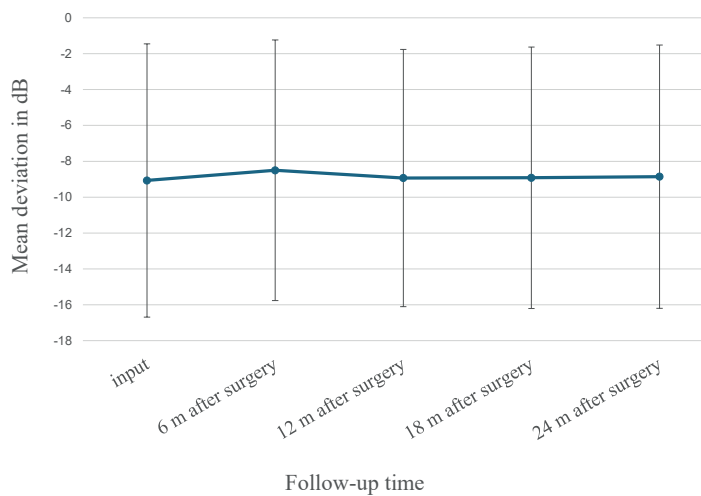
Average best corrective visual acuity preoperatively was 0.65 ± 4.65 on Snellen charts. Best corrected visual acuity 6 months after surgery was on average 0.75 ± 5.64 , 12 months after surgery 0.79 ± 6.19 , and 18 and 24 months after surgery on average 0.82 ± 7.07 on Snellen charts (Graph 3).

From the above results it ensues that average best corrected visual acuity had statistically significantly improved 6 months after surgery ($p < 0.05$), and subsequently remained constant between the individual measured time intervals up to the time of 24 months after surgery.

The visual field of the patients was evaluated using the mean deviation of sensitivity of all points in comparison with the norm for the relevant age (MD). The average MD value before surgery was -9.06 ± 7.61 dB, 6 months after surgery -8.49 ± 7.25 dB, 12 months after surgery -8.93 ± 7.16 dB, 18 months after surgery -8.91 ± 7.33 dB and 24 months after surgery -8.85 ± 7.33 dB ($p = 0.305$). Based on the results it is evident that no



Graph 3. Average best corrected visual acuity (BCVA) on Snellen charts versus follow-up time



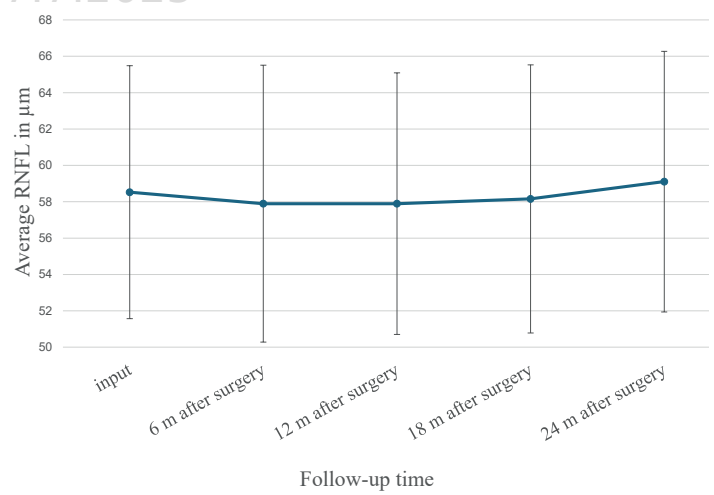
Graph 4. Evaluation of the field of view on the T 30-2 computer perimeter given by the mean deviation parameter in decibels (dB)

dramatic improvement took place, but that there was also no worsening of changes in the visual field.

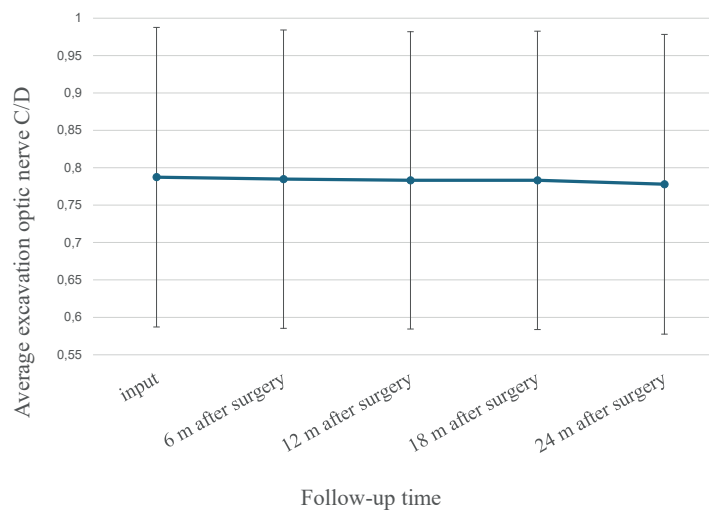
No pair comparison demonstrated a statistically significant difference (all the corrected p-values are 1.000), which means that no significant differences in the visual field were found between the individual points in time (Graph 4).

The average value of the RNFL on OCT preoperatively was $58.52 \pm 6.95 \mu\text{m}$, at 6 months after surgery $57.89 \pm 7.61 \mu\text{m}$, 12 months after surgery $57.89 \pm 7.61 \mu\text{m}$, 18 months after surgery $58.15 \pm 7.37 \mu\text{m}$ and 24 months after surgery $59.10 \pm 7.16 \mu\text{m}$ ($p = 0.05$). It ensues from the results of the Friedman test that no significant changes in the values of the retinal nerve fiber layers (RNFL) exist over time within the observed period (Graph 5).

Average excavation of the optic nerve papillae on OCT before surgery was 0.78 ± 0.04 , 6 months after surgery 0.78 ± 0.03 , 12 months after surgery 0.78 ± 0.03 , 18 months after surgery 0.78 ± 0.03 and 24 months after surgery 0.78 ± 0.04 ($p = 0.05$). It ensues from the results of the Friedman test that no statistically significant changes of average excavation of the optic nerve pa-



Graph 5. Average nerve fiber layer measured on OCT versus follow-up time



Graph 6. Mean optic nerve target extinction measured on OCT versus follow-up time

pillae occurred within the observed period (Graph 6).

No serious complications occurred perioperatively. During the early postoperative period we found a loose conjunctival suture in 3 eyes, which was followed by resuturing in 1 eye due to infiltration of intraocular fluid from the wound. In the late postoperative period we recorded complications in 1 eye. At 18 months after surgery the mouth of the implant obturated through the vitreous fiber by the loosened lens apparatus. It was necessary to explant the original implant, and to insert a second implant into the superior nasal quadrant. In this case we recorded a deterioration of best corrected visual acuity by 3 rows in Snellen charts due to progression of glaucoma neuropathy. It was not necessary to perform needling of the filtration cushion in any of the eyes.

DISCUSSION

Our retrospective study of 19 eyes evaluated the surgical success of the PRESERFLO™ MicroShunt implant in combination with mitomycin C 0.4 mg/ml for 2–3 minutes.

The result in our 2-year study 24 months after surgery points to a long-term reduction of IOP by as much as 12.73 ± 2.51 mmHg, thus by 33.2% in comparison with the average baseline value. The percentual reduction of applied anti-glaucoma drugs at the end of the follow-up observation period was 89.2%. One of the target parameters of effectiveness was the number of eyes which achieved complete and qualified success. Two years after surgery, complete success was recorded in 68.5% of eyes and qualified success in 10.5% of eyes. Our results correlate with the results recorded by Batlle et al. [14], in which IOP was reduced to 10.7 ± 3.5 mmHg after 3 years, thus a reduction by 53% in comparison with the baseline value. The reduction of the average number of anti-glaucoma medications was 64%. During the operation MMC 0.4 mg/ml was used for 3 minutes. In an extension of the follow-up observation period to 5 years the authors confirmed maintained reduction of IOP and a reduction of the average number of anti-glaucoma medications [1]. Similar results were also demonstrated by Schleres et al. in their cohort of patients over a follow-up observation period of two years [8]. In their cohort IOP was reduced after 24 months to 12.7 ± 3.5 mmHg, thus a reduction of 39% in comparison with the baseline value. The reduction of the average number of anti-glaucoma medications was 64%. During the operation MMC 0.2 mg/ml was used for 3 minutes. Similar results are presented within a shorter observation period of 11 months also by Ibarz-Barberá et al. [15], with the use of MMC 0.2 mg/ml for 2 minutes. Beckers et al. [5] in their study documented a reduction of IOP after 2 years to 14.1 ± 3.2 mmHg, thus by 20% in comparison with the baseline value. The largest difference in reduction of IOP between the groups (with the use of 0.2 mg/ml MMC and 0.4 mg/ml MMC) was recorded at 6 months, but the differences were not significant at further follow-up examinations within the 2-year interval after surgery. The reduction of the average number of anti-glaucoma medications was 51.9% in the group with the use of 0.2 mg/ml MMC and 90.3% in the group with the use of 0.4 mg/ml MMC. During the operation MMC 0.2 mg/ml was used for 2–3 minutes and 0.4 mg/ml for 2–3 minutes. The differences in adverse effects in comparison of the use of MMC in different concentrations were observed in a study conducted by Beckers et al. [5]. The authors determined a higher percentage of incidence of transitory hypotonia upon the use of MMC in a concentration of 0.4 mg/ml. In our study with the used concentration of MMC 0.4 mg/ml we did not record any adverse effect.

The influence of the dose and time of exposure to MMC during the implantation of a PRESERFLO™ MicroShunt shall require further study.

The use of MMC is considered an important element in the success of the surgical operation [1]. It has been demonstrated that human serum factors inhibit the antifibrotic activity of MMC in the fibroblastic cells of the Tenon's fascia in vitro [14]. There is currently no clear consensus regarding the most effective doses and the application of time of MMC [15]. The exposure time is typically 2–3 minutes, and it can be calibrated according to the number and severity of the risk factors for failure of the procedure. Ab-

sorption materials are used for direct application of MMC to the scleral bed after dissection of the Tenon's capsule, as is also traditional trabeculectomy surgery [1,16].

In a one-year study Ibarz-Barberá et al. [13] analyzed postoperative changes of endothelial cells in patients following the implantation of a PRESERFLO™ MicroShunt and the relationship that these changes could have with the position of the tube in the anterior chamber. It was determined that implantation of a PRESERFLO™ MicroShunt is associated with a loss of endothelial cells in the immediate postoperative period, which continues more slowly also over the course of at least one year. In our retrospective study we did not evaluate the loss of endothelial cells.

The implantation of a PRESERFLO™ MicroShunt stabilized the parameters used for diagnosis and monitoring of glaucoma (visual field, optic coherence tomography of the optic nerve papilla and retinal nerve fiber layer). In a study conducted by Sofie Fili et al. [17], the aforementioned parameters were also stabilized as in our own study over a 12-month observation period.

No serious complications occurred perioperatively in our study. In the early postoperative period we recorded a loose conjunctival suture in 3 eyes, which was followed by resuturing in 1 eye due to infiltration of intraocular fluid from the wound. In the late postoperative period we recorded complications in 1 eye. At 18 months after surgery the mouth of the implant obturated through the vitreous fiber by the loosened lens apparatus. It was necessary to explant the original implant, and to insert a second implant following prior anterior vitrectomy. It was not necessary to perform needling of the filtration cushion in any of the eyes. During the course of our study we did not record late hypotonia or loss of sight as a consequence of hypotonic maculopathy. No complications occurred such as hyphema, shallow anterior chamber, choroidal ablation, blebitis, endophthalmitis or migration of the implant. We also did not record any case of loss of sight or malignant glaucoma. The incidence of perioperative and postoperative complications differs according to different authors. In a study conducted by Ibarz Barberá et al. [4], no cases with complications were reported. In a study by Fea et al. [18], all the complications were mild and successfully resolved. Needling was performed on 19 eyes, and surgical revision on 14 eyes. In a study by Beckers et al. [5], non-serious adverse effects were recorded in 56.4% of cases (increased IOP, hypotonia, keratitis, flat AC, hyphema and diplopia), whereas severe adverse effects were recorded in 6.9% (keratitis, conjunctival dehiscence, and corneal ulcer). In a study conducted by Batlle et al. [1], a total of 21 non-serious complications were reported during the first 3 years after surgery. A further 10 non-serious adverse cases were recorded up to the 5th year after surgery, and 4 serious adverse cases (turbidity of posterior capsule, posterior synechiae and pupillary affection). No disorders of the implant, chronic hypotonia or endophthalmitis were reported in the 5th year. Reoperation was performed on 2 patients (8.7%) due to failure of the filtration cushion. A second MicroShunt was implanted in one of these patients, whereas in the other patient the MicroShunt was

replaced by an XEN 45 gel stent. Needling of the filtration cushions was required in 2 patients (8.7%).

In recent years the options for surgical solution of glaucoma have been expanded by the introduction of MIGS. The mechanism of effect differs in MIGS. The XEN 45 gel stent and PRESERFLO™ MicroShunt drain the fluid into the subconjunctival space, similarly as in the case of trabeculectomy [8].

Although it still ranks as one of the most frequently performed anti-glaucoma operations due to its effectiveness in reducing IOP, trabeculectomy nevertheless entails the risks of adverse effects such as the requirement for other sight-threatening postoperative interventions and a long postoperative convalescence time [6,19].

In a study conducted by Baker et al. [20], which compares the effectiveness and safety of PRESERFLO™ MicroShunt with trabeculectomy, after 1 year the probability of success was lower in the group with PRESERFLO™ MicroShunt (53.9%) in comparison with the group with trabeculectomy (72.7%). In the PRESERFLO™ MicroShunt group, complete success (IOP < 21 mmHg) was recorded in 60.8% of patients, in comparison with 68% after trabeculectomy. With regard to safety, the percentage of postoperative interventions and the incidence of hypotonia reported in a randomized study of PRESERFLO™ MicroShunt versus trabeculectomy was higher in the group with trabeculectomy.

In a study by Gubser et al. [19] comparing PRESERFLO™ MicroShunt with trabeculectomy, it was demonstrated that the decrease in intraocular pressure and the reduction of the number of anti-glaucoma medications during a two-year observation period in POAG is comparable in both groups. The complications during the postoperative period between both groups were also comparable, without statistical significance.

In a study by Scheres et al. [8] which directly compared Preserflo Microshunt with an XEN 45 gel stent, the authors demonstrated that similar results were achieved in eyes with POAG, with a similarly high safety profile. A total of 73% of eyes with an XEN gel stent and 79% of implantations of Preserflo Microshunt demonstrated qualified success after 24 months of observation. The study demonstrated a safe and effective reduction of intraocular pressure and the need for anti-glaucoma medication, with a similar success rate after 2 years.

In the case of the early phase of the therapeutic process of primary open-angle glaucoma, based on our results it

is appropriate to prioritize PRESERFLO™ MicroShunt over other conventional surgical methods. The simple and relatively quick surgical method with a fast learning curve, with long-term reduction of intraocular pressure, as well as the significant reduction to discontinuation of anti-glaucoma medication and minimal perioperative complications, are key advantages of PRESERFLO™ MicroShunt.

A disadvantage of PRESERFLO™ MicroShunt is the risk of obturation of the drainage channel, which may require further surgical interventions. Another limiting factor is its high price. A very important factor is to adhere to the principle of the freely mobile, unimpaired conjunctiva in the place of implantation.

This is a progressive method in the surgical treatment of glaucoma, with a high safety profile and minimal anatomical invasiveness, which may improve patients' quality of life.

This retrospective study has a number of limitations. The evaluated cohort comprised a smaller number of patients with a medium-length follow-up observation period. The operations were performed by three surgeons. Primary open-angle glaucoma was diagnosed in all the patients, and as a consequence our results may not be usable for different types of glaucoma. This study is not comparative, and as a result does not provide information about the success rate between PRESERFLO™ MicroShunt and other anti-glaucoma surgical techniques.

CONCLUSION

Severe and refractory glaucoma remains a difficult challenge for ophthalmologists due to poor adherence to pharmacological therapy and the extensive postoperative care required in connection with conventional surgical procedures. Trabeculectomy and large drainage shunts are often used in the treatment of uncontrollable medium-severe to severe glaucoma, but often require intensive postoperative care. The surgical procedure PRESERFLO™ MicroShunt may be indicated in the early phase of the therapeutic process before significant damage to the optic nerve has occurred. PRESERFLO™ MicroShunt can be used separately or in combination with phacoemulsification [11].

From our results it ensues that the glaucoma implant PRESERFLO™ MicroShunt is an effective surgical method with minimal postoperative complications, leading to a reduction of average IOP and to discontinuation or reduction of local anti-glaucoma medication for up to 2 years after surgery.

REFERENCES

1. Batlle JF, Corona A, Albuquerque R. Long-term Results of the PRESERFLO MicroShunt in Patients With Primary Open-angle Glaucoma From a Single-center Nonrandomized Study. *J Glaucoma*. 2021 Mar 1;30(3):281-286. doi: 10.1097/IJG.0000000000001734
2. Dervos T, Gugleta K, Scholl HPN, Gatziofufas Z, Enz TJ. Single versus Double PreserFlo MicroShunt Implantation in Glaucoma Patients: A Retrospective Cohort Study. *Ophthalmic Res*. 2023;66(1):1362-1375. doi: 10.1159/000535276
3. Gambini G, Carlà MM, Giannuzzi F, et al. PreserFlo® MicroShunt: An Overview of This Minimally Invasive Device for Open-Angle Glaucoma. *Vision (Basel)*. 2022 Feb 9;6(1):12. doi: 10.3390/vision6010012
4. Ibarz-Barberá M, Morales-Fernández L, Corroto-Cuadrado A, et al. Corneal Endothelial Cell Loss After PRESERFLO™ MicroShunt Implantation in the Anterior Chamber: Anterior Segment OCT Tube Location as a Risk Factor. *Ophthalmol Ther*. 2022 Feb;11(1):293-310. doi: 10.1007/s40123-021-00428-0
5. Beckers HJM, Aptel F, Webers CAB, et al. Safety and Effectiveness of the PRESERFLO® MicroShunt in Primary Open-Angle Glaucoma: Results from a 2 – Year Multicenter Study. *Ophthalmol Glaucoma*.

- 2022 Mar-Apr;5(2):195-209. doi: 10.1016/j.jogla.2021.07.008
6. Qin Q, Zhang C, Yu N, et al. Development and material characteristics of glaucoma surgical implants. *Adv Ophthalmol Pract Res*. 2023 Sep 23;3(4):171-179. doi: 10.1016/j.aopr.2023.09.001
7. Saeed E, Gołaszewska K, Dmuchowska DA, Zalewska R, Kono-
pińska J. The PreserFlo MicroShunt in the Context of Minimally
Invasive Glaucoma Surgery: A Narrative Review. *Int J Environ Res
Public Health*. 2023 Feb 7;20(4):2904. doi: 10.3390/ijerph20042904
8. Scheres LMJ, Kujovic-Aleksov S, Ramdas WD, et al. XEN® Gel Stent
compared to PRESERFLO™ MicroShunt implantation for primary
open-angle glaucoma: two-year results. *Acta Ophthalmol*. 2021
May;99(3): e433-e440. doi: 10.1111/aos.14602
9. Bhayani R, Martínez de la Casa JM, et al. Short-term safety and effi-
cacy of Preserflo™ Microshunt in glaucoma patients: a multicentre
retrospective cohort study. *Eye (Lond)*. 2023 Mar;37(4):644-649.
doi: 10.1038/s41433-022-01995-7
10. Bunod R, Robin M, Buffault J, Keilani C, Labbé A, Baudouin C. Pre-
serFlo MicroShunt® exposure: a case series. *BMC Ophthalmol*. 2021
Jul 10;21(1):273. doi: 10.1186/s12886-021-02032-z
11. Habbe KJ, Kohlhaas M, Fili S. PreserFlo™ MicroShunt Versus Ab Ex-
terno Canaloplasty in Patients With Moderate to Advanced Open-
Angle Glaucoma: 12 – Month Follow-Up of a Single-Center Retro-
spective Study. *Cureus*. 2023 Feb 19;15(2): e35185. doi: 10.7759/
cureus.35185
12. Storp JJ, Vietmeier FE, Merté RL, et al. Long-Term Outcomes of the
PRESERFLO MicroShunt Implant in a Heterogeneous Glaucoma Co-
hort. *J Clin Med*. 2023 Jul 4;12(13):4474. doi: 10.3390/jcm12134474
13. Tanner A, Haddad F, Fajardo-Sanchez J, et al. One-year surgical
outcomes of the PreserFlo MicroShunt in glaucoma: a multicen-
tre analysis. *Br J Ophthalmol*. 2023 Aug;107(8):1104-1111. doi:
10.1136/bjophthalmol-2021-320631
14. Batlle JF, Fantès F, Riss I, et al. Three-Year Follow-up of a Novel
Aqueous Humor MicroShunt. *J Glaucoma*. 2016 Feb;25(2): e58-65.
doi: 10.1097/IJG.0000000000000368. PMID: 26766400
15. Ibarz Barberá M, Martínez-Galdón F, Caballero-Magro E, Rodrí-
guez-Piñero M, Tañá-Rivero P. Efficacy and Safety of the Preserflo
Microshunt With Mitomycin C for the Treatment of Open Angle
Glaucoma. *J Glaucoma*. 2022 Jul 1;31(7):557-566. doi: 10.1097/
IJG.0000000000002052
16. Ahmed IK, Sadruddin O, Panarelli JF. Subconjunctival filtration in
evolution: current evidence on MicroShunt implantation for trea-
ting patients with glaucoma. *Eye Vis (Lond)*. 2023 Mar 2;10(1):10.
doi: 10.1186/s40662-022-00322-1
17. Fili S, Kontopoulou K, Vastardis I, Perdikakis G, Bechrakis N, Ko-
hlhaas M. PreserFlo™ MicroShunt Combined with Phacoemulsifi-
cation versus PreserFlo™ MicroShunt as a Standalone Procedure
in Patients with Medically Resistant Open-Angle Glaucoma. *J
Curr Ophthalmol*. 2022 Jul 26;34(2):180-186. doi: 10.4103/joco.
joco_298_21
18. Fea AM, Ghilardi A, Bovone D, Reibaldi M, Rossi A, Craven ER.
A New and Easier Approach to Preserflo MicroShunt Implantation.
Clin Ophthalmol. 2022 Apr 27; 16:1281-1288. doi: 10.2147/OPHT.
S307835
19. Gubser PA, Pfeiffer V, Hug S, et al. PRESERFLO MicroShunt implan-
tation versus trabeculectomy for primary open-angle glaucoma:
a two-year follow-up study. *Eye Vis (Lond)*. 2023 Dec 21;10(1):50.
doi: 10.1186/s40662-023-00369-8
20. Baker ND, Barnebey HS, Moster MR, et al. Ab-Externo Micro-
Shunt versus Trabeculectomy in Primary Open-Angle Glaucoma:
One-Year Results from a 2-Year Randomized, Multicenter Study.
Ophthalmology. 2021 Dec;128(12):1710-1721. doi: 10.1016/j.
ophtha.2021.05.023