

SPONTANEOUS REGRESSION OF A PRIMARY IRIS STROMAL CYST IN A PATIENT WITH KERATOCONUS. A CASE REPORT

Galvis V.^{1,2,3}, Shields CL.⁴, Tello A.^{1,2,3}, Niño CA.^{1,2,3}, Laiton AN.^{2,3}, García JD.^{1,5}, Chaparro TA.^{1,2}, Viteri EJ.^{2,3}

¹Centro Oftalmológico Virgilio Galvis, Floridablanca, Colombia

²Fundación Oftalmológica de Santander FOSCAL, Floridablanca, Colombia

³Universidad Autónoma de Bucaramanga UNAB, Bucaramanga, Colombia

⁴Ocular Oncology Service, Suite 1440, Wills Eye Hospital, 840 Walnut St, Philadelphia, PA 19107, USA

⁵Universidad de la Sabana, Chía, Colombia

The authors of the study declare that no conflict of interest exists in the compilation, theme and subsequent publication of this professional communication, and that it is not supported by any pharmaceutical company. The study has not been submitted to any other journal nor has it been printed elsewhere.

Received: 15 March 2021

Accepted: 5 June 2021



First author:
Virgilio Galvis, MD, PhD

Corresponding author:
Juan Daniel García, MD
Centro Oftalmológico Virgilio Galvis
FOSCAL Internacional, office 3011
Floridablanca
Email: juandanielgarciasanchez@gmail.com.

SUMMARY

Purpose: To report the rare case of a 29-year-old male with a history of keratoconus, who presented with a primary iris stromal cyst which eventually showed spontaneous regression.

Methods: Description of the clinical findings in the case of a 29-year-old male with a prior history of keratoconus, but no eye surgery or trauma, who consulted for an iris cyst in the left eye, diagnosed 9 months earlier.

Case report: Slit-lamp examination revealed mild dyscoria, and a large cyst in the inferior quadrant of the iris. Ultrasound biomicroscopy and anterior segment optical coherence tomography of the left eye confirmed the presence of a giant iris cyst with thin walls, in contact with the corneal endothelium. Corneal endothelial cell density in the inferior cornea (close to the cyst) was 1805 cells/mm² and 2066 cells/mm² in the central area. After considering the risk of anterior chamber epithelial downgrowth following any surgical procedure of the cyst, the patient received conservative management. In the following months, the patient presented with 3 episodes of anterior uveitis, managed with topical corticosteroids. Finally, at approx. 21 months after the initial diagnosis, the cyst presented spontaneous regression. Anterior segment optical coherence tomography confirmed the absence of fluid inside the cyst remnants and the final endothelial cell densities evidenced endothelial cell loss (inferior cornea 738 cells/mm² and central cornea 1605 cells/mm²).

Conclusion: Conservative management should be considered in patients with cysts that show slow progression and are distant from the visual axis, in order to minimise the risk of complications following any surgical procedure of the cyst. In addition, the present case is one of the few of primary stromal iris cysts with spontaneous regression reported in the literature.

Keywords: iris cysts, iris diseases, iris stromal cyst management, keratoconus

Čes. a slov. Oftal., 77, 2021, No.5, p. 257–260

INTRODUCTION

Primary iris cysts are infrequent, in comparison with secondary cysts [1]. Surgical resection as well as alternative treatments, including intracystic ethanol injection to induce sclerosis, [2] and surgical aspiration of the cyst content, have been described for patients with progressive cyst growth and involvement of the visual axis [1].

However, the feared risk of anterior chamber epithelial downgrowth after these procedures is a critical issue [3]. On the other hand, spontaneous regression of primary stromal iris cysts has been reported, although only in a few cases [4,5]. Therefore, conservative management, especially in patients with cysts that show slow progression and do not involve the visual axis, could be an option.

In addition, to our knowledge, the association of primary iris cyst and keratoconus has not been previously published. However, it is difficult to establish an exact causal relationship between these.

The current case report presents a young man with keratoconus and a primary iris stromal cyst, that eventually exhibited spontaneous regression.

CASE REPORT

A 29-year-old male with a history of keratoconus, and the usage of rigid contact lenses, reported that about 9 months before the initial examination at Centro Oftalmológico Virgilio Galvis, he was diagnosed with an iris cyst in his left eye which had not received any specific treatment.

On initial examination, corrected distance visual acuity of the right eye was 20/25 (with refraction +0.50-5.00 x 20°) and of the left eye 20/30 (with refraction +1.00-7.00 x 135°). A clear cornea, mild dyscoria, and a large cyst on the inferior quadrant of the iris (from the 5 to 7 o'clock position), rather translucent, partially divided into 2 cavities, with few accumulations of pigment on its smooth surface, were found in the left eye (Figure 1). Intraocular pressure was normal in both eyes (10 mmHg).

Corneal topography findings (Sirius, CSO, Florence, Italy) showed keratoconus in both eyes, more advanced in the left eye. Thinnest corneal thickness was 470 and

446 microns in the right and left eyes respectively. Ultrasound biomicroscopy (UBM) of the left eye was performed, which reported a giant iris cyst (vertical diameter 5.05 mm and horizontal diameter 2.88 mm) with thin, well defined walls. No disruption of the iris pigment epithelium was seen, which together with the ciliary body, the zonules and the crystalline lens equator, were displaced by the cyst towards a more posterior position (Figure 1).

Anterior segment optical coherence tomography (AS-OCT) of the left eye showed a large cyst composed of two communicated cavities, protruding from the anterior surface of the iris, and making contact with the corneal endothelium (vertical diameter 4.8 mm and horizontal diameter 2.9 mm) (Figure 1).

Specular microscopy (SP3000P, Topcon, Tokyo, Japan) showed corneal endothelial cell density in the left eye was 2066 cells/mm² in the central cornea and 1805 cells/mm² in the inferior cornea close to the cyst. The right eye showed 2030 cells/mm² in the central area.

After discussing the case locally and with Dr. Carol Shields from the Wills Eye Hospital in Philadelphia (USA), the patient underwent conservative management and close observation, considering the absence of symptoms and that the visual axis was spared. Some of us were tempted to perform surgical drainage of the cyst, and later after reviewing the literature, we also thought it could be a case for intracystic irrigation with absolute alcohol in order

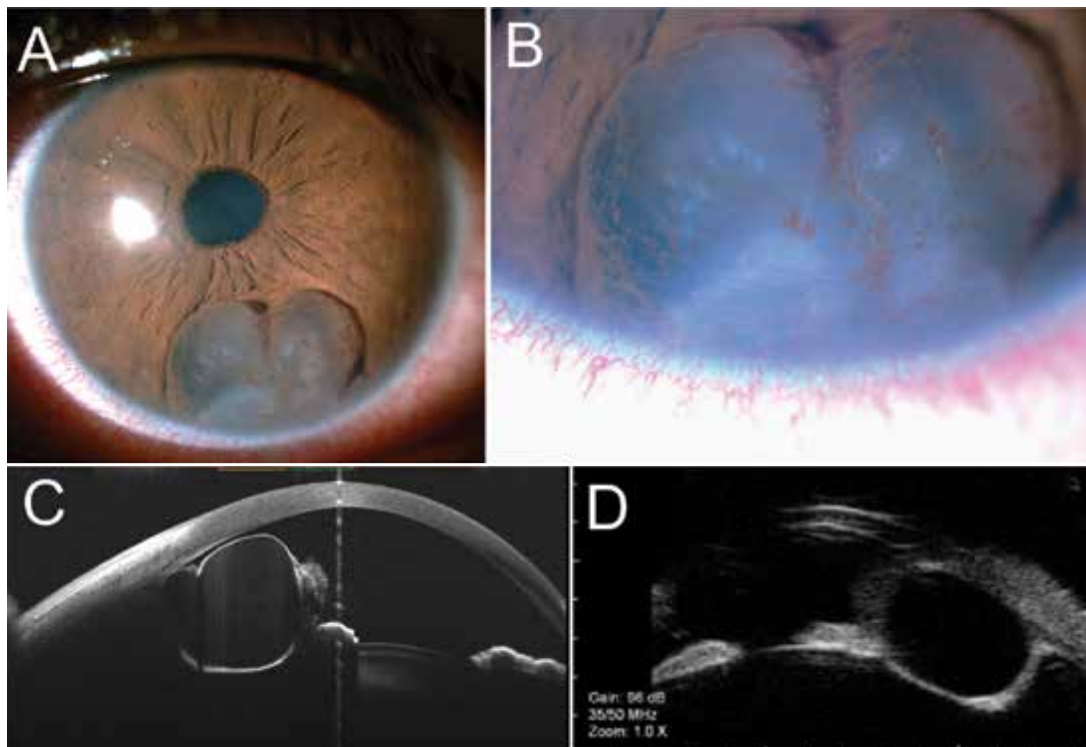


Figure 1. (A) Left eye: iris stromal cyst of approx. 4.0 x 5.5. mm in size, closing the inferior anterior chamber angle and touching the endothelium (August 2019). (B) Multiple faint, almost horizontal, fine pigmented lines are seen in the area where the cyst wall made contact with the endothelium (C) Anterior segment optical coherence tomography (MS-39, CSO, Florence, Italy) and (D) Ultrasound biomicroscopy of the lesion (HiScantouch, Optikon 2000, Rome, Italy)

to induce sclerosis [1-3]. However, following the advice of the international expert, and due to the risk of epithelial downgrowth in the anterior chamber as a complication of any surgical procedure, we decided to keep the patient under observation [4,5]. One month later, the patient consulted us, complaining of 3 days of pain in the left eye and perilimbal inferior redness. Eye redness and anterior chamber cellularity +++ were evidenced. Hence, anterior uveitis was diagnosed, probably secondary to microrupture of the cyst, and he received management with 1% topical prednisolone. Two weeks later, the inflammation finally resolved. During the next 9 months, the patient presented with two additional episodes of anterior uveitis, which were also managed with topical corticosteroids.

At the final check-up visit, 21 months after the initial diagnosis of the primary iris stromal cyst, the patient reported that he had not had symptoms for about 3 months. Slit-lamp biomicroscopy of the left eye revealed a clear cornea, mild dyscoria, and subtotal regression of the cyst, with its remnants being attached to the inferior anterior chamber angle and corneal endothelium, between the 5 and 6 o'clock position (Figure 2). The AS-OCT confirmed the absence of fluid inside the cyst remnants. The final endothelial cell densities in the left eye were 1605 and 738 cells/mm² in the central and inferior areas, respectively. The patient was recommended to attend periodic check-ups (every 6 months) to monitor endothelial cell density.

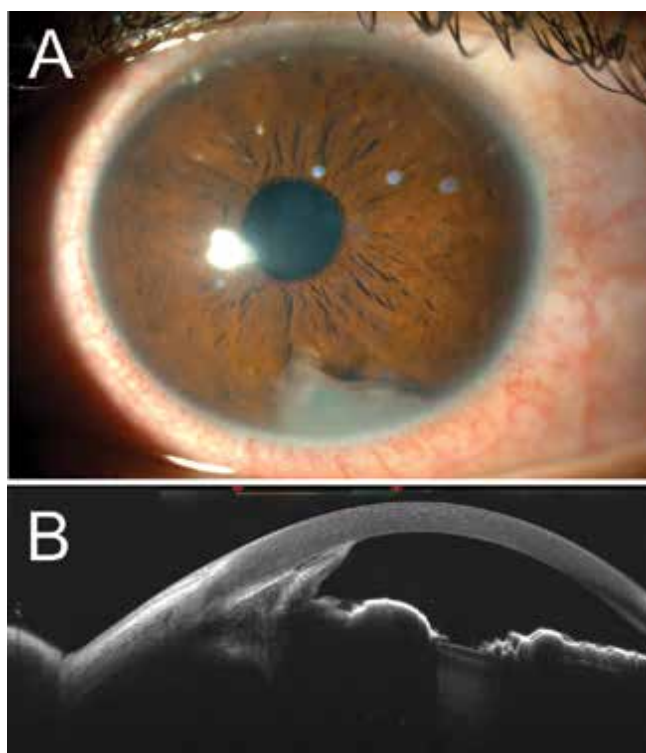


Figure 2. Eleven months later (July 2020) a subtotal regression of the cyst was observed both at the slit lamp (A) and with the anterior segment optical coherence tomography (B)

DISCUSSION

Several cases have been reported of primary iris stromal cysts with progressive growth, especially in children [1]. However, it seems that the majority of these primary lesions are stationary, and show very little growth over time, particularly in adults [1]. Therefore, conservative management should be considered.

To prevent complications such as pupillary obstruction, corneal decompensation, and secondary glaucoma, surgical options are reserved mainly for patients with progressive growth of the cyst that involves the visual axis. However, surgical management carries the risk of epithelial downgrowth in the anterior chamber that, although infrequent, is a serious complication. Lois et al. published a series of 17 patients with primary iris stromal cysts. Nine of them were children under 10 years of age, who showed a higher rate of cyst growth compared with the group of older patients. Only 2 of these children received conservative management, while the other 7 received some type of surgical treatment (excision of the cyst or aspiration of the cyst, with or without cryotherapy). Recurrences of the iris cyst was observed in 4 of those cases and further surgical treatment was needed to eradicate the cysts [1]. Although, in all 7 treated children, the cysts were controlled, complications during the follow-up included corneal oedema, peripheral band keratopathy and cataract. In the group of teenagers and adults with a mean age of 43 years, 7 out of the 8 patients were managed with observation and only 1 received treatment with laser photocoagulation, due to persistent photophobia. The patient who received photocoagulation had a recurrence of the cyst 4 weeks after the treatment and required further aspiration to collapse the cyst. Findings during the follow-up time of the patients who received expectant management, included a focal cataract at the site of cyst contact [1].

As mentioned, epithelial downgrowth is a severe and feared complication of the surgical procedures of iris cysts protruding into the anterior chamber [3]. In a series of 3 cases that developed epithelial downgrowth after the excision of an iris cyst, published by Orlin et al. (1991), the patients underwent multiple procedures, including corneal cryotherapy. Ultimately, two required cornea transplantations, but the third patient eventually developed an intractable glaucoma, and lost his vision [3].

Intracystic injection of absolute alcohol (ethanol 100%) has also been described in the management of iris cyst. Shields et al. published a series of 15 cases with iris stromal cysts, with recurrence after failed previous simple aspiration. In 10 cases, alcohol-induced sclerosis led to stabilisation or involution of the cyst; 2 patients presented with recurrence and required a second procedure; another 2 patients required a third procedure and a 3-year-old patient with cyst recurrence and severe photophobia required urgent resection. Complications following the alcohol-induced sclerosis were transient corneal oedema

and anterior segment inflammation, which resolved with topical corticosteroid therapy [2].

In the present case, the patient presented with a primary iris stromal cyst that initially did not cause symptoms or involve the visual axis. Therefore, the initial approach was conservative management and observation. During the first several months of follow-up, the cyst presented slow progression growth, but still spared the visual axis. In addition, the patient presented with 3 episodes of anterior uveitis that resolved with topical corticosteroids. At that time, we were tempted to change our approach to a more aggressive one, such as absolute ethanol-induced cyst sclerosis or excision of the cyst. However, considering the characteristics of the cyst and the possible complications secondary to invasive treatments, we decided to continue conservative management. Finally, 21 months after the initial diagnosis of the cyst, it presented a spontaneous regression.

Endothelial cell loss, as a consequence of direct contact with the cyst, was evidenced in the central cornea at the last follow-up visit (1605 cells/mm²), and predominantly in the inferior quadrant, near the area of contact of the cyst (738 cells/mm²). However, the cornea remained transparent and the patient free of symptoms. The patient was therefore instructed to consult every 6 months for follow-up with specular microscopy.

Corneal endothelial touch was also observed in 7 (41.2%) cases of primary stromal iris cysts reported by Lois et al., but only 1 of the 4 children and none of the 3 adults with this finding eventually had diffuse corneal oedema [1].

The present case is one of the few reported in the literature of primary stromal iris cysts, with spontaneous regression [4,5]. In addition, to our knowledge, the association of primary iris cyst and keratoconus, as in the case presented herein, has not been previously published. However, it is very difficult to establish the exact connection between the iris cyst and keratoconus, and it could simply correspond to a coincidence in this patient.

CONCLUSION

Most primary iris stromal cysts are stationary, and show very little growth over time, particularly in adults. Therefore, conservative management, especially in patients with cysts that show slow progression and are distant from the visual axis, should be considered. Furthermore, the possibility of spontaneous total or sub-total regression, although rare, may occur as in the present case [4,5].

LITERATURE

1. Lois N, Shields CL, Shields JA, Mercado G, De Potter P. Primary iris stromal cysts. A report of 17 cases. *Ophthalmology*. 1998 Jul;105(7): p. 1317-1322.
2. Shields CL, Arepalli S, Lally EB, Lally SE, Shields JA. Iris stromal cyst management with absolute alcohol-induced sclerosis in 16 patients. *JAMA Ophthalmol*. 2014 Apr;132(6): p. 703-708.
3. Orlin SE, Raber IM, Laibson PR, Shields CL, Brucker AJ. Epithelial downgrowth following the removal of iris inclusion cysts. *Ophthalmic Surg*. 1991 Jun;22(6): p. 330-335.
4. Winthrop SR, Smith RE. Spontaneous regression of an anterior chamber cyst: a case report. *Ann Ophthalmol*. 1981 Apr;13(4): p. 431-432.
5. Brent GJ, Meisler DM, Krishna R, Baerveldt G. Spontaneous collapse of primary acquired iris stromal cysts. *Am J Ophthalmol*. 1996 Dec;122(6): p. 886-887.