

# SCOTOMAS IN THE VISUAL FIELD AS THE FIRST SIGN OF INTRACRANIAL EXPANSION. CASE REPORT

Horkovičová K.<sup>1</sup>, Krásnik V.<sup>1</sup>, Liška M.<sup>2</sup>

<sup>1</sup>Department of Ophthalmology, Faculty of Medicine, Comenius University and University Hospital Bratislava, Slovakia


<sup>2</sup>Department of Neurosurgery, University Hospital Bratislava, Slovakia

*The authors of the study declare that no conflict of interests exists in the compilation, theme and subsequent publication of this professional article, and that it is not supported by any pharmaceuticals company. The article has not been submitted to any other journal or printed elsewhere, with the exception of congress abstracts and recommended procedures.*

Received: 24 August 2020

Accepted: 2 February 2021

Available on-line: 15 June 2021



MUDr. Kristína Horkovičová,  
Ph.D., MPH  
Klinika oftalmológie, Lekárska  
fakulta Univerzity Komenského  
a Univerzitná nemocnica Nemoc-  
nica Ružinov  
Bratislava  
E-mail: k.horkovicova@gmail.com

## SUMMARY

The most common cause of visual field loss in ophthalmology is glaucoma. Other causes of visual field damage include local damage to the eye itself in intrabulbar or retrobulbar neuritis or injuries. However, they can also be caused by general diseases, e.g. in endocrine orbitopathy, toxic and nutritional neuropathy, or in diseases that are localized intracranially. Each of these findings in itself suggests the nature of the lesion, its intracranial location, lateral occurrence, as well as in which part of the visual pathway the lesion is located. The use of perimeter has therefore become the primary examination method, which is available, is not demanding and will quickly allow a diagnosis to be made. When found on a perimetric examination, it is necessary to indicate targeted imaging examinations, such as computed tomography or magnetic resonance imaging. The article describes a patient who was primarily examined at the Department of Ophthalmology, Faculty of Medicine, Comenius University and the University hospital of Bratislava. The patient reported visual field outages, and after subsequent computed tomography, she was interdisciplinary managed and surgery was done on at the Neurosurgical Department. After the operation, there was a significant improvement without a pathological finding on the perimeter.

**Key words:** visual field loss, homonymous hemianopsia, perimeter, visual field, atypical meningioma

Čes. a slov. Oftal., 77, 2021, No.3, p. 154–157

## INTRODUCTION

When focusing on a specific point in space, it is possible also to perceive the wider space around this point, which is defined as the visual field. The visual field represents a function of the retina and is the sum of points which are perceived by a single eye without it moving. The range is defined by the shape of the face, forehead and nose. A physiological visual field for white colour has the following range: temporally 90°, nasally 60°, upwards approximately 60° and downwards 70°. In the past examination of the visual field is the only possibility for diagnosis of intracranial expansion [1–3].

Evaluation of the visual field is important upon assessing lesions which relate to the visual pathway. The most frequently used method is perimetry. In the case of the presence of a defect of the visual field on perimetry, with exclusion of an ophthalmological cause, this finding attests to a lesion located in the visual pathway. According to the scotoma on perimetry it is possible to

determine whether the lesion is located in the retrobulbar space, in the chiasm, in front of or behind the chiasm, in front of or beyond the corpus geniculata laterale or in the occipital lobe. Each lesion causes a blind spot which is typical of the given localisation [4,5].

## CASE REPORT

A 64-year-old patient examined at the outpatient section of the Department of Ophthalmology, Comenius University and the University Hospital in Bratislava in April 2020 stated deteriorated vision in her right eye persisting for approximately two weeks, with a blind spot in the visual field causing a loss of temporal vision, with the result that she collided with objects. She also stated a problem with spatial orientation and a feeling of inability to express herself verbally, and that she was unable to complete commenced manual work. Central visual acuity in the patient's right eye was 20/60, uncorrected, in the left eye 20/20, intraocular pressure in both eyes was

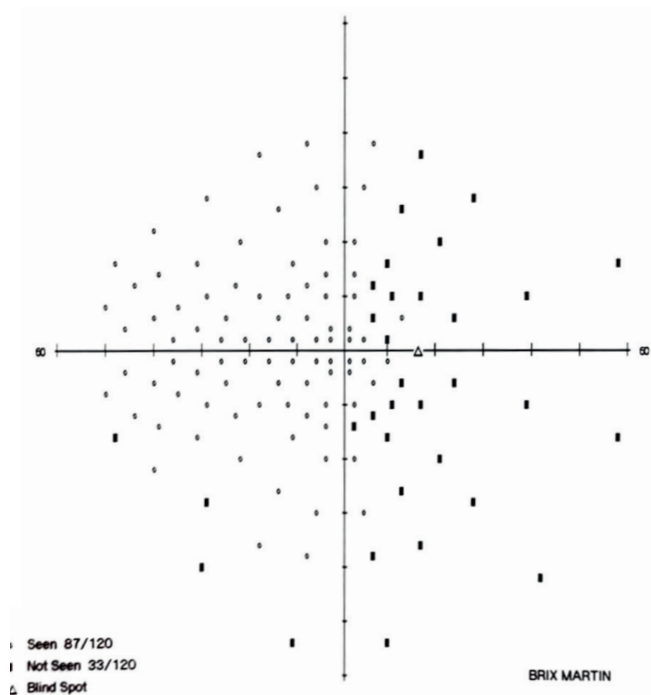
18 Torr. The local finding in both eyes was commensurate to age. A perimetric examination was conducted on the patient, with a finding of homonymous hemianopsia (Fig. 1 and 2). The patient was sent for examination by computer tomography, without the application of a contrast substance due to iodine allergy. The conclusion of the examination demonstrated a tumorous expansion in the parieto-occipital region on the left, with a shift of the midline structures and pronounced perifocal edema. There followed a neurological examination in which the patient was oriented auto and allopsychically, without meningeal symptomatology, speech without pathological finding, upon examination of gait a slight inclination towards the right. The patient was admitted for additional diagnosis at the Department of Neurology of the Slovak Medical University in Bratislava. Upon admittance magnetic resonance imaging was performed, with the conclusion of a tumorous deposit in parieto-occipital left of the parafalcine, with pronounced damage to the brain as a consequence of the size of the tumour, the character of the meningioma with suspected presence of a high-grade component (Fig. 3). The Department of Neurosurgery was consulted, and the patient was subsequently transferred there. On the 11<sup>th</sup> day after determination of the diagnosis, the patient underwent microsurgical neuronavigated resection via the biparieto-occipital craniotomy, perioperatively measured intracranial pressure was within a physiological range.

The tumorous mass was sent for a histological examination, the result of which was verified as an atypical meningioma, WHO gr. II. After surgery, follow-up magnetic resonance imaging was performed (Fig. 4). Two months after the operation the patient underwent a follow-up

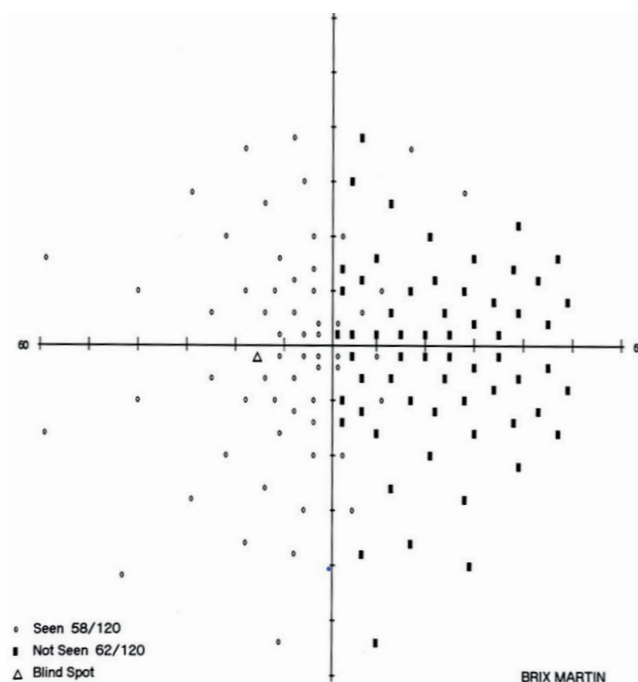
examination by perimetry, which was without scotomas bilaterally in the visual field (Fig. 5 and 6). The patient continues to be observed in outpatient care by an ophthalmologist, neurologist and neurosurgeon.

## DISCUSSION

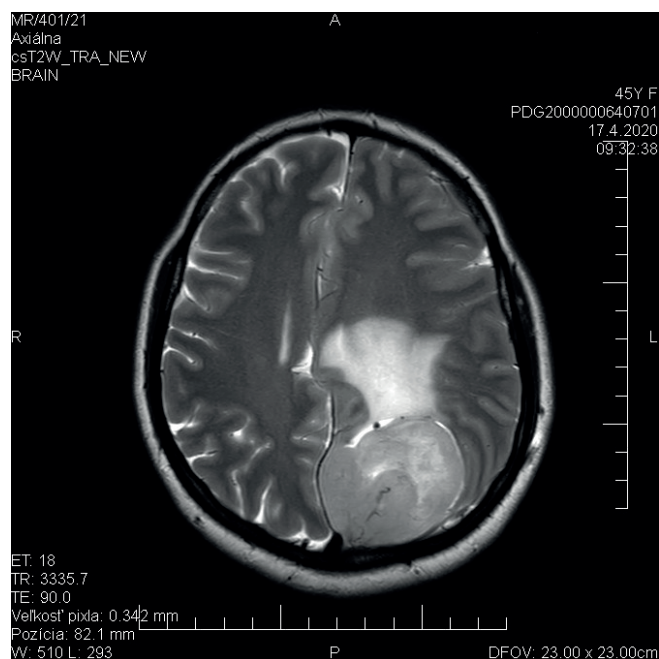
Disorders of the visual field adversely affect activities in everyday life, such as personal hygiene, reading and operating a motor vehicle, and should be taken into ac-



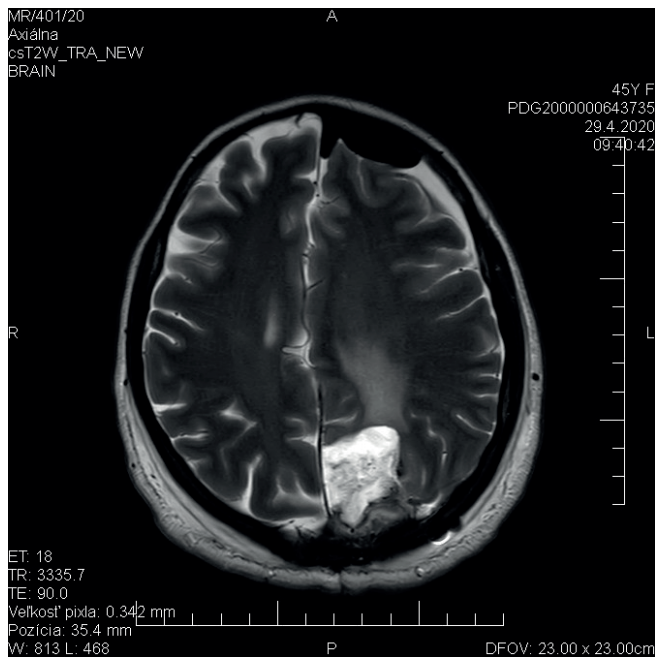
**Fig. 1.** Changes in visual field of patient's right eye before surgery



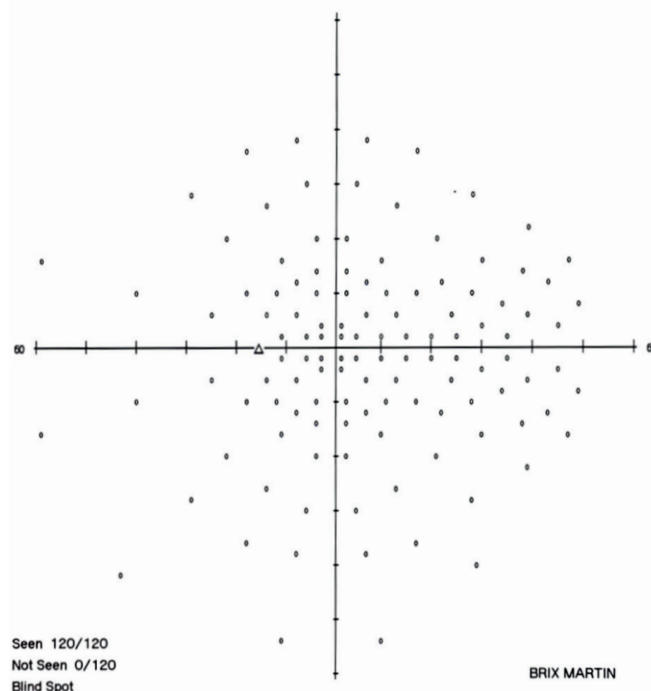
**Fig. 2.** Changes in visual field of patient's left eye before surgery



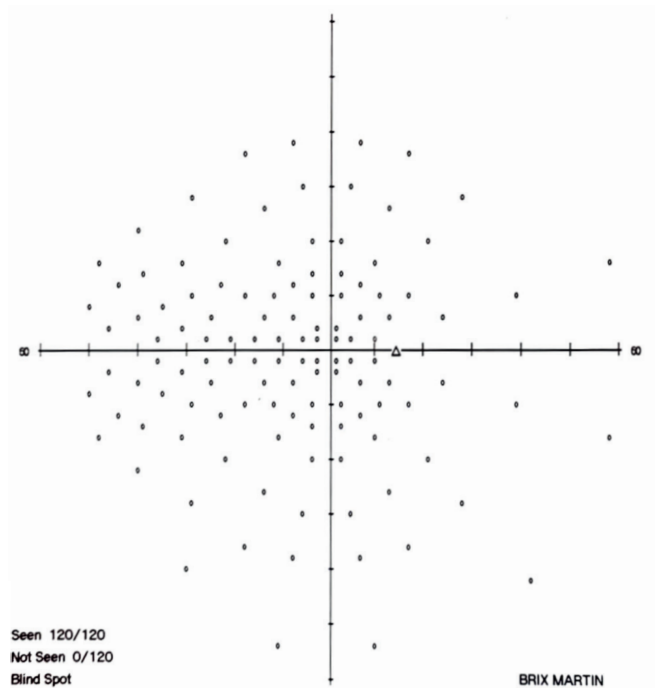
**Fig. 3.** Magnetic resonance imaging T2 weighing patient before surgery



**Fig. 4.** Magnetic resonance imaging T2 weighing patient after surgery



**Fig. 6.** Changes in visual field of patient's left eye after surgery



**Fig. 5.** Changes in visual field of patient's right eye after surgery

count when planning rehabilitation strategies. Testing of the visual field should be performed on all patients with lesions of the visual pathway.

Deficits of the visual field ensuing from neuro-ophthalmological conditions can adversely affect quality of life and activities in everyday life. Homonymous hemianopsia impairs the performance of everyday activities for patients, such as personal hygiene, food preparation, driving, shopping and using a telephone. Patients with homonymous hemianopsia describe problems reading,

which can also be classified as hemianopic dyslexia [6–9]. In differential diagnostics, it is necessary to consider also optic disc drusens, which may cause scotomas in the visual field [10].

Meningeomas can also be from the optic nerve sheath and constitute approximately 2% of all orbital tumours and 1–2% of all meningiomas, although in the orbit it is more common to find secondary meningiomas growing into the orbit from the surrounding area [11].

Homonymous hemianopsia need not be caused only by a tumorous lesion in the brain. Another cause may be posterior cortical atrophy, which mostly has its origin in the parieto-occipital cortex. The incidence of a homonymous defect of the visual field in posterior cortical atrophy is relatively frequent, and in the literature ranges markedly from 47.5% to 78%. Homonymous hemianopic disorders of the visual field in patients with posterior cortical atrophy usually appear together with disorders of visual functions with associated anomalous visual perceptions such as imperception of an image, hallucinations, simultanagnosia or achromatopsia.

Visual symptoms may be the first and dominant clinical manifestation of posterior cortical atrophy, and ophthalmologists are often the first to assess these patients. Within the framework of the differential diagnostic process in patients with visual symptoms, every ophthalmologist should keep in mind the possibility of neurodegenerative disease [12,13].

Zhang in his study confirms that stroke is the most common cause of homonymous hemianopsia. The large delay between the occurrence of a stroke and the identification of homonymous hemianopsia indicates that in patients with a stroke, hemianopsia is frequently overlooked [14].

Kamal-Salah describes a case in which a patient had a syndrome of mitochondrial myopathy, encephalopathy, lactic acidosis and episodes similar to stroke, which is referred to as MELAS syndrome. It is a hereditary disorder caused by mitochondrial DNA, by a point mutation influencing RNA, with ophthalmological manifestations such as external ophthalmoplegia, ptosis, retinitis pigmentosa, dystrophy, myopia, cataracts, atrophy of the optic nerve and homonymous hemianopsia [15–17].

Homonymous hemianopsia may be caused by a tumour in the region of the optic tract, in the region of the corpus geniculatum laterale, the optic radiation and the occipital cortex. Tumours are responsible for approximately two thirds of lesions in the region of the temporal bone and approximately one third to one half of parietal and occipital lesions. In the case of brain tumours, the rule is a chronological sequence of two groups of signs and symptoms. First of all focal symptoms corresponding to a tumour lesion in the delineated region of the brain, later remote symptoms of a growing tumour, which lead to general symptoms of increased intracranial pressure. Various types of homonymous hemianopsia in tumorous

lesions along the suprachiasmatic pathway are described and discussed. Differential diagnosis of brain tumours consists in excluding haematomas, abscesses, granulomas, parasites and others [18].

## CONCLUSION

Scotomas in the visual field and the evaluation thereof with the use of perimetry represent an important issue for management, not only for ophthalmologists, but also for neurologists and neurosurgeons. Upon correct evaluation, the result of perimetry is useful at the very beginning before the actual examination of the patient or the use of imaging methods. However, it is not necessary to rely only upon the result, but on a correlation with the patient's clinical symptoms.

During the examination of our patient, we succeeded by means of interdisciplinary co-operation in determining a clear and quick diagnosis, after which the patient underwent a surgical solution as quickly as possible, by which we achieved a significant improvement of both her local and general condition.

## LITERATURE

- Jogi R. Basic ophthalmology. JP Medical; Ltd 2016; ISBN 93-5250-005-9.
- Rozsival P. Oční lékařství. 2. upravené vydání. Praha: Galén 2017.
- Oláh Z, Černák A, Dóci J, Ševčík J, Gerinec A. Očné lékařstvo: učebnica pre lekárske fakulty; Osveta, 1992; ISBN 80-217-0437-3.
- Skorkovská K. Perimetrie; Grada, 2015; ISBN 80-247-5282-4.
- Kedar S, Ghate D, Corbett JJ. Visual fields in neuro-ophthalmology. *Indian J Ophthalmol* 2011, 59(2):103-109. doi:10.4103/0301-4738.77013
- Warren M. Pilot Study on Activities of Daily Living Limitations in Adults With Hemianopsia. *American Journal of Occupational Therapy* 2009,63(5):626-633. doi:10.5014/ajot.63.5.626
- Schuetz S. The rehabilitation of hemianopic dyslexia. *Nature Reviews Neurology* 2009,5 (8):427-437. doi:10.1038/nrneuro.2009.97
- Bowers AR, Mandel AJ, Goldstein RB, Peli E. Driving with hemianopia, I: Detection performance in a driving simulator. *Invest Ophthalmol Vis Sci* 2009,50(11):5137-5147. doi:10.1167/iovs.09-3799
- Wood JM, McGwin G, Jr, Elgin J, Vaphiades MS, Braswell RA, DeCarlo DK, et al. On-road driving performance by persons with hemianopia and quadrantanopia. *Invest Ophthalmol Vis Sci* 2009,50(2):577-585. doi:10.1167/iovs.08-2506
- Čmelo, J.; Valášková, J.; Krásnik, V. The optic nerve drusen and hemodynamics. *Cesk Slov Oftalmol.* 2019,75(5):252-256. doi:10.31348/2019/5/2
- Furdová A, Babál P, Kobzová D. Orbital optic nerve sheath meningioma. *Cesk Slov Oftalmol.* 2018,74(1):23-30. doi:10.31348/2018/1/4-1-2018
- Pelak VS, Smyth SF, Boyer PJ, Filley CM. Computerized visual field defects in posterior cortical atrophy. *Neurology* 2011,77(24):2119-2122. doi: 10.1212/WNL.0b013e31823e9f2a
- Lee AG, Martin CO. Neuro-ophthalmic findings in the visual variant of Alzheimer's disease. *Ophthalmology* 2004,111(2):376-380. doi:10.1016/s0161-6420(03)00732-2
- Zhang X, Kedar S, Lynn MJ, Newman NJ, Biousse V. Homonymous Hemianopia in Stroke. *Journal of Neuro-Ophthalmology* 2006,26(3):180-183. doi: 10.1097/01.wno.0000235587.41040.39
- Kamal-Salah R, Baquero-Aranda I, Grana-Pérez MDM, García-Campos JM. Macular pattern dystrophy and homonymous hemianopia in MELAS syndrome. *BMJ Case Rep* 2015, 2015, bcr2014206499. doi:10.1136/bcr-2014-206499
- Latkany P, Ciulla TA, Cucchillo P, Malkoff MD. Mitochondrial maculopathy: geographic atrophy of the macula in the MELAS associated A to G 3243 mitochondrial DNA point mutation. *American Journal of Ophthalmology* 1999,128(1):112-114. doi:10.1016/S0002-9394(99)00057-4
- Adadj E, Mansouri K, Borruat, FX. Mitochondrial DNA (mtDNA) A 3243G mutation associated with an annular perimacular retinal atrophy. *Klinische Monatsblätter für Augenheilkunde* 2008,225(5):462-464. doi:10.1055/s-2008-1027257
- Huber A. Homonyme Hemianopsie bei Hirntumoren. *Klinische Monatsblätter für Augenheilkunde* 1988,192(5):543-550. doi:10.1055/s-2008-1050175