

PUPILLOTONIA AND ADIE SYNDROME

Horkovičová K., Popov I., Valašková J.

Department of Ophthalmology, Faculty of Medicine, Comenius University, and Ružinov University Hospital, Bratislava

The authors of the study hereby declare that no conflict of interest exists in the compilation, theme and subsequent publication of this professional communication, and that it is not supported by any pharmaceuticals company. The authors further declare that this study has not been submitted to any other journal or printed elsewhere, with the exception of congress abstracts and recommended procedures.

Received: 23 April 2020

Accepted: 18 August 2020

Available online: 20 December 2020



MUDr. Kristína Horkovičová
Klinika oftalmológie, Lekárska
fakulta Univerzity Komenského
a Univerzitná nemocnica,
Nemocnica Ružinov, Bratislava
k.horkovicova@gmail.com

SUMMARY

The aim of the work is to approach the examination of the pupil with a focus on anisocoria, its characteristics and approach to the diagnosis of pupillotonia and Adie's syndrome and its clinical evaluation. Pupil function is important not only in neurophthalmological examination but also in general ophthalmological examination. First of all, we need to know how the reflex arc works in order to be able to exclude or confirm whether the parasympathetic or sympathetic is affected. It is also necessary to know the exact characteristics of the pupil, such as size, shape, placement, function and reaction to light and at close range. Only on this basis can we distinguish pathological features. We do not often encounter this diagnosis, but it is necessary to keep it in mind, especially in the field of neurophthalmology but also in general ophthalmology. We also present three cases of pupillotonia and Adie's syndrome, which we diagnosed at the Department of Ophthalmology, Faculty of Medicine, Comenius University, after the patient himself came by emergency admission or was sent directly to ophthalmology clinic. In the discussion, we present various other diagnoses, where the reflex arc may not be affected, but the pathological pupil is caused by intraocular tumors, general systemic diseases and, last but not least, local therapy or alkaloids.

Key words: anisocoria, pupil, pupillotonia, Adie syndrome, pilocarpine

Čes. a slov. Oftal., 76, 2020, No.5, p. 232–235

INTRODUCTION

Pupillotonia is relatively little known among ophthalmologists as well as among neurologists, and is often the source of diagnostic errors or confusion. The pathology in itself is practically harmless, and is often mistaken for far more serious clinical pictures. Pupillotonia is distinguished partially by practically absent reaction to light, but also by its particular tonic manner of contraction and decontraction of the pupil in near gaze. As a rule it appears in middle age, between the 20th and 40th year of life, and is more prevalent in women in a ratio of 2:3 [1,2]. Young adults (more often women than men) find that they have one pupil larger than the other, or that they are unable to focus with one eye. Pupillotonia is characterised as postganglionic parasympathetic denervation of the intraocular muscles. It is often combined with a dysfunction to loss of tendon reflexes, primarily of the patellar and Achilles tendon. This image is then referred to as Adie syndrome. A diagnosis of pupillotonia is confirmed by 4 symptoms, in which the first

is insufficient or entirely absent reaction to light, manifested as uneven pupil contraction, or complete paresis of the sphincter. The second is accommodative paresis (objectively changing dioptric power of the refractive apparatus and subjective need for constantly different dioptric correction. The third is cholinergic hypersensitivity of denervated muscles – sphincter and ciliary muscle. Upon a minimal concentration of 0.05 %, 0.125 % and 0.5 % coll. pilocarpine, which in a healthy eye does not cause changes of accommodation, pupil size contracts within 5-10 minutes and remains in miosis for several hours, depending on the degree of sensitivity to cholinergic substances. The last symptom is a profuse and tonic reaction of the pupil in near gaze, in which reaction to convergence is preserved [1-7].

CASE REPORTS

Case Report 1

In July 2016, a 35 year old patient reported to our centre via emergency admission, stating that in the last few

days he had been suffering from intermittent pain in the right eye and right side of the head, as well as intermittent attacks of blurred vision. Subjectively, according to the patient's own words, the attack always begins when driving, upon intense gaze and concentration. He had suffered such an attack before our examination, but had not sought an ophthalmologist at the time. At the examination he had visual acuity of 6/6 in both eyes according to Snellen's optotypes. The patient was treated for ocular hypertension with antiglaucomatous agents, upon examination intraocular pressure was 18 Torr in the right eye and 16 Torr in the left eye. Examination of the anterior and posterior segment was without a pathological finding. The patient was not being treated for any general pathology. Upon emergency admission a neurological examination was performed, as well as a brain scan by computer tomography (CT), in which the finding was negative. Subsequently OCT of the macula and optic nerve papilla of both eyes was performed, without pathology. During outpatient examination of the patient, measurement of pupils was first conducted on a Lenstar LS 900 instrument. This was followed by a pharmacological pupillary test: - pupil before application of coll. pilocarpine 0.125 % gtt: o.dx. 4.57 mm and o.sin. 3.90 mm, after application of pilocarpine 0.125 % gtt: o.dx. 2.82 mm and o.sin. 3.50 mm (Fig. 1, 2). On this basis we concluded a diagnosis of pupillotonia. The patient is continuing to use coll. pilocarpine 0.125 % gtt locally according to requirement, i.e. approximately one drop every 5 days.

Case Report 2

In March 2018, again via emergency admission, a 37 year old patient reported to us, stating that the pupil of

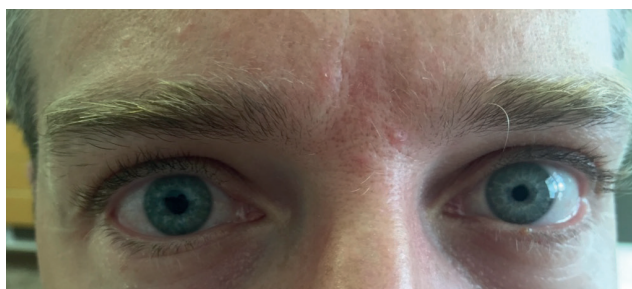


Fig. 1. Patient with anisocoria in right eye

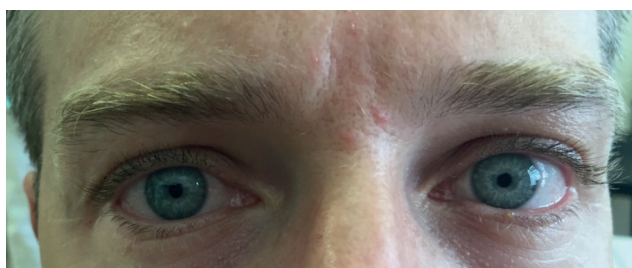

Fig. 2. Patient after application of coll. pilocarpine 0.125 % gtt and subsequent contraction of pupil in right eye

her right eye had ceased to react. The patient negated injury, and stated that at the time she was writing her thesis. Subjectively she was unable to focus on close objects. She was not being treated for any general pathology. An examination of visual acuity recorded 6/6 bilaterally on Snellen's optotypes, intraocular pressure was within the norm in both eyes. An examination of the anterior and posterior segment was without a pathological finding. Upon emergency admission a neurological examination and CT head examination were performed, with a negative conclusion. Upon convergence the patient's anisocoric pupil contracted. We subsequently performed a pharmacological test, in which we used coll. pilocarpine 0.125 %, with a positive result. We concluded a diagnosis of pupillotonia.

Case Report 3

In April 2018 a patient reported to our neuro-ophthalmologic outpatient department, stating that she had suffered from anisocoria since 2010. In 2012 she had been examined at our department, with a conclusion of anisocoria of unclear etiology. At that time the patient was referred for a neurological and CT examination, but did not report back with the results. At an examination the patient subjectively stated that she especially perceived a difference in near and distance vision, in which focusing was impaired in her left eye. Upon an examination on Snellen's optotypes, visual acuity of 6/6 was recorded in the right eye and 6/12 in the left eye, with correction of -0.75 Dsph 6/6. Examination of the anterior and posterior segment was without a pathological finding. In 2012 the patient also underwent an MRI examination, USG of carotids and a VEP examination, which were negative. The performed neurological examination demonstrated only weaker or absent reflexes in the lower limbs. The patient was not being treated for any general pathology. At a check-up we examined the patient for convergence, in which the pathological pupil contracted. We subsequently conducted a pharmacological test with coll. pilocarpine 0.125 %, which we applied, evaluating the test after 30 minutes. The result was positive, and the patient's anisocoric pupil contracted. Since the patient had been examined also at a neurological department in the past and has weak reflexes in the lower limbs, we concluded a diagnosis of Adie syndrome.

DISCUSSION

In addition to other parts of the eye, the pupil itself is examined within the framework of an ophthalmological examination. In the examination we evaluate the shape, size, placement, colour and last but not least direct and indirect reaction to light and pupil reaction at close range. During the examination, pupil reactions of both eyes are compared against one another, and as a result this examination is beneficial only in the case of unilateral or asymmetrical dysfunctions. Different pupil

width – anisocoria – reflects the state of innervation of the pupil muscles by autonomous nerves. It is present in approximately 15-20 % of the population. A difference of less than 1 mm between the two sides upon normal reactions is evaluated as physiological. Unilateral affliction of the sympathetic or parasympathetic efferent pathway causes pathological anisocoria [3,6].

In the case of suspicion of a pathological pupil reaction, it is necessary for the patient to be examined by an ophthalmologist. However, the given problem need not be first encountered only by an ophthalmologist or other specialist such as a neurologist, neurosurgeon, internal medicine specialist or general practitioner. In some cases patients recognise the condition at home by themselves, or are notified by their acquaintances. The main differential diagnosis which should be taken into consideration upon an enlarged pupil is palsy of the third cranial nerve, pharmacological mydriasis, tonic pupil, processes on the iris such as post-traumatic states, alkaloids or tumours, or states following reactions. Our three patients noticed the condition themselves, when they had problems focusing. Anisocoria is defined as unequal pupil width, which is sometimes pronounced and sometimes only inconspicuous. It is a common finding, affecting approximately 20 % of the population. A physiological model of pupils is described up to a difference in width of 0.5 mm. Over 0.5 mm anisocoria is described as pathological. Etiology of the pathology can vary. For diagnosis of pupillomotor dysfunction it is necessary to take all causes into account – mainly life-threatening conditions: paresis of the sympathetic nervous system (Horner syndrome, post-traumatic and post-surgical damage), dysfunction of the parasympathetic nervous system (sudden stroke, intracranial hypertension, aneurysm, tumours, carotid-cavernous fistula, iatrogenic (after surgery, trauma, instillation of drops, exposure of eye to anti-cholinergic drugs), Adie (tonic) pupil syndrome and finally physiological anisocoria, which we differentiate by means of pharmacological tests. On the basis of a pilocarpine test, pupillotonia was confirmed in two of our patients, and Adie syndrome in one patient, since the latter also had other neurological complaints following examination by a neurologist. On first impression it sometimes appears that this concerns a general, serious pathology, which may take the form of metastases in the brain, up to simple cases. It is necessary to remember that a carefully recorded medical history assists us in many cases. The patients in our case reports were treated with coll. pilocarpine 0.125 %, which was sufficient.

In some cases pupil dysfunction may occur also in pupils with intraocular tumours or tumours in the region of the eye socket. In many cases these are patients in whom we determine a tumorous pathology only by

means of ocular examination, and also patients who have undergone for example stereotactic radiosurgery, gamma knife or brachytherapy. It is necessary not to underestimate anisocoria, because it may be one of the first symptoms in patients with malignant melanoma of the corpus ciliare, and is first noticed by patients themselves or by their acquaintances [8]. It is also necessary to remember that anisocoria in connection with pain may be caused by an acute glaucoma attack [9].

Zhang describes a patient who had Adie pupillotonia associated with peripheral sensory polyneuropathy, in whom primary small-cell carcinoma of the mediastinum was ultimately demonstrated. This coincidence is very rare, but it is necessary also to consider pathologies that do not relate only to ophthalmology, but which may be associated also with other general disorders [10].

In the spectrum of causes of anisocoria, mydriasis in one eye is mostly isolated, which is a benign condition, for example a pupil with pupillotonia or a state following local or general application of mydriatics. These substances include alkaloids, which are contained in certain plants, in particular jimson weed (*Datura stramonium*), deadly nightshade (*Atropa belladonna*) or black henbane (*Hyoscyamus niger*). These are highly toxic plants, which are capable of causing fatal poisoning. Slight intoxication may be manifested in unilateral or bilateral mydriasis [11].

If we exclude other causes, we often conclude the diagnosis as pupillotonia, or in the case of subdued reflexes as Adie syndrome. In the case of pupillotonia or Adie syndrome we may markedly alleviate everyday life conditions for patients. Poor focusing in distance or near vision seriously impairs quality of life. Upon the use of coll. pilocarpine 0.125 %, visual acuity is radically improved, with an attendant improvement in quality of life. Despite the more rapid progression of cataract upon the use of pilocarpine, we nevertheless recommend its use for cataract patients. The aim and purpose of local therapy of pupillotonia is to contract the pupil as prevention against excessive light exposure and phototoxicity of the photosensitive cells of the macula. Dosage of coll. pilocarpine 0.05 % - 0.5 % is influenced by the light conditions that patients currently inhabit. It is necessary to instruct patients that if they are in an external environment in which there is an excessive influence of solar and UV radiation, it is necessary to use drops several times per day.

CONCLUSION

Anisocoria as such may or may not be caused by a serious systemic pathology. However, upon an ophthalmological examination it is necessary not to neglect pupillotonia or Adie syndrome, even if we do not encounter this in practice as often as other ophthalmological diagnoses. It may be the first warning signal, which, if identified during a targeted and timely diagnosis, can resolve patients' complaints.

LITERATURE

1. Yanoff M, Duker JS. *Ophthalmology: Expert Consult.com*. 4. ed. Philadelphia, Pa.: Elsevier Saunders; 2014; 1404 s.
2. Jirásková N. *Neurooftalmologie: minimum pro praxi*. 1. vyd. Praha: Triton, 2001. 124 s. ISBN 8072541773.
3. Otradovec J. *Klinická neurooftalmologie*. Grada; 504 s.
4. Freedman KA, Brown SM. Topical Apraclonidine in the Diagnosis of Suspected Horner Syndrome. *Journal of neuro-ophthalmology*. 2005;25(2):83-85. Available from: https://journals.lww.com/jneuroophthalmology/Fulltext/2005/06000/Topical_Apraclonidine_in_the_Diagnosis_of.4.aspx. DOI: 10.1097/01.WNO.0000165108.31731.36.
5. Batawi H, Micieli JA. Adie's tonic pupil presenting with unilateral photophobia successfully treated with dilute pilocarpine. *BMJ Case Rep*. 2020;13(1):e233136. Available from: <https://casereports.bmj.com/content/13/1/e233136>.
6. Rozsival P. *Oční lékařství*. 2. Galen; 2017. 252 s.
7. Hoffing RAC, Lauharatanahirun N, Forster DE, Garcia JO, Vettel JM, Thurman SM. Dissociable mappings of tonic and phasic pupillary features onto cognitive processes involved in mental arithmetic. *PloS One*. 2020;15(3):e0230517. Available from: <https://journals.plos.org/plosone/article?id=10.1371/journal.pone.0230517>.
8. Furdová A, Juhás J, Šramka M. Ciliary body melanoma treatment by stereotactic radiosurgery. *Cesk Slov Oftalmol*. 2018;73(5-6):204-210. Available from: <http://www.cs-ophthalmology.cz/cs/journal/articles/31>.
9. Furdová A, Horkovičová K, Justusová P, Šramka M. Is it sufficient to repeat LINEAR accelerator stereotactic radiosurgery in choroidal melanoma? *Bratisl Med J*. 2016;117(08):456-62. Available from: <https://pubmed.ncbi.nlm.nih.gov/27546698/>. DOI: 10.4149/BLL_2016_089.
10. Zhang L, Luo S, Jin H, Lv X, Chen J. Anti-Hu Antibody-Associated Adie's Pupil and Paraneoplastic Sensorimotor Polyneuropathy Caused by Primary Mediastinal Small Cell Carcinoma. *Front Neurol*. 2019;10:1236-1236. Available from: <https://www.ncbi.nlm.nih.gov/pmc/articles/PMC6901962/> DOI: 10.3389/fneur.2019.01236.
11. Žiak P, Kapitánová K. Pupillary abnormalities in childhood – 2 case presentations. *Cesk Slov Oftalmol*. 2019; 75 (3):145-149. Available from: <http://www.cs-ophthalmology.cz/en/journal/articles/12>. DOI: 10.31348/2019/3/5.