

# INCIDENCE OF CATARACT FOLLOWING IMPLANTATION OF A POSTERIOR-CHAMBER PHAKIC LENS ICL (IMPLANTABLE COLLAMER LENS) – LONG-TERM RESULTS

Kocová H.<sup>1</sup>, Vlková E.<sup>1</sup>, Michalcová L.<sup>1</sup>, Rybářová N.<sup>1</sup>, Motyka O.<sup>2</sup>

<sup>1</sup>Department of Ophthalmology, University Hospital and Faculty of Medicine, Masaryk University Brno  
Head: Prof. MUDr. Eva Vlková, CSc.

<sup>2</sup>Nanotechnology Centre, VŠB – Technical University of Ostrava

*The authors of the study declare that no conflict of interest exists in the compilation, theme and subsequent publication of this professional communication, and that it is not supported by any pharmaceuticals company.*

## SUMMARY

**Aim:** To evaluate late postoperative complications, especially cataract occurrence, its morphological type and factors affecting its development in patients implanted with ICL (Implantable Collamer Lens).

**Methods:** We analysed results of ICL implantation in 34 patients (type ICM V4 for myopia, ICH V3 for hyperopia, TICM V4 for astigmatism) in our department between 1998 and 2013. It comprised 62 eyes (40 myopic and 22 hyperopic). Seven eyes with toric ICL implanted were included into these groups according to spherical equivalent (SE). The average follow-up period was  $10.5 \pm 3.5$  years. We examined: uncorrected and best-corrected visual acuity (UCVA and BCVA), SE, ICL vaulting (using anterior segment OCT) and occurrence of late postoperative complications, especially cataract formation in 2 groups of patients – myopes and hyperopes.

**Results:** Among the most common late postoperative complications were pigment dispersion in 27 eyes, 43,5% (12 myopic eyes and 15 hyperopic eyes) and cataract formation. Lens opacities occurrence, including opacities without loss of BCVA, was observed in 18 eyes (29%). Opacities affecting visual acuity were observed in 10 eyes (16,1%). Cataract significantly affecting visual acuity occurred in 7 eyes, i.e. 11,3%, (in 5 myopic eyes and 2 hyperopic eyes). In these eyes, ICL removal and cataract surgery with implantation of posterior chamber intraocular lens (PC IOL) was performed.

The most common morphological type of cataract were anterior subcapsular opacities (83.3%), the average time of onset was  $3.4 \pm 1.9$  years after ICL implantation.

We did not prove statistically significant association neither between cataract occurrence and age at the time of surgery, nor between cataract occurrence and higher preoperative spherical equivalent. We did not prove significant association between cataract occurrence and low vault, however in 7 eyes after cataract surgery and ICL removal we do not know the vault values.

In one eye uveitis with cystoid macular oedema was observed, in two highly myopic eyes repeated ICL dislocation and cataract occurred. In both of these cases ICL was removed.

**Conclusions:** According to our experience, implantation of ICL in moderate and high ametropia was relatively safe when assessing long-term outcomes. Among the most common complications were pigment dispersion and anterior subcapsular cataract formation. Cataract can be managed effectively surgically with good refractive outcomes without loss of BCVA. However loss of accommodation after cataract surgery and risk of vitreoretinal complications must be considered.

**Key words:** ICL (Implantable Collamer Lens), posterior chamber phakic intraocular lens, refractive surgery, cataract occurrence

Čes. a slov. Oftal., 73, 2017, No. 3, p. 87–93

## INTRODUCTION

ICL (intraocular contact lens, intraocular collamer lens) is a posterior-chamber phakic intraocular lens, which is placed behind the iris with haptics into the sulcus ciliaris. It is a plate-haptic type lens with a central convex-concave optic zone. It is suitable for correction of medium and higher refractive errors. It is produced from the material collamer – copolymer collagen and hydroxyethylmethacrylate (19), highly biocompatible material. A “vault” is created between the anterior surface of the patient’s own lens and the posterior surface of the ICL (4). Upon low vault values (see

below), it is possible to expect complications such as the development of cataract, whereas a high vault may result in closure of the anterior chamber angle.

The design of ICLs has undergone several changes. The V1 version differed from the older V0 version in the shape of the haptics, version V2 was improved with orientation signs and had a higher vault, version V3 was created with the extension of the optic part, and a further raising of the vault was implemented in version V4 (9). Version V4 model plus, known as Visian ICL, differs in the type of solution in which the lens is stored and the length of the orientation signs in toric variants. The latest types of ICL with “CentraFLOW™” (version V4c) enable



MUDr. Hana Kocová  
Oční klinika FN Brno a LF MU  
Jihlavská 20  
625 00 Brno  
e-mail: hana.kocova7@gmail.com

through flow of chamber fluid through a small opening in the centre of the optic part, and therefore unlike older types of ICL it is not necessary to perform laser iridectomy preoperatively. The opening also facilitates the removal of viscoelastic material during the actual procedure, and helps preserve the nutrition of the patient's own lens (8,2).

The length of the Visian ICL (V4b) lenses used most often at present is 11.6 to 13.7 mm, the diameter of the optic zone is 4.9 to 5.8 mm. They are available in dioptric strength of -0.5 D to -18 D, toric variants are available in the same scope of spherical dioptres with astigmatic correction of +0.5 D to +6 D, graded at intervals of 0.5 D. ICLs for correction of hypermetropia are available in dioptric strength of +0.5 D to +10 D, toric variants within the scope of 0 D to + 10 D with astigmatic correction of +0.5 to +6 D (20).

The objective of this study was to evaluate the long-term complications of implantation of ICL, in particular the incidence of cataract as frequently discussed in the literature.

## MATERIAL AND METHODOLOGY

A retrospective study incorporated 62 eyes (40 myopic and 22 hypermetropic) of 34 patients (8 men and 26 women), who underwent implantation of an ICL (type ICM V4 for myopia, ICH V3 for hypermetropia, ICM V4 for astigmatism) at the department of ophthalmology at the Faculty of Medicine, Masaryk University and University Hospital in Brno, between the years of 1998 and 2013, and who attended regular postoperative follow-up examinations. The patients were divided into 2 groups – myopic and hypermetropic. Seven eyes with an implanted toric ICL were included in the group according to spherical equivalent of refraction.

The indication criteria for implantation of an ICL covered motivated patients with realistic expectations, with a medium to higher refractive error – myopia -3 to -20 Dsf, hypermetropia +3 to +17 Dsf, astigmatism +0.5 to +6.0 Dcyl, age 21 – 45 years, stable refraction, endothelial density >2000 cells/mm<sup>2</sup> in patients aged over 25 years and >2500 cells/mm<sup>2</sup> in patients aged under 25 years, anterior chamber depth (ACD) >2.8 mm in hyperopes, >3.0 mm in myopes. In 1 myopic patient the level of the refractive error exceeded the maximum dioptric strength of the available ICL.

Patients with ocular pathologies such as diseases of the cornea, pseudoexfoliation syndrome, pigment dispersion syndrome, uveitis, glaucoma, cataract, malignant degeneration of the retina, anamnesis of retinal detachment, as well as patients with an allergy to collagen and serious general pathologies were excluded from the study.

Preoperatively we performed a complete examination before the refractive procedure, including an examination of contrast sensitivity, endothelial microscopy, ultrasonic biometry and corneal topography (Orbscan Iiz). The values obtained by corneal topography – ACD and horizontal white-to-white (WTW) diameter of cornea – were necessary in order to determine the size of the ICL. The dioptric strength of the ICL was stipulated with the aid of a calculator from the STAAR Surgical company. 2 Nd:YAG laser iridotomies were perfor-

med preoperatively, in our first 3 patients iridotomies were performed perioperatively.

The procedure took place under general anaesthesia, analgesation, in isolated cases under local anaesthesia. A folded ICL was implanted by means of a corneal micro-incision of the size of 2.8 mm, extended to 3 – 3.2 mm, with two auxiliary paracentesis with a size of 0.8 – 1.0 mm. The ICL was implanted with the aid of an injector, cautiously placed into the posterior chamber into the sulcus ciliaris, the corneal incision was sutured using 1 suture.

Postoperatively patients were administered antibiotics with a steroid in a combined preparation 5x daily for a period of 2 weeks, with progressive discontinuation (total period 6 weeks). All the operations were performed by a single surgeon.

Follow-up examinations took place at 1 day, 1 week, 1 month, 3 months, 6 months and then once per year. The average observation period was  $10.5 \pm 3.5$  years. We examined uncorrected and best corrected visual acuity (UCVA, BCVA), refraction on an automatic refractometer, biomicroscopy of the anterior segment, indirect ophthalmoscopy, non-contact tonometry, endothelial microscopy, corneal topography (Orbscan II z) and contrast sensitivity. At the last examination the central vault was also measured (i.e. dimension between the anterior surface of the lens and the posterior surface of the ICL in the centre, fig. 1) with the aid of OCT of the anterior segment (OCT Spectralis, Heidelberg engineering GmbH).

The parameters at the last examination were evaluated, i.e. on average 10.5 years after surgery.

## RESULTS

The preoperative characteristics of the patients are summarised in table 1.

As regards our postoperative refractive results, these have already been published (10) and exceed the framework of this publication, we shall mention on the values of visual acuity: UCVA in the group of myopes was  $1.0 \pm 0.37$ , in the group of hyperopes  $1.14 \pm 0.18$ .

The value of the central vault in the group of myopes was  $206.16 \pm 105.94$   $\mu\text{m}$  (range 10-427), in the group of hyperopes  $195.5 \pm 109.09$   $\mu\text{m}$  (range 20-404). This does not concern a statistically significant difference between the two groups.

Of late postoperative complications, the predominant were pigment dispersion syndrome and the occurrence of cataract. We recorded pigment dispersion syndrome in 27 eyes, i.e. 43.5%, of which 12 were myopic eyes (30%) and 15 hypermetropic eyes (68.2%). The incidence was statistically significant more frequently in the groups of hyperopes, as we expected with regard to the anatomical ratios of the hypermetropic eye (Pearson's Chi-squared test with Yates' continuity correction,  $p = 0.00845$ ). Pigmentary glaucoma did not occur in our cohort.

Any form of ocular opacity, including those without a deterioration of visual acuity, appeared in a total of 18 eyes, i.e. 29%. Of these we recorded cataract associated with a deterioration of visual acuity in 10 eyes, i.e. 16.1%. We observed anterior subcapsular opacities without effect on vision and without progression over time in 1 myopic eye (2.5%) and




Fig. 1 Vault measurement using anterior segment OCT

in 6 hypermetropic eyes (27.3%), incipient corticonuclear cataract without effect on vision in 1 myopic eye (2.5%). We observed incipient anterior subcapsular opacities in connection with a deterioration of BCVA by at least 2 rows in 3 myopic eyes (7.5%). Progressing cataract pronouncedly reducing vision, for which explantation of the ICL and cataract surgery with implantation of a posterior-chamber lens (PC IOL) was indicated, occurred in 7 eyes (11.3%), of which 5 were myopic eyes (12.5%) and 2 hypermetropic (9.09%).

The incidence of ocular opacities was significantly more frequent in the group of hyperopes ( $p=0.019$ ), the incidence of cataract with an influence on vision was comparable in both groups (Fischer exact test).

In 83.3% of eyes with cataract this concerned anterior subcapsular opacities, in 16.7% of eyes it concerned corticonuclear opacities (graph 1, fig. 2).

We did not observe any differences in the location of opacities between hyperopes and myopes. We could expect that in myopes opacities of the lens would predominate in the central periphery, and in hypermetropes in the centre, with regard to the shape of the ICL and the widest place of its optical part.

As regards the time of origin of cataract connected with a deterioration of visual acuity, in the group of myopes this was on average 3.13 years after surgery (in 1 eye 1 year after surgery, in 3 eyes 2 years after surgery, in 1 eye 3 years after surgery and subsequently 4, 5 and 6 years after surgery always in 1 eye). In the group of hyperopes, cataract occurred in 2 eyes of 1 patient, 2 years and 7 years after surgery (graph 2).

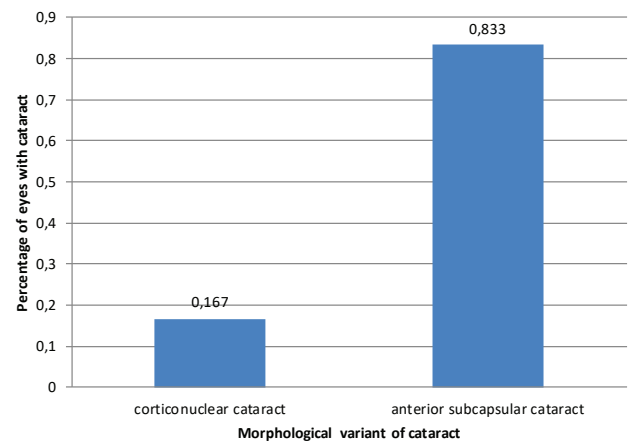
We measured vault values of 125  $\mu\text{m}$  to 1000  $\mu\text{m}$ , which the firm STAAR Surgical states as "safe", and in which we would not expect complications, in 78.7% of eyes, and values of less than 125 in 21.3% of eyes (10 eyes). Vault values of more than 1000  $\mu\text{m}$  did not occur in our cohort.

In eyes with a vault of less than 125  $\mu\text{m}$  we determined the occurrence of cataract in 2 cases: a small anterior subcapsular opacity without an impact on visual acuity occurred in 1 hypermetropic eye with a vault of 47  $\mu\text{m}$ . In 1 myopic eye with a vault of 119  $\mu\text{m}$  an anterior subcapsular cataract occurred, in which BCVA deteriorated to 0.32. In eyes with a known vault value we did not demonstrate a statistically significant association between low vault and the occurrence of cataract, in 7 eyes after explantation of ICL and cataract surgery the vault was not measured before surgery.

All patients in whom ICL explantation and cataract surgery with implantation of PC IOL was performed were satisfied, BCVA reached 1.0. Only in 2 eyes of one highly myopic patient

was there decentration of PC IOL following explantation of ICL and implantation of PC IOL. The PC IOL was explanted from the patient, who remained aphakic. At the last follow-up examination, BCVA in the right eye was 0.9 with correction of -5.25 Dsf and -0.75 Dcyl, BCVA in the left eye 1.0 with correction of -3.5 Dsf and -2.0 Dcyl.

Of other complications we recorded recurrence of uveitis in one myopic eye. An attack of uveitis occurred three times following implantation of ICL, always approximately with an interval of one month, the last attack leading to



Graph 1 Representation of morphological variants of cataract.

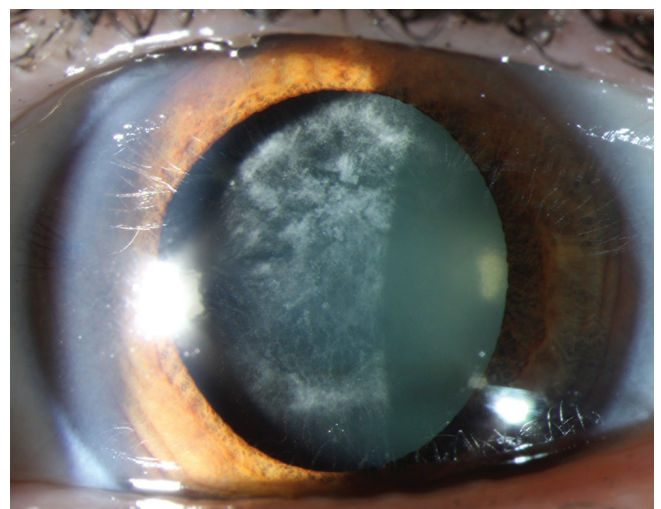


Fig. 2 Anterior subcapsular cataract in a myopic patient 11 years after ICL implantation

Table 1 Preoperative Demographics of the Study Population (10)

	Group Myopia, Mean ± Standard Deviation	Group Hyperopia, Mean ± Standard Deviation
Number of eyes	40,00	22,00
Age (years)	28,28 ± 6,25	26,95 ± 6,04
Gender (% female)	81,80%	66,70%
Manifest spherical equivalent (D)	-11,0 ± 4,45	5,62 ± 1,63
UCVA	0,04 ± 0,02	0,30 ± 0,26
BCVA after omitting amblyopic eyes	0,04 ± 0,02	0,30 ± 0,28
BCVA	0,82 ± 0,23	0,89 ± 0,23
BCVA after omitting amblyopic eyes	0,98 ± 0,23	0,98 ± 0,19
Endotelial cell density (cells/mm <sup>2</sup> )	2847,21 ± 217,81	2925,56 ± 329,94

the development of cystoid macular edema with papillary edema. The patient was repeatedly treated with corticoids locally and generally orally, once intravenously. One year after implantation of ICL, its explantation was performed on this patient. Following the termination of corticoid therapy and pacification of the finding – i.e. 3 years after explantation of the ICL – the patient underwent LASIK for correction of refractive error. Now, 8 years after implantation of the ICL, the patient is without complaints, UCVA in the right and left eye attains 1.0.

In 2 eyes of a highly myopic patient, repositioning of a dislocated ICL was performed, with subsequent explantation due to repeat dislocation and incipient cataract. During observation an increase in the axial length of 2 mm was recorded in this patient. Subsequently cataract surgery was performed on this patient with implantation of PC IOL. At the last follow-up examination UCVA was 1.0 and 0.9.

We did not record any progressive decrease of endothelial cells of the cornea. The average density of corneal endothelial cells at the last examination in the group of myopes was 2346.82 ± 214.27 cells/mm<sup>2</sup>, in the group of hyperopes 2455.45 ± 310.46 cells/mm<sup>2</sup>. The decrease of endothelial cells over the observation period in the group of myopes was 17.6%, in the group of hyperopes 16%. However, only 45% of patients reported for an examination by endothelial microscopy at the

last follow-up.

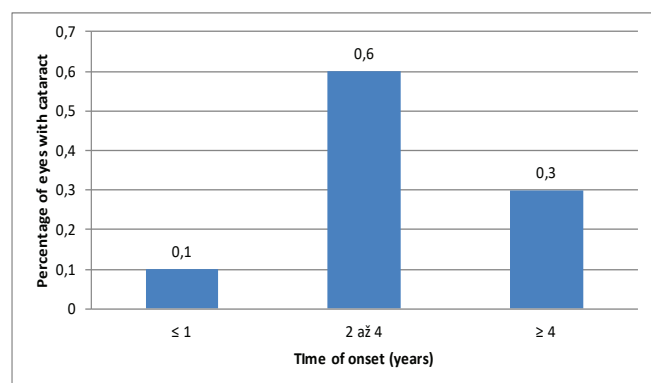
We did not record any vitreoretinal complications in our cohort.

### DISCUSSION

Upon implantation of ICL lenses, correct vault size appears to be very important. According to the recommendations of the firm STAAR Surgical, the ideal vault value is 250 to 500 μm, and we may expect complications in the case of a vault lower than 125 μm or a vault higher than 1000 μm. According to Gonvers, a vault value of ≥ 90 μm suffices, though he recommends a vault of ≥ 150 μm (5). The recommended vault value according to Fernandes is 400 - 600 μm (4).

It is evident that upon a low vault, contact between the ICL and the patient's own lens may occur, which may result in particular in an anterior subcapsular cataract, as well as in instability and rotation of the ICL and damage to the zonular apparatus. The occurrence of a cataract may be conditioned partially by intermittent or constant contact of the ICL with the lens, and partially by alteration of the flow of intraocular fluid, with an attendant breach of the nutritional ratios in the posterior chamber upon a low vault (4). The influence of accommodation has also been described, which upon a forward shift of the anterior pole of the lens may lead to intermittent contact between the ICL and the lens (1). On the other hand, an excessively high vault may cause complications such as closure of the chamber angle, pupillary block and pigmentary glaucoma (5).

Insufficient diameter of the ICL may lead to a primarily low vault immediately after surgery. As a result the theme of a correctly calculated size of the ICL is frequently discussed in the literature. The diameter of the ICL is most often calculated on the basis of the dimension of WTW and ACD. The size of the sulcus ciliaris is estimated from the dimension of the WTW with an addition of + 0.5 to 1.0 mm in myopes and + 0 to 0.5 mm in hyperopes (4). Measurement of WTW distance is therefore of key importance. It may be measured by a caliper or with the aid of Orbscan, Pentacam, IOL Master or Lenstar. In the case of measurement using these instruments, measurement by caliper may be suitable as a control. We thereby avoid possible imprecisions caused by



Graph 2 Representation of cataract according to morphological type

lesions in the region of the limbus, such as arcus senilis, pigmentation, neovascularisation etc. (13).

An alternative to measurement of WTW is measurement of STS (sulcus-to-sulcus) distance with the aid of UBM, measurement of ATA (angle-to-angle) or PTP (iris pigment end-to-pigment end) with the aid of OCT of the anterior segment. The most frequently used method remains WTW and ACD measurement. According to the summary study by Packer, the resulting vault based on WTW and STS measurement does not statistically significantly differ (13). According to another study by Reinstein, however, significantly higher predictability of the postoperative vault is attained by incorporating the dimension of STS into the calculation of the size of the ICL (15).

It has been demonstrated that reduction of the vault also occurs over the course of time (18). This may partially be due to the influence of the front-to-back dimension of the patient's own lens, which grows with age (4). Of interest here is also the influence of light conditions and pupil width upon measurement of the vault. Under photopic conditions and in pharmacologically induced miosis, a reduction of the vault occurs due to a backward shift of the ICL and the forward movement of the patient's own lens, whereas by contrast, under scotopic conditions and in mydriasis an increase of the vault occurs (11, 3).

Serious late complications recorded in our cohort included progressive cataract, which required explantation of the ICL and cataract surgery with implantation of PC IOL in 7 eyes (of which 2 eye remained aphakic following repeated dislocations of the PC IOL in one highly myopic female patient), explantation of ICL due to its repeated dislocations and development of an incipient cataract in two highly myopic eyes, and recurring uveitis in 1 eye.

We did not observe postoperative complications in patients following explantation of ICL and cataract surgery with implantation of PC IOL, with the exception of dislocation of PC IOL and its explantation in the above-mentioned patient. Nevertheless, cataract surgery involves a loss of accommodation, and serious complications may occur, such as retinal detachment. As a result it is necessary to instruct patients before implantation of ICL with regard to the potential necessity for secondary cataract surgery.

As regards the time of origin of cataract, this rather concerned late occurrence of cataract. Early occurrence of cataract is linked with perioperative trauma of the lens – we did not record this type of cataract.

Late occurrence of cataract is generally caused by a low vault – intermittent or constant contact of the ICL and the lens, or breach of the natural ratios in the posterior chamber. In our cohort it was this type of cataract that occurred.

We did not determine a statistically significant association between cataract and low vault, but in the already explanted ICL the vault value was not measured again before surgery. We also did not demonstrate a statistically significant association between the incidence of cataract and higher age at the time of surgery, or between the incidence of cataract and higher spherical equivalent preoperatively.

We demonstrated a significantly more frequent occur-

rence of cataract in hypermetropic patients, which we may explain by means of the anatomic ratios of the hypermetropic eye. At our centre ICL type ICH V3 were implanted in hyperopes and ICM V4 in myopes, these lenses have an identical vault height. The more frequent occurrence of cataract in hyperopes should therefore not be caused by the type of implanted lens. We did not demonstrate a significant difference between the incidence of symptomatic cataract in patients with an implanted ICL type ICH V3 and ICM V4. In the summary study by Fernandes, the incidence of cataract is described from 1.3% to 28% in the case of the type ICM V4 and 6% to 14.3% for type ICH V3 (4).

The situation is different upon a comparison of the incidence of cataract in the cases of lenses type ICM V3 and ICM V4. These lenses differ in the vault height. Type ICM V4 has a steeper curve and a vault higher by 0.13 to 0.21 mm than the older type ICM V3 (4). The authors concur that there is a more frequent occurrence of cataract in the case of type ICM V3 (16, 6). Sanders describes a significantly higher incidence of anterior subcapsular opacities in the group of patients with an implanted ICM V3 (12.6% in the group with ICM V3 and 2.9% in the group with ICM V4). In his study lower vault values were attained in patients with ICM V3, and an association was demonstrated between anterior subcapsular opacities of the lens and low vault (16).

In his publication, Gonvers also describes lower vault values in patients with an implanted ICM V3 lens. His cohort comprised 32 myopic eyes, of which 19 were implanted with an ICM V3 lens and 13 eyes with an ICM V4. Anterior subcapsular cataract occurred in 4 eyes, of which 3 cases occurred in the case of ICM V3. The observation period was 7.4 months (6).

A discussed theme in the contemporary literature is the advantages of the latest type of ICL, ICL V4c with a central opening, known as CentraFLOW™. In the case of this type of ICL it is not necessary to perform laser iridotomy preoperatively. The opening facilitates the through flow of chamber fluid, assists the preservation of nutrition of the patient's own lens (8, 2), and there should therefore be a lower incidence of cataract in patients with an implanted ICL V4c.

Bhandari compared the results of implantation of an ICL V4b lens in 62 myopic eyes and V4c in 10 myopic eyes. The observation period was 9 months. Anterior subcapsular opacities appeared in 6.9% of eyes with an implanted ICL V4b and 3.14% of eyes with an implanted ICL V4c. The authors recorded high intraocular pressure in 2 eyes with an ICL V4b, which was caused by impassable iridotomy (2). Shimizu compared the results of implantation of an ICL in 64 myopic eyes 5 years after surgery, in which one half of eyes had an implanted ICM V4b and one half ICM V4c. Only one asymptomatic anterior subcapsular cataract was recorded in the cohort, in a patient with an implanted ICL V4b. Postoperative elevation of intraocular pressure did not occur, and the values of intraocular pressure did not statistically significantly differ between the two groups (17). The long-term results of implantation of lenses with CentraFLOW™ are not yet available.

We did not observe serious complications such as pig-

mentary glaucoma and vitreoretinal complications in our cohort, and similarly no such complications occurred in the majority of foreign publications (7,12,14).

## CONCLUSION

According to our experiences, the implantation of ICL lenses appears to be relatively safe from a long-term perspective, and this concerns a full-value variant of surgical correction of medium and higher refractive errors. Its advantages are the preservation of accommodation in young patients,

reversibility of the procedure and excellent refractive results. The disadvantages of ICL implantation remain potential complications of the intraocular procedure. Of the serious late postoperative complications in our cohort, the predominant was the occurrence of anterior subcapsular cataract, more frequently in hyperopes, which can nevertheless be very well resolved, with excellent refractive results without a deterioration of BCVA. Sight-threatening complications such as endophthalmitis, progressive loss of endothelial cells, secondary glaucoma, vitreoretinal complications and bleeding did not occur in our cohort.

## LITERATURE

1. **Baikoff G, Lutun E, Wei J, et al.:** Anterior chamber optical coherence tomography study of human natural accommodation in a 19-year-old albino. *J Cataract Refract Surg*, 2004; 30(3): 696–701.
2. **Bhandari V, Karandikar S, Reddy JK, et al.:** Implantable collamer lens V4b and V4c for correction of high myopia. *J Curr Ophthalmol*, 2016; 27(3–4): 76–81.
3. **Du C, Wang J, Wang X, et al.:** Ultrasound Biomicroscopy of Anterior Segment Accommodative Changes with Posterior Chamber Phakic Intraocular Lens in High Myopia. *Ophthalmology*. leden 2012; 119(1): 99–105.
4. **Fernandes P, González-Méijome JM, Madrid-Costa D, et al.:** Implantable collamer posterior chamber intraocular lenses: a review of potential complications. *J Refract Surg Thorofare NJ* 1995. 2011; 27(10): 765–76.
5. **Gonvers M, Bornet C, Othenin-Girard P.:** Implantable contact lens for moderate to high myopia: relationship of vaulting to cataract formation. *J Cataract Refract Surg*, 2003; 29(5): 918–24.
6. **Gonvers M, Othenin-Girard P, Bornet C, et al.:** Implantable contact lens for moderate to high myopia: short-term follow-up of 2 models. *J Cataract Refract Surg*, 2001; 27(3): 380–8.
7. **Igarashi A, Shimizu K, Kamiya K.:** Eight-year follow-up of posterior chamber phakic intraocular lens implantation for moderate to high myopia. *Am J Ophthalmol*, 2014; 157(3): 532–539.
8. **Kawamorita T, Uozato H, Shimizu K.:** Fluid dynamics simulation of aqueous humour in a posterior-chamber phakic intraocular lens with a central perforation. *Graefes Arch Clin Exp Ophthalmol*, 2012; 250(6): 935–9.
9. **Kitahara M, Kamiya K, Igarashi A, et al.:** Long-term safety outcomes of posterior chamber phakic intraocular lens implantation for high myopia. *Kitasato Med J*, 2012; 42(2): 111–119.
10. **Kocová H, Vlková E, Michalčová L, et al.:** Implantation of posterior chamber phakic intraocular lens for myopia and hyperopia – long-term clinical outcomes. *J Fr Ophthalmol [Internet]*. [citován 31. březem 2017]; Dostupné z: <http://www.sciencedirect.com/science/article/pii/S018155121730027X>.
11. **Lindland A, Heger H, Kugelberg M, et al.:** Changes in vaulting of myopic and toric implantable collamer lenses in different lighting conditions. *Acta Ophthalmol (Copenh)*, 2012; 90(8): 788–91.
12. **Moya T, Javaloy J, Montés-Micó R, et al.:** Implantable Collamer Lens for Myopia: Assessment 12 Years After Implantation. *J Refract Surg*, 2015; 31(8): 548–56.
13. **Packer M.:** Meta-analysis and review: effectiveness, safety, and central port design of the intraocular collamer lens. *Clin Ophthalmol Auckl NZ*, 2016; 10: 1059–77.
14. **Pesando PM, Ghiringhello MP, Di Meglio G, et al.:** Posterior chamber phakic intraocular lens (ICL) for hyperopia: ten-year follow-up. *J Cataract Refract Surg*, 2007; 33(9): 1579–84.
15. **Reinstein DZ, Lovisolo CF, Archer TJ, et al.:** Comparison of Postoperative Vault Height Predictability Using White-to-White or Sulcus Diameter-based Sizing for the Visian Implantable Collamer Lens: [1]. *J Refract Surg Thorofare*, 2013; 29(1): 30–5.
16. **Sanders DR, Vukich JA.:** Incidence of Lens Opacities and Clinically Significant Cataracts With the Implantable Contact Lens: Comparison of Two Lens Designs. *J Refract Surg*, 2002; 18(6): 673–82.
17. **Shimizu, Kimiya MD, PhD; Kamiya, Kazutaka MD, PhD; Igarashi, Akihito MD, PhD;:** Long-Term Comparison of Posterior Chamber Phakic Intraocular Lens With and Without a Central Hole (Hole ICL and Conventional ICL) Implantation for Moderate to High Myopia and Myopic Astigmatism: Consort-Compliant Article. *Medicine*, 2016, 95(14).
18. **Schmidinger G, Lackner B, Pieh S, et al.:** Long-term changes in posterior chamber phakic intraocular collamer lens vaulting in myopic patients. *Ophthalmology*, 2010; 117(8): 1506–11.
19. **The Implantable Contact Lens for Myopia (ITM) Study Group; Vukich J. A., Sanders D. R., Barnett R., et al.:** U.S. Food and Drug Administration clinical trial of the Implantable Contact Lens for moderate to high myopia. *Ophthalmology*, 2003; 110(2): 255–66.
20. **Visian ICL User Guidance [Internet]**. is-suu. [citován 3. duben 2017]. Dostupné z: [https://issuu.com/pommerli/docs/visian\\_icl\\_training\\_finalpres](https://issuu.com/pommerli/docs/visian_icl_training_finalpres).