

# INTRAOPERATIVE OPTICAL COHERENCE TOMOGRAPHY IN VITREORETINAL SURGERY

## SUMMARY

**Aim:** To provide a survey of the current clinical use of intraoperative optical coherence tomography (iOCT), especially in the context of our own vitreo-retinal experience.

**Methods:** Retrospective evaluation of casuistic cases of typical diseases of the retina, which were treated by standard pars plana vitrectomy (PPV) using iOCT integrated into an operating microscope OPMI Lumera 700 / Rescan 700 (Zeiss). Auxiliary techniques: best corrected visual acuity (BCVA) was tested on ETDRS charts, biomicroscopy was performed using a 78D lens, and optical coherence tomography (OCT) using Zeiss Cirrus equipment. Operations were carried out under retrobulbar anaesthesia by three-port 23G PPV and using a Constellation surgical unit (ALCON).

**Results:** Three cases of 2 females (vitreoretinal interface disorders) and 1 male (proliferating diabetic retinopathy) of average age of 63 years are reported. In the former 2 cases, the follow-up period was 3 months, and the male with diabetic retinopathy was followed for 15 months. All surgical interventions using iOCT took place without either perioperative or postoperative complications. In all cases, full anatomical success was achieved. In the former two cases, there was a marked improvement of BCVA, and in the latter case, long-term stabilization of a very good initial BCVA.

**Conclusion:** Surgical-microscope integrated OCT is giving the surgeon simultaneous immediate control of both surgical manipulations and OCT visualization. The results are a perfect view and information for the surgeon, and improved outcomes for the operated eye.

**Key words:** intraoperative optical coherence tomography, vitreoretinal surgery

Čes. a slov. Oftal., 73, 2017, No. 3, p. 94–100

## INTRODUCTION

The technical possibilities of intraocular surgery have been pronouncedly extended in recent decades. At the same time there has been a rapid development of auxiliary display techniques, surgical instruments and surgical microscopes. Optical coherence tomography (OCT) has become a significant method in the diagnosis, therapeutic analysis and screening of pathologies of the ocular structures of the anterior and posterior segment of the eye. This technique provides significant anatomical data, such as in particular the possibility of contactless examination of the retina with high resolution in a transverse cross-section in layers [1]. In recent years technical possibilities have advanced to such an extent that it is possible to examine ocular structures using an OCT instrument and perioperatively with the use of an ocular microscope with an integrated OCT instrument. This linkage enables the surgeon to observe immediate response upon manipulation of the ocular tissue, and to specify the current situation of the anatomy of the treated structure.

The significance of the use of intraoperative OCT (iOCT) has been confirmed in a number of studies [2-4]. Display with the aid of iOCT is useful in vitreoretinal surgery [5], surgery of the anterior segment [6] and also glaucoma [7]. A typical procedure in surgery of the posterior segment which it is possible to monitor perioperatively with the aid of iOCT is work with surface membranes on the retina.

The objective of this article is to provide an overview of the current situation with the use of iOCT and to present our own experience with this technology.

## METHODOLOGY

We retrospectively evaluate typical examples of the use of iOCT in case reports. A common feature of all is the following universal examination techniques: determination of best corrected visual acuity (BCVA) on an ETDRS table, biomicroscopy and optical coherence tomography (OCT) on a ZEISS Cirrus instrument. The case reports include the usually indicated diagnoses and the patients operated on signed a regular informed consent form for the planned procedure.


### Specification of microscope with integrated OCT

OPMI Lumera 700 / Rescan 700 Carl Zeiss is a microscope with an integrated iOCT module. Inbuilt iOCT does not represent increased demands on the time of the operation or a risk of loss of sterility of the operating field. The iOCT module is integrated into the head of the microscope and does not restrict the functions or quality of display. OCT scans in HD resolution are projected into the right eyepiece of the microscope in real time. The surgeon may thus obtain simultaneous OCT scans of the observed area upon display of the anterior and posterior segment of the eye. iOCT can be controlled using the pedal of the microscope or with the aid of a Callisto system. The surgeon may designate the position of the scan, recording of the row or grid of the model of OCT scans, and the possibility of examining them. In addition to monitoring the anatomical structures, it is possible

Dusová J., Hejsek L., Stepanov A., Marak J., Jirásková N.

Department of Ophthalmology, University Hospital Hradec Králové  
Head prof. MUDr. Naďa Jirásková, Ph.D., FEBO

*The authors of the study declare that no conflict of interest exists in the compilation, theme and subsequent publication of this professional communication, and that it is not supported by any pharmaceuticals company.*



MUDr. J. Dusová, Ph.D.  
Oční klinika  
Fakultní nemocnice Hradec Králové  
Sokolská 581  
500 05 Hradec Králové  
e-mail: jaroslava.dusova@fnhk.cz

also to conduct measurement of thickness (e.g. of cornea), depth of the angle of the anterior chamber. iOCT has high resolution of the spectral region, uses a wavelength of 840 nm and the scan speed is 27 000 images per second. The parameters of scanning are as follows: depth 2.0 in tissue, axial resolution 5.5  $\mu\text{m}$  in tissue, scanning of setting of length 3-16 mm and rotation of cross section within scope of 360°.

### Surgical technique

All the procedures were performed in retrobulbar anaesthesia. In all cases non-suture transconjunctival 23G pars plana vitrectomy (23G PPV) was performed with the aid of a Constellation instrument (ALCON, Ft Worth, TX, USA). After visualisation using membrane blue (MembraneBlue-Dual®, DORC), peeling of the internal limiting membrane (ILM) was performed with the aid of Eckhardt forceps (Alcon). Intraocular retinal tamponade by air was used at the end of the procedure in all cases.

### Case report – idiopathic macular hole (IMH)

A woman aged 66 years perceived deformation of the image in the right eye persisting for 4 months. Overall she was healthy, with negative results for observed pathologies. Initial BCVA was 20/80, ophthalmoscopically and with the aid of OCT idiopathic macular hole (IMH) was confirmed in stage Gass 2 (fig. 1-2). The further intraocular finding was normal.

The pathology was resolved by means of a standard operation with ILM peeling. The course of the procedure was monitored with the aid of iOCT (fig. 3), which enabled full monitoring of the macular region even in a situation of impaired transparency of the ocular media by means of auxiliary colouring and intravitreal air (fig. 4 and 5). It was confirmed that iOCT visualises the course of ILM peeling, enables direct control of the traction performed by the surgeon on the vulnerable tissue of the macula, and thereby limits the risk of iatrogenic damage (fig. 6).

Upon the use of air tamponade, the patient maintained a prone head position for 5 days. The macular hole was closed and BCVA improved with a subjective reduction of metamorphopsia. At a follow-up examination 3 months after surgery, BCVA was 20/25 and on OCT the defect of the macula was completely closed (fig. 7-8).

### Case report – idiopathic epiretinal membrane (ERM)

This concerned a 70 year old woman with an impression of blurred vision in the left eye persisting for one month. The patient had corrected arterial hypertension, therapy was ongoing for approximately 10 years. Firm adherence of the vitreous body together with the epiretinal membrane caused tractional maculopathy with intraretinal thickening (fig. 9-10). The remaining finding was normal, with the exception of incipient cortical cataract. Initial BCVA was 20/100.

Standard PPV was performed with ERM peeling (fig. 11). After the absorption of the air tamponade, BCVA progres-

sively adjusted, with reduction of deformation of central vision. At a follow-up examination 3 months after the operation, BCVA was 20/32 and central retinal thickness in the macula had been reduced by 260  $\mu\text{m}$  (fig. 12-13).

### Case report – proliferative diabetic retinopathy with diabetic macular edema

A man aged 44 years was observed for type 1 diabetes mellitus 1 (persisting for 10 years), arterial hypertension (3 years) and hypercholesterolaemia (3 years). The patient was sent to our clinic for the purpose of resolving proliferative diabetic retinopathy in the right eye. Panretinal photocoagulation had not previously been performed (fig. 13). At the same time, extrafoveal diabetic macular edema was determined, which caused metamorphopsia. BCVA was 20/25.

During the operation, delamination of proliferations was performed, as well as ILM peeling in the macula and endolaser photocoagulation. The anatomy of gliovascular proliferation on

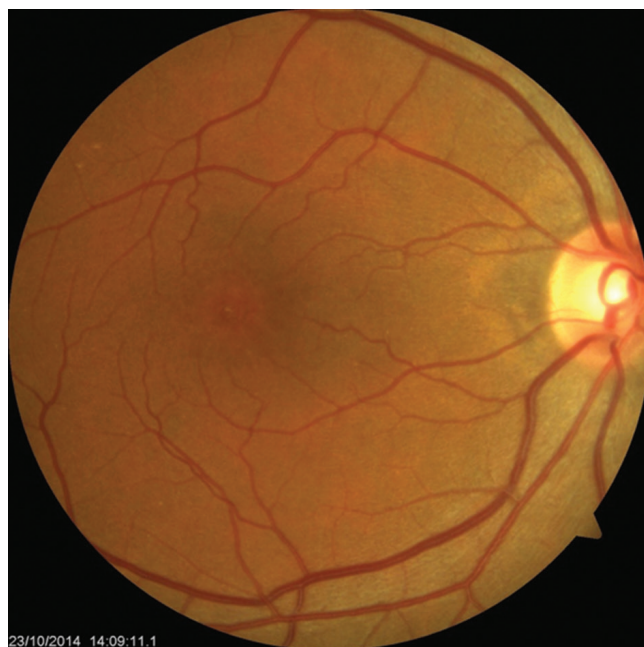

Fig. 1 Preoperative finding of IMH

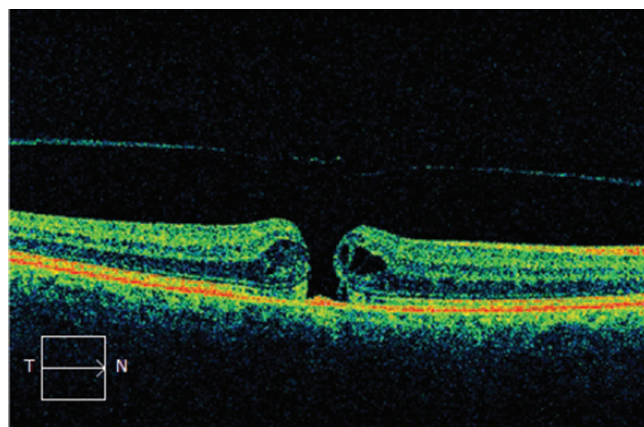


Fig. 2 Finding on OCT before surgery for IMH



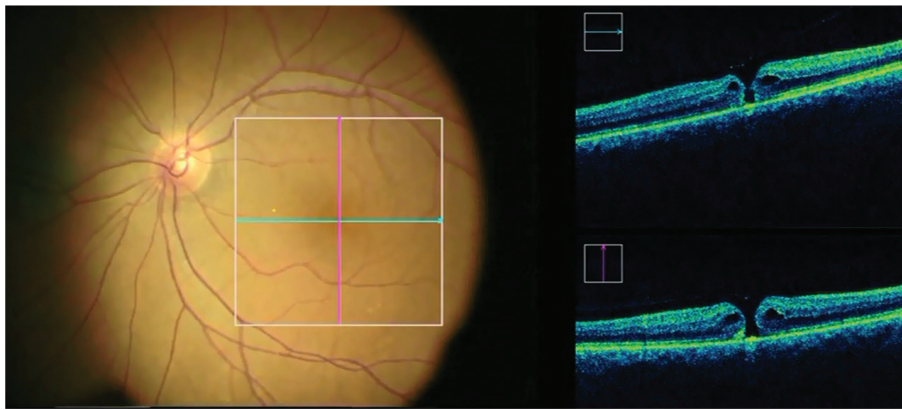


Fig. 3 Intraoperative finding of IMH on OCT

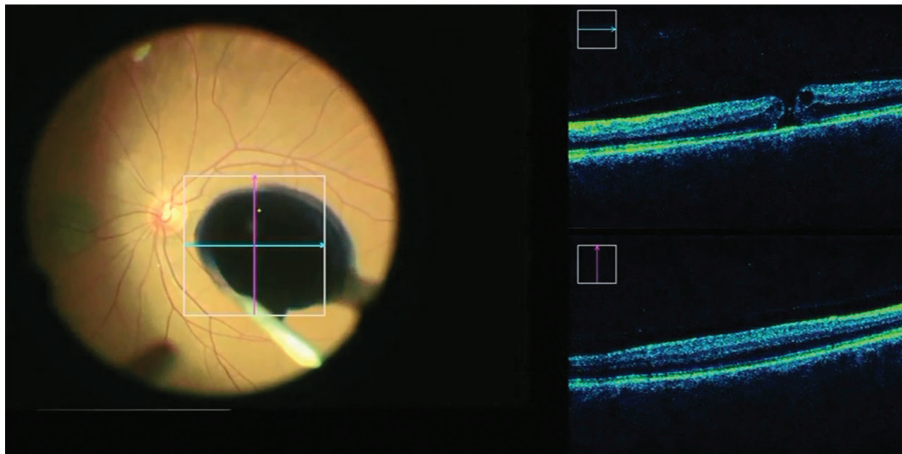


Fig. 4 iOCT enables monitoring of IMH also upon the use of auxiliary colouring and thereby limits the risk of unwanted application of potentially toxic colouring beneath the retina

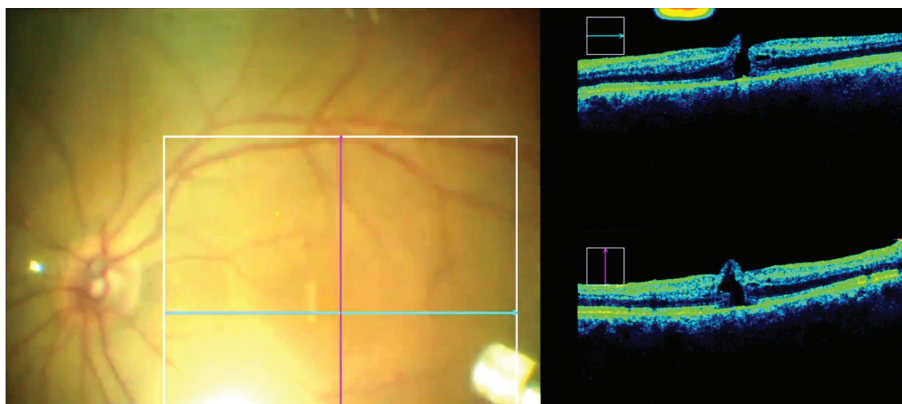


Fig. 5 Intraoperative OCT enables monitoring of the macula also upon exchange for air tamponade, which markedly impairs the view of the ocular fundus

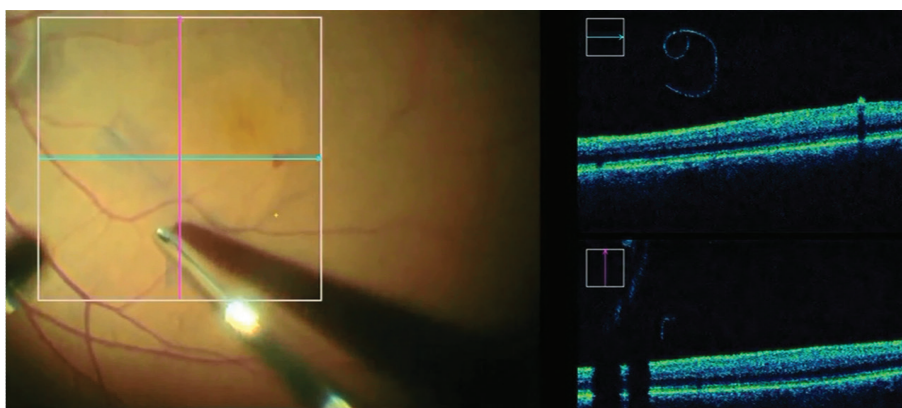


Fig. 6 iOCT visualises the course of ILM peeling

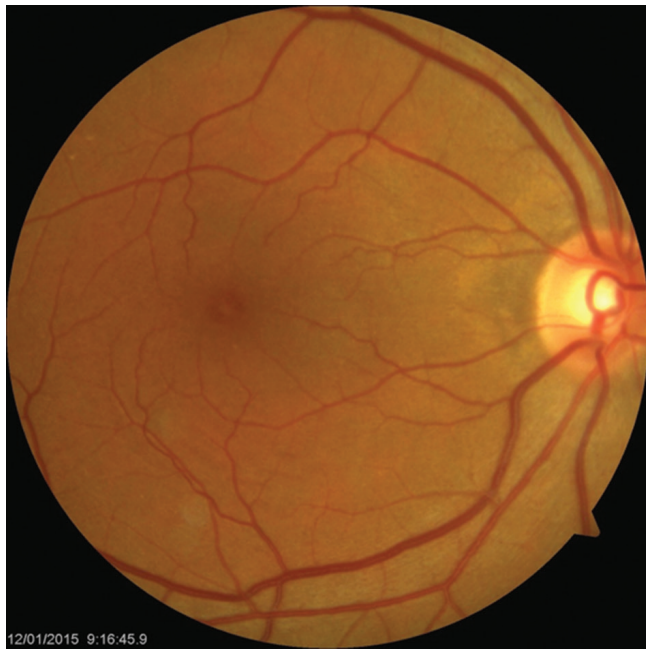

Fig. 7 Postoperative finding of IMH after 3 months

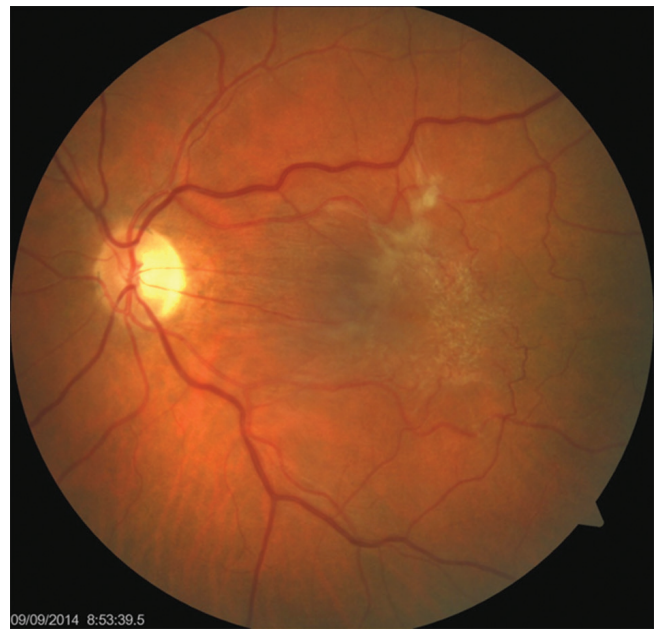

Fig. 9 Preoperative finding of ERM

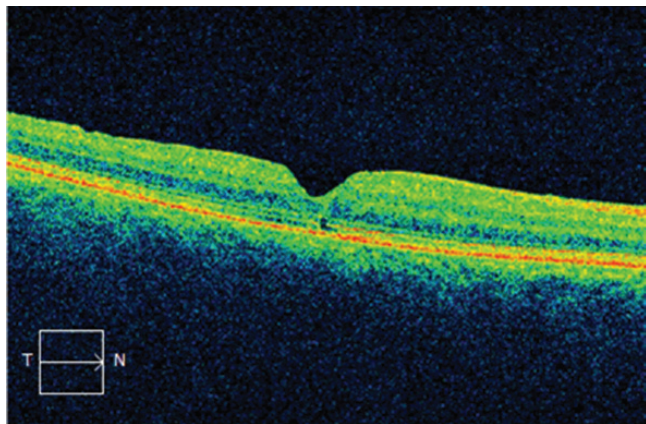


Fig. 8 Finding on OCT 3 months after IMH surgery

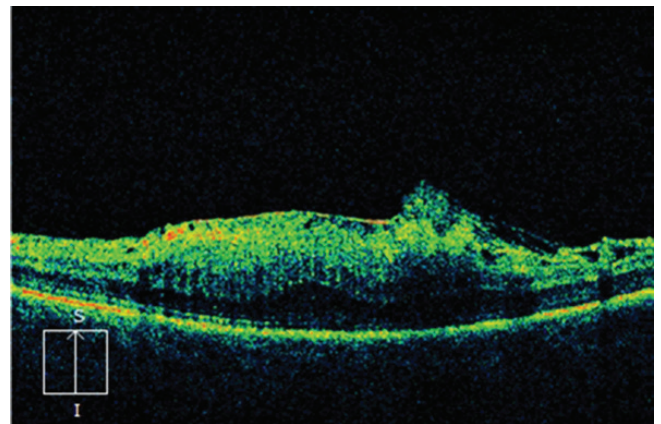


Fig. 10 Preoperative finding of ERM on OCT

the disc of the optic nerve was determined in detail with the aid of iOCT, focusing on the vascular supply of the membrane. Progressive delamination of proliferations was not accompanied by pronounced bleeding from the large vascular stems on the papilla. Minimal bleeding on the disc is illustrated in fig. 16.

Following the absorption of the air tamponade, retinopathy was stable over the long term, and diabetic macular edema did not progress. Hard exudates were absorbed, BCVA was stabilised throughout the entire observation period (15 months) at the value of 20/25 (fig. 17).

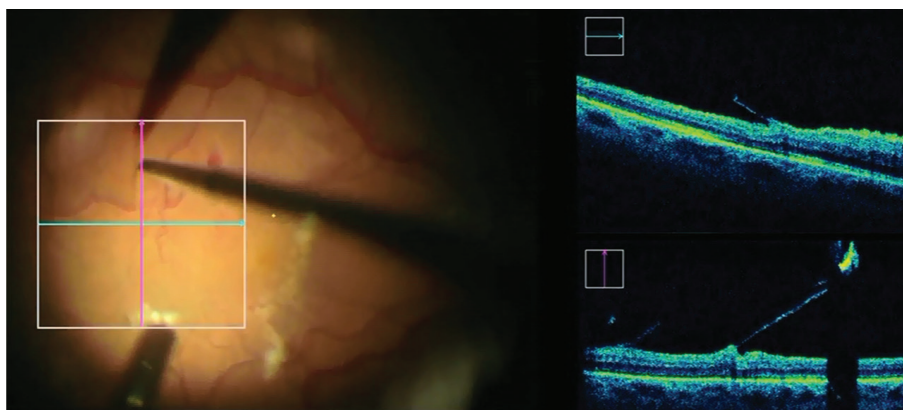


Fig. 11 iOCT at time of ERM peeling. The surgeon directly observes the traction forces, inducing them by microforceps and limiting the risk of occurrence of a central defect of the neuroretina upon strong adherence of the membrane.



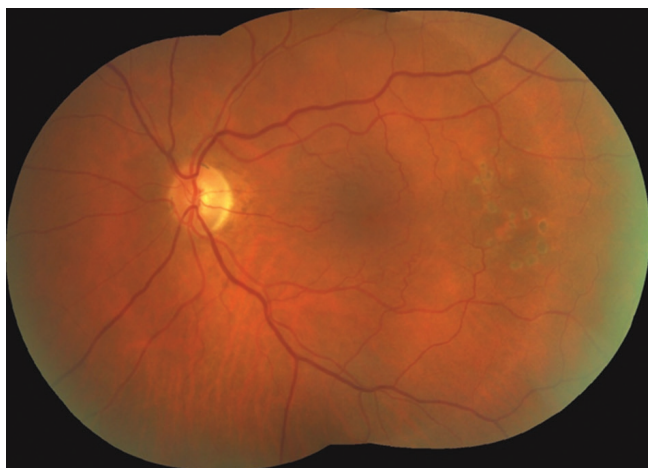

Fig. 12 Macular finding 3 months after surgery

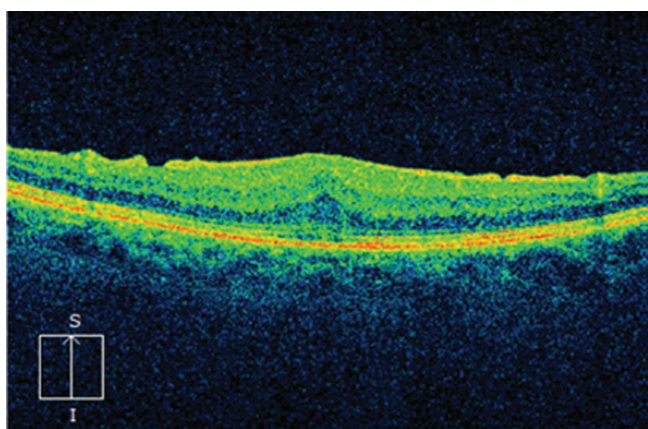


Fig. 13 Macular finding on OCT 3 months after surgery: regression of edema, adjustment of linearity of retinal layers

## DISCUSSION

All surgical procedures with the use of iOCT were conducted without any perioperative or postoperative complications. In all cases full anatomical success was achieved. In two out of three cases BCVA was substantially improved, and in the last case good initial BCVA was stabilised.

The use of iOCT did not jeopardise the safe performance

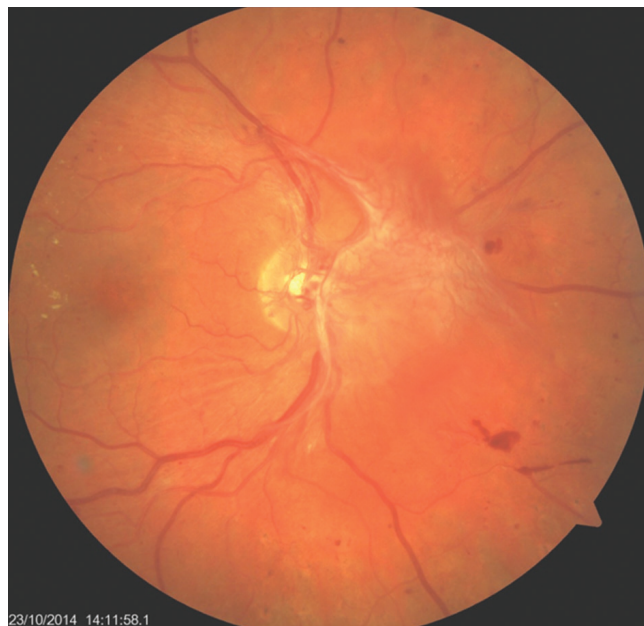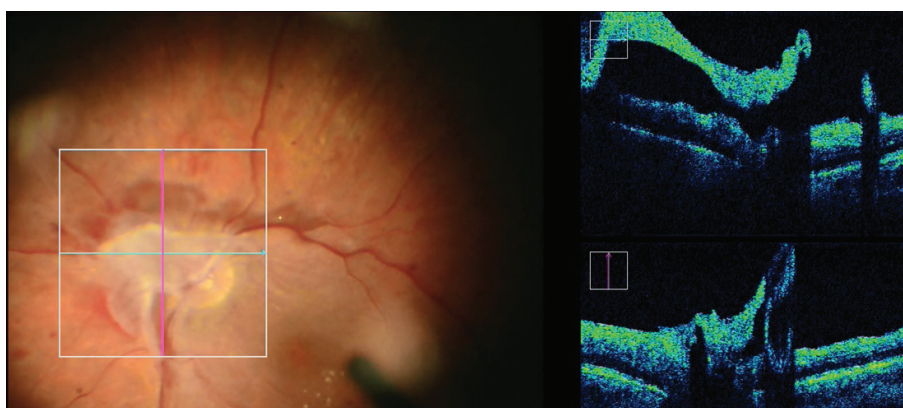


Fig. 14 Retinal finding in the region of the posterior pole before surgical procedure: papillo-vitreal and retino-vitreal proliferations, limited filling of retinal channel, incipient hard exudation in macula

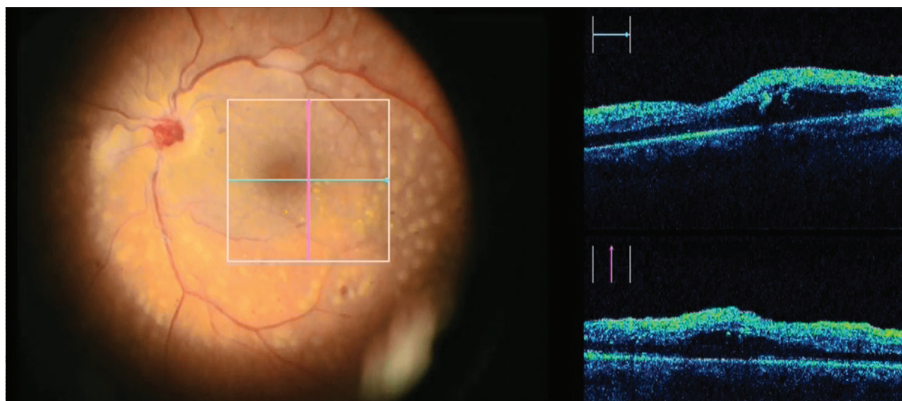
of the procedure or the sterility of the operating field. On the contrary, display by iOCT was possible even under impaired optical conditions such as incipient cataract, use of auxiliary colouring and exchange of water/air. This contrasts with routine OCT examination using a standard instrument, which is rendered practically impossible by the use of air or gas tamponade. The quality of the iOCT display was very good.

This series of case reports confirms the hypothesis that iOCT perfectly displays the micro-anatomy of the operated part of the retina. Display with the aid of iOCT positively influences surgical decision-making in the sense of estimating the current possibilities of work with tissue and reducing the risk of iatrogenic injury by incautious handling. Advances of iOCT are expected in the visualisation of the details of surgery for vitreomacular pathologies, diabetic retinopathy and rhegmatogenous retinal detachment [9].

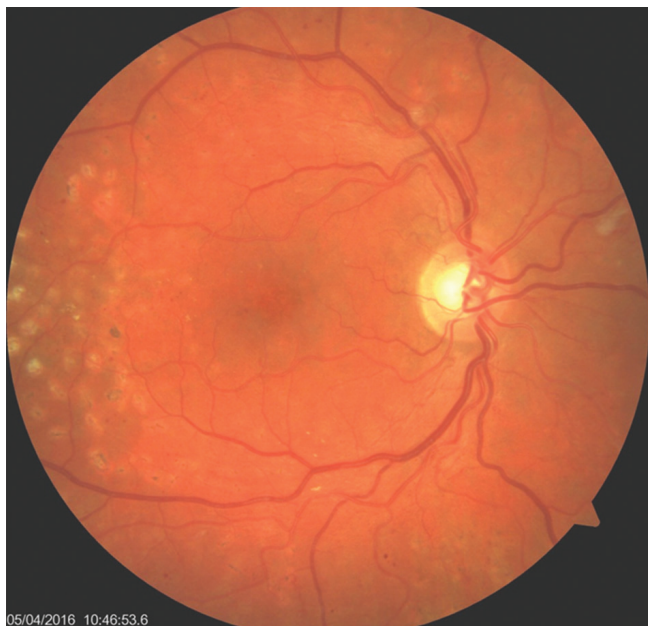In accordance with the study [10], we verified the contribution of iOCT to surgery of IMH. Perioperative assessment of the size of the defect, the relationship of photorecep-



Obr. 15 iOCT upřesňuje anatomické uspořádání proliferace při terči zrakového nervu



Obr. 16 iOCT makulární krajiny (extrafoveální diabetický makulární edém) na konci operace



Obr. 17 Nález klidné diabetické retinopatie se vstřebanými exsudaty za 15 měsíců po operaci

tors and retinal pigment epithelium and the tendency of IMH to close at the end of the operation are criteria for the decision of the surgeon concerning the type of intraocular tamponade and the necessity of postoperative positioning. Perioperative iOCT thus increases the success of primary closure of the defect [10].

Similar use in perioperative decision-making is provided by iOCT in the surgery of idiopathic ERM. The surgeon can observe the condition of the neuroretina during the separation of the adhering membrane, and thereby avert the potential occurrence of a central defect in the macula. At the same time, iOCT displays whether the performed treatment is complete or whether it is necessary to supplement the peeling (in the case of the presence of a residual membrane), or to extend it. These findings are not displayed by a regular surgical microscope [10].

The use of iOCT in proliferative retinopathies facilitates the easy identification of the operated layers, displays their potential vascular supply and highlights possible fine cracks in the neuroretina.

However, intraoperative use of integrated iOCT in a microscope also has limits of its use. This especially concerns a limitation of display upon the use of intraocular instruments which are metallic and reflect, or are impermeable by the light ray of the iOCT instrument. For these reasons, scattering and shadowing of the image may occur.

## CONCLUSION

The use of iOCT provides the surgeon with simultaneous control, both upon performing surgical manipulation in close contact with the retina and upon visualisation of details of the finding on the ocular fundus. The result is an excellent perioperative overview, up-to-date information for the surgeon, higher precision and therefore the preconditions for better postoperative results.

## LITERATURE

1. **Chen, TC., Cense, B., Pierce, MC. et al.:** Spectral domain optical coherence tomography: ultra-high speed, ultra-high resolution ophthalmic imaging. *Arch Ophthalmol*, 123(12); 2005: 1715–20.
2. **Ehlers, JP., Tao, YK., Farsiu, S. et al.:** Integration of a spectral domain optical coherence tomography system into a surgical microscope for intraoperative imaging. *Invest Ophthalmol Vis Sci*, 52(6); 2011: 3153–9.
3. **Ehlers, JP., Dupla, WJ., Kaiser, PK. et al.:** The Prospective Intraoperative and Perioperative Ophthalmic Imaging with Optical Coherence Tomography (PIONEER) Study: 2-year results. *Am J Ophthalmol*, 158(5); 2014: 999–1007.
4. **Ehlers, JP., Goshe, J., Dupla, WJ. et al.:** Determination of feasibility and utility of microscope-integrated optical coherence tomography during ophthalmic surgery: the DISCOVER Study RESCAN Results. *JAMA Ophthalmol*, 133(10); 2015: 1124–32.
5. **Ehlers, JP., Xu, D., Kaiser, PK. et al.:** Intraoperative dynamics of macular hole surgery: an assessment of surgery-induced ultrastructural alterations with intraoperative optical coherence tomography. *Retina*, 34(2); 2014: 213–21.
6. **De Benito-Llopis, L., Mehta, JS., Angunawela, RI. et al.:** Intraoperative anterior segment optical coherence tomography: a novel assessment tool during deep anterior lamellar keratoplasty. *Am J Ophthalmol*, 157(2); 2014:

- 334–341.
7. **Heindl, LM., Siebelmann, S., Dietlein, T. et al.:** Future prospects: assessment of intraoperative optical coherence tomography in ab interno glaucoma surgery. *Curr Eye Res*, 40(12); 2015: 1288–91.
8. **Toygar, O., Riemann, CD.:** Intraoperative optical coherence tomography in macula involving rhegmatogenous retinal detachment repair with pars plana vitrectomy and perfluoron. *Eye (Lond)*, 30(1); 2016: 23–30.
9. **Ray, R., Barañano, DE., Fortun, JA. et al.:** Intraoperative microscope-mounted spectral domain optical coherence tomography for evaluation of retinal anatomy during macular surgery. *Ophthalmology*, 118(11); 2011: 2212–7.
10. **Ehlers, JP.:** Intraoperative optical coherence tomography: past, present, and future. *Eye*, 30; 2016: 193–201.