

HYBRID MONOVISION

^{1,2}Studený P., ²Kacarovský M,
²Kacarovská J., ²Gajarová N., ^{1,2}Straňák Z.

¹Department of Ophthalmology,
Královské Vinohrady University Hospital
and 3rd Faculty of Medicine, Charles
University Prague
Head: prof. Dr. Pavel Kuchynka, CSc.,FCMA

²Eye Clinic SOMICH, Karlovy Vary
Head physician: Dr. Pavel Studený, Ph.D.,
MHA

*The authors of the study declare that
no conflict of interest exists in the
compilation, theme and subsequent
publication of this professional
communication, and that it is not
supported by any pharmaceuticals
company.*



MUDr. Pavel, Studený, Ph.D.
Oční klinika FNKV
Šrobárova 50
100 34 Praha 10 - Vinohrady
e-mail: studenypavel@seznam.cz

SUMMARY

Aim: To evaluate our own results of the use of hybrid monovision technique, in patients after bilateral cataract surgery, where in the dominant eye the monofocal intraocular lens is implanted and in the non-dominant eye the multifocal intraocular lens (IOL) is implanted.

Material and methods: Prospective follow-up of group of 33 patients with bilateral cataract surgery and induced hybrid monovision. In the dominant eye, the hydrophilic monofocal aspheric intraocular lens Auroflex (AuroLab) was implanted, and in the non-dominant eye the hydrophilic multifocal aspheric intraocular lens Seelens (Hanita) was implanted. During the post-operative period, the uncorrected distance visual acuity (UDVA), best-corrected distance visual acuity (CDVA), uncorrected near visual acuity (UNVA), best-corrected near visual acuity (CNVA), and distance-corrected near visual acuity (DCNVA) were established. Further, the monocular contrast sensitivity, subjective satisfaction, and dysfotopsias appearance were examined. The examinations were held 3 and 6 months after the surgery.

Results: In dominant eyes with implanted monofocal lens, UDVA improved from 0.61 ± 0.39 logMAR preoperatively to 0.03 ± 0.14 logMAR at 6 months after the surgery. In non-dominant eyes, with implanted multifocal intraocular lens, UDVA improved from 0.30 ± 0.23 logMAR preoperatively to -0.04 ± 0.06 logMAR. The average binocular UDVA (bUDVA) was -0.07 ± 0.08 logMAR and binocular CDVA (bCDVA) -0.12 ± 0.06 . The average UNVA in dominant eyes 6 months after the surgery was 0.62 ± 0.18 logMAR, in non-dominant eyes 0.18 ± 0.15 logMAR, binocularly 0.15 ± 0.11 logMAR. The contrast sensitivity was in the eyes with implanted multifocal IOL slightly worse comparing to the eyes with implanted monofocal lens, albeit only in the space frequency of 6 cycles per degree (CPD) this difference was statistically significant. Subjectively, the presence of dysfotopsia and other problems were very low, the average values of single answers were from 1.3 to 2.1 (on the scale 1 – 5, 1 – no problems and 5 – severe problems). Also, we noticed high percentage of subjective satisfaction with the surgery results (94 %). Six percent of patients wear glasses for near distance as a standard, 42 % of patients wear them occasionally, and 45 % of patients don't use glasses for near distance at all.

Conclusion: The technique of hybrid monovision is effective, safe, and relatively cheap method solving the loss of accommodation in patients after the cataract surgery. This method extends the spectrum of our possibilities how to solve the loss of accommodation in these patients.

Key words: hybrid monovision, multifocal intraocular lens, contrast sensitivity

Čes. a slov. Oftal., 73, 2017, No. 1, p. 13–16

INTRODUCTION

Finding an optimum solution for loss of accommodation during the course of cataract surgery remains a persistent challenge in ophthalmology. The standard solution with the aid of implantation of a multifocal intraocular lens (MF IOL) brings with it certain complaints such as glare, halo, dysphotopsia, reduced contrast sensitivity (10), in certain cases slightly deteriorated distance visual acuity, high sensitivity to postoperative residual defects and also a higher price of implants. The use of accommodating lenses is currently less frequent, due to their limited effect on near vision (1). Another used method is the technique of monovision, which may lead to certain subjective discomfort with regard to the different postoperative refraction of both eyes, in addition to which near vision as a rule is not entirely satisfactory. The technique of hybrid monovision, introduced into the professional literature by Iida et al. in 2011, theoretically removes certain disadvantages of the aforementioned procedures (7). In this case a monofocal lens is implanted into the dominant eye and a multifocal lens into the non-dominant eye.

The monofocal lens theoretically ensures excellent distance vision, with a minimal incidence of dysphotopsia, whilst the multifocal lens then provides the patient with relatively good near vision. With regard to the fact that both eyes have the same refraction to distance, the risk of subjective complaints ensuing from anisometropia, as in the case of the monovision technique, is minimised. A further advantage is the low cost. Nevertheless, to date this technique is not very widespread. The aim of our study was to evaluate our own results from the use of the technique of hybrid monovision, above all with regard to visual acuity for distance and near vision, contrast sensitivity and subjective patient satisfaction.

METHODOLOGY

This concerned a non-randomised, prospective observation of a consecutive cohort of patients. The cohort comprised 33 patients with bilateral cataract, in whom the performance of phacoemulsification was followed by the implantation of a hydrophilic multifocal lens of the type Auroflex

(Aurolab) into the dominant eye, and the implantation of a hydrophilic multifocal aspherical intraocular lens of the type Seelens MF (Hanita) into the non-dominant eye, with apodised diffractive optics, creating an addition of + 3.0 D to near vision. In all eyes the operation was supplemented as standard by posterior CCC beneath the implanted intraocular lens for the purpose of preventing a secondary cataract. The exclusion criteria from the cohort were presence of another ocular pathology, corneal astigmatism higher than 0.75 D and any perioperative complications. Surgery on both eyes was performed at an interval of 1-7 days, the operations were performed by a single surgeon (PS). The perioperative and postoperative course was entirely standard in all patients, no complications were recorded in any of the patients. The operations were performed within the period of 10/2014 – 3/2015. For all patients the planned value of postoperative refraction in emmetropia was (+0.25 to -0.25) Dpt. The SRK T formula was used for calculation of the power of the intraocular lens. Dominance of the eye was determined using two methods for determining directional dominance (technique of alternating coverage of the right and left eye while observing an object through a narrow opening, and technique of bringing the opening closer to the dominant eye). In the postoperative period uncorrected distance visual acuity (UDVA) and best corrected distance visual acuity (CDVA) were observed, as well as uncorrected near visual acuity (UNVA), best corrected near visual acuity (CNVA) and distance corrected near visual acuity (DCNVA). All the values were examined both monocularly and binocularly (bUDVA, bCDVA, bUNVA, bCNVA, bDCNVA). In addition, monocular contrast sensitivity under mesopic conditions was examined with the aid of a CSV-1000E test. All the values were examined 3 and 6 months after the performed operation.

The results were statistically processed with the aid of SPSS statistical software, version 15.0 for Windows (SPSS, Inc, IL, US). A Student T-test was used for the statistical evaluation, we considered the level of $p \leq 0.05$ to be statistically significant.

RESULTS

In the dominant eyes with an implanted monofocal lens, average UDVA improved from 0.61 ± 0.39 logMAR preoperatively to 0.05 ± 0.16 logMAR 3 months after surgery and 0.03 ± 0.14 logMAR 6 months after surgery (table 1, graph 1), in which 88 % of patients had UDVA of 0.21 logMAR and better (6/9), 70 % of eyes had UDVA of 0.0 logMAR and better (6/6). In these eyes CDVA preoperatively was 0.28 ± 0.15 logMAR, -0.08 ± 0.07 logMAR at 3 months and -0.06 ± 0.06 logMAR at 6 months after surgery (table 2, graph 2), in which 97 % of eyes had CDVA of 0.0 logMAR and better (6/6) and 70 % of eyes -0.08 logMAR and better (6/5). In comparison with the preoperative values, UDVA and CDVA improved statistically significantly, both 3 months and 6 months after surgery.

In the non-dominant eyes with an implanted multifocal intraocular lens, average UDVA improved from 0.30 ± 0.23

logMAR preoperatively to 0.06 ± 0.15 logMAR and -0.04 ± 0.06 log MAR 3 and 6 months after surgery respectively (table 1, graph 1), in which 97 % of patients had UDVA of 0.21 logMAR and better (6/9), 64 % of eyes had UDVA of 0.0 logMAR and better (6/6). In these eyes CDVA preoperatively was 0.37 ± 0.45 logMAR, -0.05 ± 0.09 logMAR at 3 months and -0.04 ± 0.06 logMAR 6 months after surgery (table 2, graph 2), in which 88 % of eyes had CDVA of 0.0 logMAR and better (6/6) and 48 % of eyes -0.08 logMAR and better (6/5). In comparison with the preoperative values, UDVA and CDVA improved statistically significantly, both 3 months and 6 months after surgery.

Average UDVA and CDVA were practically the same in the eyes with both monofocal and multifocal lenses, and the differences were not statistically significant.

As regards binocular functions, three months after surgery binocular UDVA (bUDVA) was -0.07 ± 0.09 logMAR and binocular CDVA (bCDVA) -0.13 ± 0.06 logMAR. Six months after surgery bUDVA was -0.07 ± 0.08 logMAR, bCDVA -0.12 ± 0.06 (tables 1, 2 and graphs1, 2).

The results of near visual acuity 6 months after surgery are presented in table 3 and graph 3. In the case of the eye with a monofocal lens, UNVA and DCNVA were markedly worse than CNVA. This difference was statistically significant. In the eye with the multifocal lens the differences between UNVA, DCNVA and CNVA were smaller, nevertheless, even in this case, CNVA was statistically significantly better than the average values of UNVA and DCNVA. We recorded a similar result upon testing near visual acuity binocularly.

Another tested quantity was contrast sensitivity. On average this was slightly worse in the eyes with the multifocal lens in comparison with the eyes with an implanted monofocal lens, nevertheless only at a spatial frequency of 6 cycles/degree was this difference statistically significant ($p = 0.01973$), (graph 4).

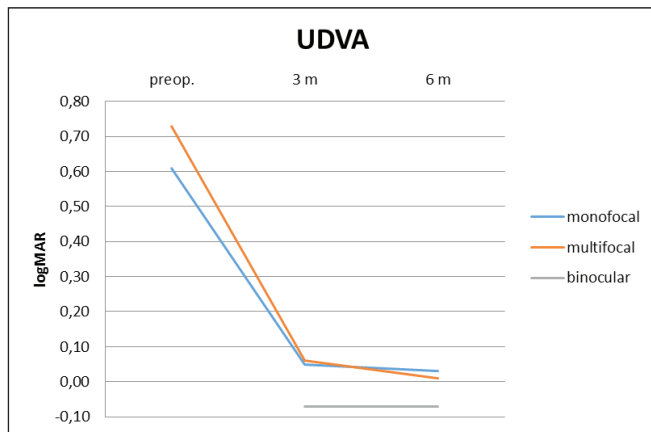
Subjectively the incidence of dysphotopsia and other complaints was very low, the average values in the individual responses were 1.3-2.1 (on a scale of 1-5, 1- no complaints, 5- severely disruptive complains). We also recorded a high percentage of subjective satisfaction with the result of the operation (94%). 2 patients (6 %) always use glasses

Table 1. Average monocular UDVA (logMAR)

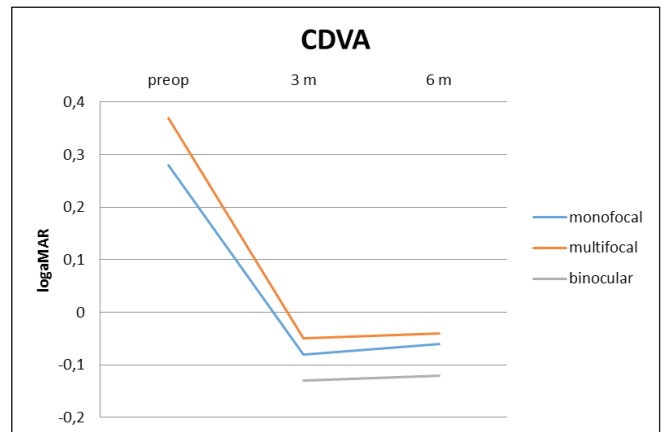
UDVA	preop.	3 m	6 m
monofocal	$0,61 \pm 0,39$	$0,05 \pm 0,16$	$0,03 \pm 0,14$
multifocal	$0,73 \pm 0,51$	$0,06 \pm 0,15$	$0,01 \pm 0,10$
binocular		$-0,07 \pm 0,09$	$-0,07 \pm 0,08$

Table 2 Average monocular CDVA (logMAR)

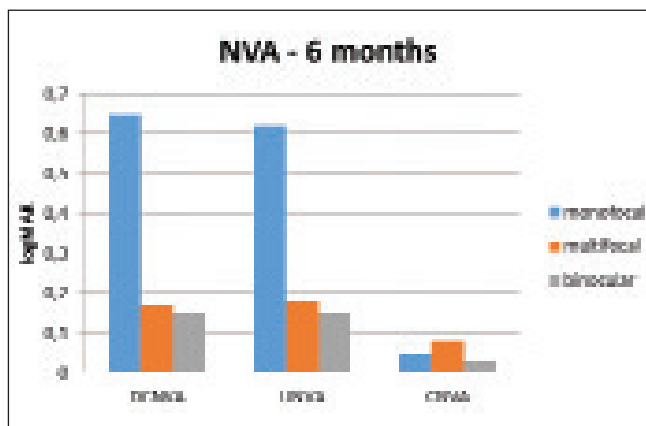
CDVA	preop	3 m	6 m
monofocal	0.28 ± 0.15	-0.08 ± 0.07	-0.06 ± 0.06
multifocal	0.37 ± 0.45	-0.05 ± 0.09	-0.04 ± 0.06
binocular		-0.13 ± 0.06	-0.12 ± 0.06



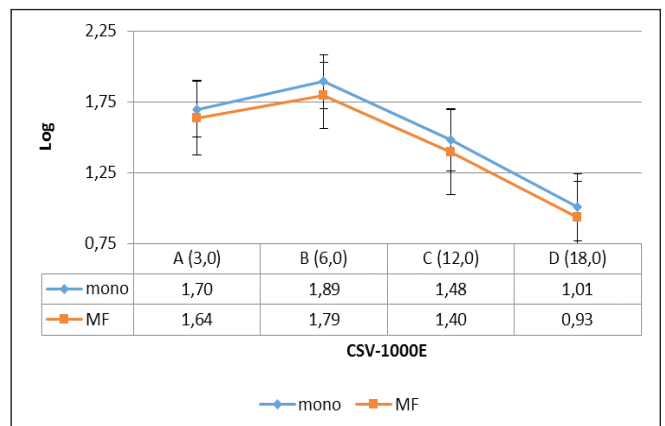
Graph 1. Average monocular UDVA (logMAR)



Graph 2. Average monocular CDVA (logMAR)



Graph 3. Average near visual acuity (logMAR) 6 months after surgery



Graph 4. Contrast sensitivity 6 months after surgery

for close up work, 14 patients (42%) occasionally, 2 patients (6%) only at a computer and 15 patients (45%) do not use glasses for close up work.

DISCUSSION

The technology for producing MF IOL is constantly improving, and the current models of lenses offer very good binocular visual acuity for both distance and near vision. Cochener et al. in their meta-analysis of studies describing the results of implantation of a MF IOL state a median value of UDVA at 0.093 logMAR, median UNVA reached 0.141 logMAR (6). This fully correlates with the results in our cohort of patients, in which UDVA in the non-dominant eyes with an implanted MF IOL 6 months after surgery was -0.04 ± 0.06 log MAR and UNVA 6 months after surgery 0.18 ± 0.15 . In the eyes with a monofocal IOL in our cohort the average value of UDVA was 0.03 ± 0.14 logMAR and the value of UNVA 0.62 ± 0.18 logMAR. Whilst distance visual acuity was therefore entirely comparable for both types of lenses (both MF and monofocal), near visual acuity (according to expectation) was statistically significantly better in the eyes with a MF IOL.

In the published studies, postoperative independence of

glasses in patients with a bilaterally implanted MF IOL fluctuates within the range of 30% - 100% (10). In our cohort of patients with hybrid monovision, 45% of patients were entirely independent of glasses, 49% of patients were partially independent and used glasses correction for near vision (or middle distance vision) occasionally. Average binocular uncorrected near visual acuity was 0.15 ± 0.11 logMAR.

Nevertheless, the evaluation of good results of visual acuity in patients with an implanted MF IOL alone does not entirely attest to the resulting effectiveness of these lenses. The benefit of near vision is often gained at the expense of a deterioration of other optical qualities. Sometimes the adverse side effects of an MF IOL may even be the reason for explantation (8,11,14). These complaints may theoretically be alleviated precisely by a combination of a monofocal and multifocal lens.

In our cohort of patients, a comparison of contrast sensitivity of both types of lenses demonstrated a slightly worse result in the eyes with an implanted MF IOL, nevertheless only in a single parameter (spatial frequency of 6 cycles/degree) was this difference statistically significant. Similar results are described also in studies by other authors, comparing the effect of multifocal and monofocal lenses on contrast sensitivity (3,12), whereas in other published studies

this difference was not found (2).

In addition to reduced contrast sensitivity, of the other adverse secondary visual phenomena the most frequently described are halo and glare. The percentage incidence of severe complaints is stated within the range of 0-10% (10), whilst the meta-analysis conducted by Calladine states the incidence of the phenomenon of halo/glare as high as in 48.5% of patients (3). This variability is due primarily to the different methodology of determining these phenomena in the individual studies, as well as due to the various optical designs of the individual lenses (10). In response to a targeted question, in our cohort of patients 21.2% stated a mild to medium halo effect or glare (score 2-3 out of total 1-5).

In various studies subjective patient satisfaction following the implantation of multifocal lenses is stated at more than 80% (4,5,9,13). In our cohort of patients only 2 patients chose another type of implanted intraocular lens. Overall satisfaction was therefore 94%.

CONCLUSION

The technique of hybrid monovision is an effective, safe and relatively cheap method for resolving loss of accommodation in patients following cataract surgery. This method extends our spectrum of possible solutions for loss of accommodation in these patients.

LITERATURE

1. Alió JL, Pinero DP, Plaza-Pucha AB.: Visual outcomes and optical performance with a monofocal intraocular lens and new-generation single-optic accommodation intraocular lens. *J Cataract Refract Surg*, 2010; 36: 1656–1664.
2. Alió, JL., Piñero, DP., Plaza-Puche, AB. et al.: Visual outcomes and optical performance of a monofocal intraocular lens and a new-generation multifocal intraocular lens. *J Cataract Refract Surg*, 37; 2011: 241–50.
3. Calladine, D., Evans, JR., Shah, S. et al.: Multifocal versus monofocal intraocular lenses after cataract extraction. *Cochrane Databas Sys Rev*, 2012; 9: CD003169.
4. Can, I., Bostanci Ceran, B., Soyugelen, G. et al.: Comparison of clinical outcomes with 2 small-incision diffractive multifocal intraocular lenses. *J Cataract Refract Surg*, 38; 2012: 60–67.
5. Chang, JSM., Ng, JCM., Lau, SYF.: Visual outcomes and patient satisfaction after presbyopic lens exchange with a diffractive multifocal intraocular lens. *J Refract Surg*, 28; 2012: 468–474.
6. Cochener B, Lafuma A, Khoshnood B., Courouve L, Berdeaux G.: Comparison of outcomes with multifocal intraocular lenses: a meta-analysis. *Clin Ophthalmol*, 2011; 5: 45–56.
7. Iida, Y., Shimizu, K., Ito, M.: Pseudophakic monovision using monofocal and multifocal intraocular lenses: hybrid monovision. *J Cataract Refract Surg*; 37; 2011: 2001–5.
8. Kamiya, K., Hayashi, K., Shimizu, K. et al.: Multifocal intraocular lens explanation: a case series of 50 eyes. *Am J Ophthalmol*, 158; 2014: 215–220.
9. Mester, U., Vaterrodt, T., Goes, F. et al.: Impact of personality characteristics on patient satisfaction after multifocal intraocular lens implantation: results from the „happy patient study“. *J Refract Surg*, 30; 2014: 674–678.
10. Rosen, E., Alió, JL., Dick, HB. et al.: Efficacy and safety of multifocal intraocular lenses following cataract and refractive lens exchange: Metaanalysis of peer-reviewed publications. *J Cataract Refract Surg*, 42; 2016: 310–328.
11. Veselá, M., Baráková, D., Lenčová, A.: Analýza příčin explantace nitroočních čoček. *Čes a Slov Oftal*, 69; 2013: 170–173.
12. Vingolo, EM., Grenga, P., Iacobelli, L. et al.: Visual acuity and contrast sensitivity: AcrySof ReSTOR apodized diffractive versus AcrySof SA60AT monofocal intraocular lenses. *J Cataract Refract Surg*, 33; 2007: 1244–7.
13. Visser, N., Nuijts, RMMA., de Vries, NE. et al.: Visual outcomes and patient satisfaction after cataract surgery with toric multifocal intraocular lens implantation. *J Cataract Refract Surg*, 37; 2011: 2034–2042.
14. Woodward, MA., Randleman, JB., Stulting, RD.: Dissatisfaction after multifocal intraocular lens implantation. *J Cataract Refract Surg*, 35; 2009: 992–7.
15. Ye, PP., Li, X., Yao, K.: Visual outcome and optical quality after bilateral implantation of aspheric diffractive multifocal, aspheric monofocal and spherical monofocal intraocular lenses: a prospective comparison. *Int J Ophthalmol*, 6; 2013: 300–6.