

# PUNCTATE INNER CHOROIDOPATHY

## SUMMARY

### PUNCTATE INNER CHOROIDOPATHY

Punctate Inner Choroidopathy (PIC) is a rare idiopathic ocular inflammatory disease. It occurs mostly in young, myopic, otherwise healthy women. Symptoms of the disease include acute vision decrease associated with central and paracentral scotoma. In 80% of cases PIC occur bilaterally. We report the case of a woman at the age of twenty-five, who was treated for PIC. Due to the finding of active inflammatory deposit in the retina of the left eye and low visual acuity was recommended corticosteroid therapy with a good therapeutic effect.

**Key words:** Punctate Inner Choroidopathy (PIC), white dot syndromes

*Čes. a slov. Oftal., 72, 2016, No. 2, p. 44–47*

Stepanov A., Studnička J., Hejsek L.,  
Dusová J., Jirásková N.

Department of Ophthalmology, University  
Hospital Hradec Králové, Chief prof.  
MUDr. Naďa Jirásková, Ph.D., FEBO

*This study was supported by the research  
project PRVOUK: P37/07*

*The authors of the study declare that no  
conflict of interest exists in the compilation,  
theme and subsequent publication of this  
professional communication, and that it is not  
supported by any pharmaceuticals company.*



MUDr. Alexandr Stepanov, FEBO  
Oční klinika - Fakultní nemocnice  
Sokolská 581, 500 05 Hradec Králové  
e-mail: stepanov.doctor@gmail.com

## INTRODUCTION

Punctate inner choroidopathy (PIC) is a rare disease, which most commonly afflicts young, myopic women with an average age of 30 (age range 15 to 55 years). Gerstenblith et al. state in their study that 85% of the afflicted women have myopia with a median value of -7.00 D in each eye (range -1.25 to -12.75 D), and only 1% have hypermetropia (1). This pathology belongs to the heterogeneous group of pathologies known as white dot syndrome, first described by Watzke in 1984 (2). Subjective symptoms include photopsia and deterioration of acute vision associated with central and paracentral scotomas. In 80% of cases PIC occurs bilaterally. The etiopathogenesis of the pathology remains unclear. No clear correlation has been found between PIC and consumption of coffee, alcohol, cigarette smoking, sexual orientation or viral exposure (3). In the majority of cases visual acuity returns to values of 20/40 or better, nevertheless approximately 20% of patients are left with severe affliction of vision and visual acuity worse than 20/200 (2, 4, 5). The main complication is generally choroidal neovascularisation (CNV) (69%) and subsequent development of subretinal fibrosis (56%). (1).

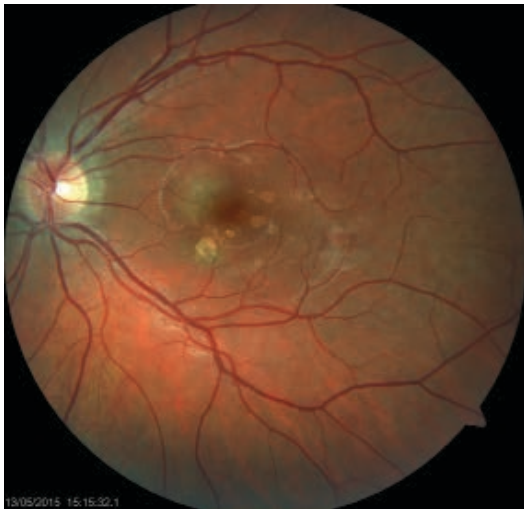## CASE REPORT

A woman aged 25 years was examined at the Department of Ophthalmology at the University Hospital in Hradec Králové due to deterioration of vision in the left eye. Generally she was being treated for hirsutism, and regularly used DIAN-35 (Ethinyl estradiol 0.035 mg and Cyproterone acetate 2.00 mg). Her previous ocular anam-

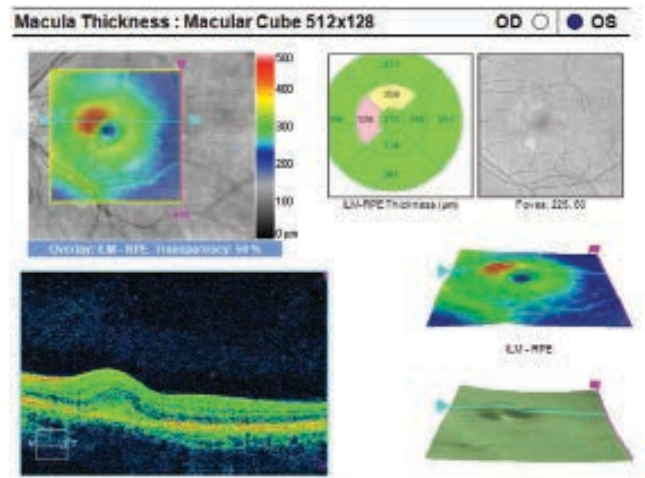
nesis was without remarkable features.

The patient had suffered ocular complaints for 3 days, had perceived flashes and a black stain in the centre of the visual field of the left eye. Initial visual acuity in the left eye was 6/15, and was not improved by correction. Visual acuity in the right eye was 6/6 with correction sph -0.75D. In both eyes the finding in the anterior segment was commensurate to age. On the ocular fundus of the left eye the disc of the optic nerve was bordered, in the area of the macula there were a number of cream-coloured deposits, some of them with pigment clusters, active inflammatory deposit nasally from the foveola (fig. 1). In the right eye the finding on the ocular fundus was commensurate to age. Optical coherence tomography (OCT) (Zeiss Cirrus) of the central region of the left eye demonstrated a created foveolar depression, edema of the neuroretina nasally on the fovea with cumulation of hyperreflectivities on the level of the retinal pigment epithelium (RPE), around the centre were small deposits of window defects of the RPE (fig. 2). At the beginning of the first minute of fluorescence angiography (FAG) we observed grading hyperfluorescence in the location of the acute deposit (fig. 3, 4). The post-inflammatory deposits were of the character of non-grading hyperfluorescence "window" defects of the RPE.

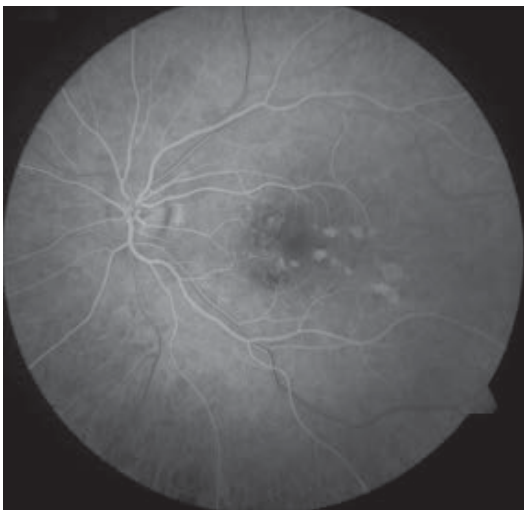On the basis of the objective finding and the patient's anamnesis, a diagnosis of PIC in the left eye was determined. Basic blood samples were taken, targeted rheumatological samples and also antibodies against: *Toxoplasma gondii*, *Toxocara canis*, *Varicella zoster*, *Herpes simplex*, *Cytomegalovirus*, *Borrelia burgdorferi* and *Chlamydia trachomatis* (in order to exclude



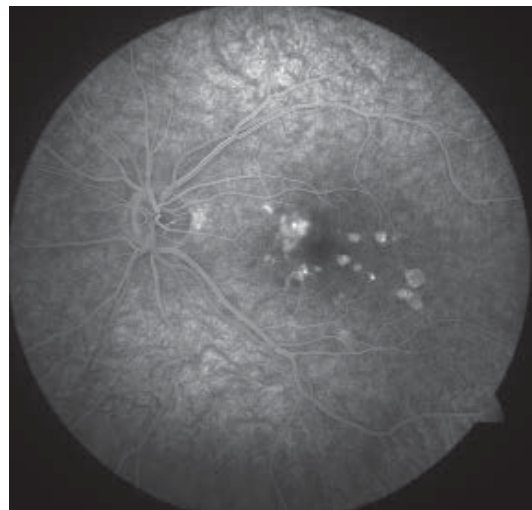
**Fig. 1** Left eye. Finding of acute inflammatory deposit in central region of retina



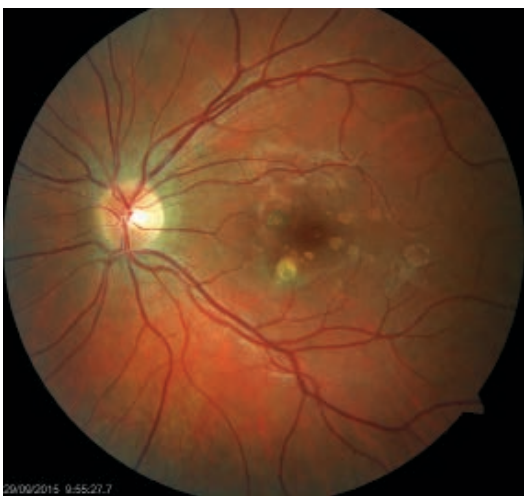**Fig. 2** OCT of central region of left eye. Hyperreflective inflammatory deposit on level of RPE, edema of neuroretina



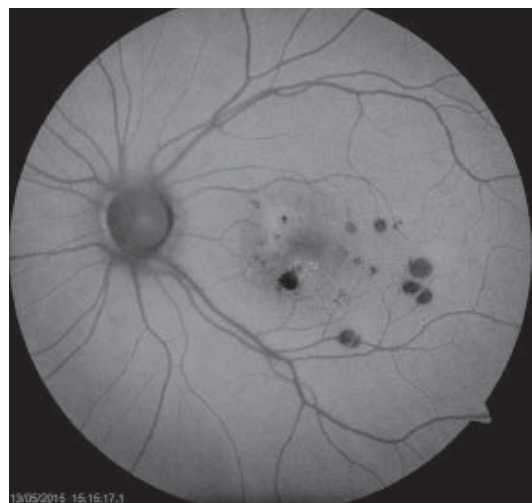**Fig. 3** FAG of left eye. Hyperfluorescence of window defects of RPE in place of inactive inflammatory lesions



**Fig. 4** FAG of left eye. Grading hyperfluorescence in place of acute deposit nasally from foveola



**Fig. 5** Left eye. Original active deposit on retina progressively bordering and partially pigmented



**Fig. 6** Auto-fluorescence photograph of ocular fundus of left eye. Deposit of atrophy of RPE

**Table 1** Differential diagnostics of punctate inner choroidopathy

Pathology	Clinical characteristics
Ocular histoplasmosis	Patient resides in endemic region; peripapillary atrophy; pacific vitreous; non-pigmented atrophic stains with pigment clusters
Tuberculosis	Positive anamnesis; positive tuberculosis test; minimal to no inflammatory reaction in vitreous area; good response to anti-TB therapy
Sarcoidosis	ACE and lysozyme may be raised; characteristic finding on X-ray of chest. Granulomas with periphlebitis on ocular fundus
Syphilis	Positive PTA-ABS or MHA-TP. From the beginning cream-coloured confluent lesions, which progressively pass into hyperplasia of RPE. Occurrence of scars; good response to specific therapy
Lymphoma	Anamnesis of affliction of CNS; dense vitritis; subretinal and intraretinal infiltrates, haemorrhage
Ocular pneumocystis	Anamnesis of HIV or other immunosuppressive conditions; small to large cream-coloured bordered lesions on level of choroidea; RPE changes are rare; good response to specific therapy
Sympathetic ophthalmia	Anamnesis of previous trauma; acute or chronic anterior uveitis; papillitis; Dalen-Fuchs deposits

accompanying infections) – values were within the norm. With regard to the finding of an acute deposit and deteriorated visual acuity, corticosteroid therapy was recommended – peroral administration of Prednisone 40 mg/day with progressive reduction of the dose over a period of 14 days. The applied therapy brought a subjective and objective improvement of the finding in both eyes. Visual acuity in the left eye improved to 6/6. 14 days after the commencement of treatment the originally active deposit on the ocular fundus progressively became bordered and partially pigmented (fig. 5). On an auto-fluorescence image of the retina of the left eye there were evident deposits of atrophy of the RPE in the affected regions (fig. 6). Regular follow-up examinations at three-monthly intervals were recommended for the patient for the purpose of potential timely identification of CNV.

## DISCUSSION

A typical finding of PIC on the ocular fundus is multiple, cream-coloured deposits in the region of the macula with a size of approximately 100-300 µm, which are localised on the level of the RPE/inner choroidea. The acute deposits progressively become bordered and pigment shifts appear with atrophy of the RPE in the centre of the lesion (6). In our case we recorded both an acute deposit and pacific post-inflammatory atrophic deposits in the region of the macula.

During the course of the first 6 months CNV develops in 25% to 40% of eyes, and it is necessary to commence therapy with anti-VEGF preparations (4, 7). In our case we have not yet recorded signs of CNV, but we are regularly monitoring the patient for the purpose of potential detection of a neovascular membrane.

The etiopathogenesis of the disease remains unclear. Autoimmune disorders occur relatively frequently in

the population of young women, such as systemic lupus erythematosus, scleroderma, rheumatoid arthritis and autoimmune thyroiditis. With regard to the connection between this pathology and HLA-A29 positivity, it is possible to presuppose that a genetic and autoimmune predisposition exists (8). In addition to this, there is an opinion that a large role in the pathogenesis is played by the main histocompatibility complex (9). In our case we recorded a rapid regression of the activity of the pathology following the commencement of immunosuppressive therapy with Prednisone, which supports the theory of autoimmune predisposition to PIC.

Because acute lesion of PIC spontaneously improves in the majority of cases, its treatment is sometimes controversial (7, 10, 11). Nevertheless, peroral steroids accelerate the improvement of visual acuity. In our case, with regard to the finding of an active deposit on the ocular fundus of the left eye with a deterioration of visual acuity, general corticosteroid therapy was recommended, with a good therapeutic effect.

Punctate inner choroidopathy belongs to the group of white dot syndromes, whose clinical findings we compared with the finding in our patient within the framework of differential diagnostics – see table 2 from our previous article – patient with APMPPE (12). Here we present differential diagnostics with other conditions.

## CONCLUSION

Punctate inner choroidopathy is acquired inflammatory disease which belongs to the group of white dot syndrome. In our case, on the basis of the clinical picture we diagnosed a less common form of the pathology afflicting one eye. Following the applied immunosuppressive therapy there was a regression of the inflammatory reaction on the ocular fundus and an improvement of visual acuity.

## LITERATURE

1. **Gerstenblith, AT., Thorne, JE., Sobrin, L. et al.:** Punctate inner choroidopathy: a survey analysis of 77 persons. *Ophthalmology*, 114(6); 2007: 1201–4.
2. **Watzke, RC., Packer, AJ., Folk, JC. et al.:** Punctate inner choroidopathy. *Am J Ophthalmol*, 98(5); 1984: 572–84.
3. **Amer, R., Lois, N.:** Punctate inner choroidopathy. *Surv Ophthalmol*, 56(1); 2011: 36–53. oLÁH
4. **Brown, J.Jr., Folk, JC., Reddy, CV. et al.:** Visual prognosis of multifocal choroiditis, punctate inner choroidopathy, and the diffuse subretinal fibrosis syndrome. *Ophthalmology*, 103 (7); 1996: 1100–5.
5. **Reddy, CV., Brown, J., Folk, JC. et al.:** Enlarged blind spots in chorioretinal inflammatory disorders. *Ophthalmology*, 103(4); 1996: 606–17.
6. **Hua, R., Liu, L., Chen, L.:** Evaluation of the progression rate of atrophy lesions in punctate inner choroidopathy (PIC) based on autofluorescence analysis. *Photodiagnosis Photodyn Ther*, 11(4); 2014: 565–9.
7. **Flaxel, CJ., Owens, SL., Mulholland, B. et al.:** The use of corticosteroids for choroidal neovascularization in young patients. *Eye*, 12(2); 1998: 266–72.
8. **Baarsma, GS., Priem, HA., Kijlstra, A.:** Association of bird-shot retinochoroidopathy and HLA-A29 antigen. *Curr Eye Res*, 9(Suppl.); 1990: 63–8.
9. **Becker, KG.:** The common genetic hypothesis of autoimmune/ inflammatory disease. *Curr Opin Allergy Clin Immunol*, 1(5); 2001: 399–405.
10. **Levy, J., Shneck, M., Klemperer, I. et al.:** Punctate inner choroidopathy: resolution after oral steroid treatment and review of the literature. *Can J Ophthalmol*, 40(5); 2005: 605–8.
11. **Brueggeman, RM., Noffke, AS., Jampol, LM.:** Resolution of punctate inner choroidopathy lesions with oral prednisone therapy. *Arch Ophthalmol*, 120(7); 2002: 996.
12. **Stepanov, A., Feuermannová, A., Studnička, J. et al.:** Akutní zadní multifokální plakoidní pigmentová epitelopatie – kazuistika. *Čes Slov Oftalmol*, 70(2); 2014: 72–6.