

OPTIC DISC DRUSENS AND THEIR COMPLICATIONS

SOUHRN

The aim of the study was to analyze the group of patients with optic disc drusen focusing on possible complications of this disease.

Material and methods: In our group of patients, we examined 46 eyes of 23 patients with the suspicion of optic disc drusen during the period from May 2013 until January 2014. In all adult patients, we examined the anterior and posterior segment of the eye biomicroscopically, established the visual acuity, measured the intraocular pressure, examined the visual field, performed the ultrasound examination of the eye (A and B-scan), analyzed the retinal nerve fiber layer (RNFL) by means of optic coherence tomography (OCT), and color and red-free photography. According to the biomicroscopical findings, the drusen were divided into invisible drusen (buried drusen) (verified by ultrasound only) – grade 0, visible delicate drusen – grade I, and multiple drusen (conglomerates) – grade II.

Results: Out of 23 patients, 14 were women and 9 were men. The age of the patients ranged from 8 to 82 years, the mean age was 44.4 years. In the group, there were 3 children (8, 11, and 13 years). In twenty-two patients, the drusen were present bilaterally, and one female patient had drusen on the right eye only. The grade of the drusen was set from 0 to II in all 45 eyes according to their amount, location, and visibility. As grade 0 were evaluated drusen in 11 patients; out of them, 10 patients had drusen bilaterally, and one female patient unilaterally. Out of these 11 patients, three were children. Grade I optic disc drusen bilaterally had nine patients, and three patients had drusen grade II bilaterally. In grade 0 drusen, no defect of the visual field was noticed. In drusen grade I, it was noticed the defect of the visual field in two patients (four eyes) out of nine patients, and in grade II the defect was present in two out of three patients (three eyes). The evaluation of the RNFL, by means of OCT, was performed among all three groups according to their grade 0 – II. In higher grades, the thickness of the RNFL was lower. Comparing to drusen grade 0, the drusen grade I, and II presented serious thinning of the RNFL superiorly. In three patients (drusen grade 0 and I) other complications of the optic disc drusen were observed. In one female patient with drusen grade I, there was decrease of the visual acuity due to the partial intravitreal hemorrhage in her left eye and parapapillary located retinal hemorrhages. In one male patient with drusen grade 0 was bilateral decrease of the VA due to cystoid macular edema caused by drusen. This patient had also retinal hemorrhages located near the papilla and partial intravitreal hemorrhage in his worse left eye. In one female patient with the drusen grade 0, the tortuous veins were noticed.

Conclusion: Drusen of the optic disc are present in 0.3 – 1.0 % of the population, and are bilateral in approximately 75 – 91 % of the cases. It is important to distinguish optic nerve disc drusen from the papilledema. Drusen of the optic nerve can cause severe defects of the visual field, decrease of the retinal nerve fiber layer, and may be accompanied by vessels complications. Patients with the optic disc drusen should regularly undergo ophthalmologic examinations focused on the intraocular pressure, visual field testing, and retinal fiber layer analysis. In patients with visual field defect and borderline values of intraocular pressure, the antiglaucomatic therapy is recommended.

Key words: optic disc drusen, intraocular pressure, visual field, ultrasound, retinal nerve fiber layer analysis, complications of the optic disc drusen

Čes. a slov. Oftal., 72, 2016, No. 1, p. 298–308

INTRODUCTION

Drusens are spherical hyaline deposits of various sizes, with a tendency towards calcification, found at various depths of the prelaminar region of the optic nerve (ON). Optic disc drusens occur in approximately 0.3 – 1% of the population (autosomal dominant heredity with incomplete penetration is presumed), but the prevalence increases to 3.4% in persons with a family anamnesis (FA) of optic disc drusens [2, 9].

Approximately 75 – 91% of clinical cases are bilateral. Men and women are afflicted with equal frequency. The largest prevalence of the pathology is recorded in the Caucasian population [2].

Optic disc drusens may be linked with various ocular and general pathologies – for example retinitis pigmentosa, open angle glaucoma, Usher syndrome, Noonan syndrome and Alagille syndrome, Ehlers-Danlos syndrome and Paget's disease [2, 3]. Optic disc drusens are also linked with rare disorders such as pseudoxanthoma elasticum and angioid

Štrofová H., Jarošová A.

Vidente s.r.o. – private ophthalmology clinic, Prague, Dr. Alena Jarošová

The authors of the study declare that no conflict of interests exists in the compilation, theme and subsequent publication of this academic communication, and that it is not supported by any pharmaceuticals company.



MUDr. Helena Štrofová
Vinohradská 176
130 00 Praha 3
e-mail:h.strof@seznam.cz

streaks, which occur simultaneously in 85% of patients. The incidence of optic disc drusens in patients with angiod streaks is as much as 21% [2, 3, 7, 8].

The pathogenesis of optic disc drusens is not entirely clear. Drusens are deposits of mucopolysaccharides and material of a proteinic nature (amino acids, nucleic acids), concretions of calcium and sometimes also iron [2, 3, 9]. Some authors are of the opinion that they originate as a consequence of axonal degeneration of the ON or through secondary chronic obstruction of axoplasmatic transport in the congested papilla of the ON [9]. Nevertheless, this is yet to be demonstrated.

Antcliff and Spalton [1] came to the conclusion that the primary pathology of optic disc drusen ensues from hereditary dysplasia of the papilla of the optic nerve and its blood supply, which is susceptible to the formation of optic disc drusens. Dysplasia of the the papilla of the optic nerve may be a primary risk factor for the development of optic disc drusens [1, 2, 3].

In the majority of patients this concerns a chance finding in which the patient suffers no complaints. In some patients, however, blind spots occur in the visual field. Subjective symptoms are abnormalities in peripheral vision or transitional visual blackouts such as “flashing” or “greying” caused by brief episodic ischemia of the nerve. Patients do not usually complain of central loss of vision, which is generally retained. Central visual acuity may be influenced in the case of presence of subretinal neovascularisation of the choroid. Rare cases of obnubilation are described in the literature (circulatory disorders in the region of the posterior ciliary arteries) [3, 6].

Of the examination methods, in first place is ophthalmoscopy, most frequently indirect. There are two main types of drusens: superficial and deeply embedded. The image of superficial drusens is typical and diagnostically problem-free. This concerns isolated or more numerous translucent yellowish-white bodies, which may form larger cluster-like deposits arching above the surface of the papilla of the ON. In the case of drusens embedded in the deep layers, the boundaries of the papilla, in particular nasally, are generally imprecise and undulating. They may imitate papilledema of the ON. It is not possible to diagnose them precisely ophthalmoscopically, but the corrugated surface of the papilla of the ON and the garlanded outline causes suspicion of this diagnosis. In children and young adults they are generally deeply hidden, and only emerge more visibly during the course of life [3, 9, 17]. Drusens are more frequently localised nasally. A calcified deposit measures from 5 to 1000 µm in diameter [3].

Upon perimetric examination blind spots in the visual field are often demonstrated, of the type of bundles of nerve fibres caused by ischemia in the region of the posterior ciliary arteries. The frequency of disruption of the visual field in adult patients with optic disc drusens has been reported within a range from 24% to 87%. Frequently described disruptions of the visual field incorporate enlargement of the blind stain, arcuate scotoma or peripheral scotomas. Nasal blind spots and generalised constriction of the visual field have also been described [2, 3, 9].

Standardised sonography of the eyeball (A and B scan) is a very reliable examination method thanks to the characteristic highly reflective character of optic disc drusens. A B-scan is capable of detecting deeply embedded deposits of calcium in the ON. Small solitary drusens can be identified by ultrasound (US) as hyperechogenic deposits with an acoustic shadow. Calcifications can be identified well even at lower levels of the ultrasound signal. Larger drusens are generally visible on computer tomography (CT). Drusens (especially superficial) are autofluorescent and are thus displayed as light regions on the papilla of the ON.

Upon fluorescence angiography (FAG) drusens are shown as uneven hyperfluorescences, especially in the late phase. This could be useful for differentiating optic disc drusens from actual papilledema [3, 4].

With the help of optical coherence tomography (OCT) it is possible to detect a diminution of the RNFL. Eyes with deeply embedded drusens frequently manifest a normal RNFL. The degree of damage to the RNFL does not always correspond to the degree of disruption of the visual field [3].

Complications – Enlarging drusens may compromise the nerve fibres and vascular supply, which leads to several complications including disruptions of the visual field, occlusion of blood vessels and haemorrhages. Optic disc drusens are very often linked with various anomalies of the ocular arteries and veins. Drusens also share in vascular occlusive complications [3, 5, 9]. Retinal capillaries are often pronouncedly tortuous, and we observe dilated veins.

Ischemic optic neuropathy as a consequence of occlusion of blood vessels is most often the cause of loss of sight in the case of optic disc drusens [3, 15, 19, 20]. Typical risk factors for anterior ischemic optic neuropathy (AION) in patients with drusens may not necessarily be present, in many patients there is a lack of any cardiovascular pathology, and the afflicted patients are of a younger age. We assume that AION occurs more frequently in the case of optic disc drusens because the prelaminar and laminar pial and choroidal supplying arteries become ischemic due to the influence of drusens which enlarge [3, 10]. Central retinal artery occlusion (CRAO) has been observed in patients with optic disc drusens associated with systemic hypertension, migraines, use of hormonal contraception, residing at high altitudes or defects of the ventricular septum [3]. Central retinal vein occlusion has also been observed together with optic disc drusens. Seitz and Kersting [3] assume that drusens may progressively compromise the central retinal vein. In rare cases haemorrhage occurs on the papilla [3]. In the case of optic disc drusens with blind spots of the visual field, larger or smaller atrophies develop. Haemorrhagic or serous macular edema may also occur, with loss of vision [3, 22, 24]. Central serous chorioretinopathy or papillopathy and macular edema are rare, but are also described in the literature in connection with drusens. Central serous papillopathy is an atypical form of central serous chorioretinopathy, with sudden disruption of vision [23]. Optic disc drusens may also lead to juxtapapillary neovascularisation of the choroidea, with subsequent haemorrhage. In younger patients, choroidal neovascularisation is linked with a better prognosis than in older patients. In younger patients the visual

complaints are of mild to medium severity. Although the etiology is not entirely known, it is assumed that optic disc drusens may impair peripapillary circulation. Chorioretinal ischemia may develop as a consequence of this, and thus stimulate the growth of newly formed capillaries. Neovascularisation is characteristically found in the vicinity of the papilla of the ON, and sometimes extends in a direction towards the macula. Juxtapapillary choroidal neovascularisation is not linked with optic disc drusens in older patients, in contrast with the incidence of choroidal neovascularisation in young patients with optic disc drusens [3]. The majority of cases of subretinal neovascularisation linked with optic disc drusens have a milder course. Laser photocoagulation should be considered only in cases where central visual acuity is endangered. Newer methods of treatment include photodynamic therapy and anti-VEGF (vascular endothelial growth factor) preparations [3, 6].

Causal therapy does not exist at present for optic disc drusens. Patients with demonstrated optic disc drusens should be regularly monitored once per year – examinations of IOP, visual field and analysis of the RNFL. In the case of blind spots of the visual field in the presence of optic disc drusens, application of local anti-glaucomatous drugs is generally recommended. Progressive loss of the visual field is caused by direct mechanical compression of the axons of the ganglion cells, circulatory disorders of the posterior ciliary arteries and subsequent ischemic changes. Reduction of IOP may alleviate this process and defer dysfunction of the axons to a certain degree. The significance of these and other prospective therapeutic modalities such as neuroprotective agents, is the subject of research [3, 6, 14].

The authors Jirásková et al. conducted decompression of the ON with disruption of the visual field and recorded a marked improvement of visual function [11, 12, 13].

Prognosis – For the majority of patients, central visual acuity is within the norm. However, it is stated that up to 70% of patients shall have disruptions of the visual field [3, 6]. Optic disc drusens are risk factors for the development of other ocular pathologies (e.g. AION, CRAO, choroidal neovascularisation, cystoid macular edema – CME, glaucoma)

METHOD OF STUDY

In our study cohort we examined 46 eyes of 23 patients with suspicion of optic disc drusens in the period from May 2013 to January 2014. The observed parameters included the age and sex of the patient, subjective complaints, refractive error IOP, vision, visual field, analysis of RNFL, US of eyeball, fundus photography and if applicable complications of optic disc drusen.

We took the patients' anamnesis, focusing primarily in disorders of visual acuity, innate ocular defects, chronic inflammatory ocular pathology, ocular trauma and surgery, previous eye examination and applicable therapy. In the family anamnesis we determined ocular pathologies and visual afflictions.

The patients were examined on a slit lamp, intraocular pressure (IOP) was measured (Computerised tonometer CT

80A, Topcon, 2005) as well as refraction (Full Auto Ref-keratometer, RK-F1, Canon), distance vision was examined on optotypes and close-up vision on well lit reading tables. We conducted a biomicroscopic examination of the ocular fundus, examined the visual field with an automatic perimeter Humphrey 30-2 (first detection 120-3) – (HFA II, Carl Zeiss Meditec, 2007), colour and red-free images were taken on a fundus camera (FF 450plus, Carl Zeiss Meditec AG, 2006). Drusens were confirmed by US of the eyeball – A and B scan (HiScan Optikon, 2000) and we conducted an analysis of the RNFL on OCT (Optical coherence tomography Optovue RT 100-2, 2010).

We differentiated optic disc drusens according to the biomicroscopic finding into invisible drusens – degree 0 – identifiable only sonographically, small visible drusens – degree I, and multiple drusens – degree II. This differentiation is taken from the literature and was modified in the degrees of optic disc drusen [21].

RESULTS

Of the 23 patients with optic disc drusen, 14 were women and 9 were men. All patients were of Caucasian race, with age within the range of 8 to 82 years (average age 44.4 years). The cohort included three children (aged 8, 11 and 13 years). Seven patients were hypermetropic, six myopic, two had astigmatism, five were emmetropic and three myopic with astigmatism.

In the observed study cohort of 23 patients, 18 patients had a chance finding of optic disc drusen, 5 were examined for disorders of vision. The disorders of vision in three patients were caused by a disrupted visual field (patient no. 1, 3, 4), in patients nos. 4 and 5 by partial haemophthalmus and in patient no. 5 additionally by CME bilaterally (Table 1). We did not observe partial atrophy of the disc of the optic nerve in any of the patients. Of the 18 patients with a chance finding, 16 were entirely without complaints (of these two patients were with treated glaucoma, seven with RA glaucoma) and two suffered from headaches. 22 patients had optic disc drusens bilaterally, one patient had drusens only in the right eye – RE.

The degree of optic disc drusens was evaluated from 0 to II in all 45 eyes depending on the amount of drusens, their depositing and visibility. Clinically invisible drusens, identifiable only sonographically, were classified as degree 0, small visible drusens as degree I, multiple superficial drusens as degree II (Fig. 1). Optic disc drusens in 11 patients were classified as degree 0, 10 of whom had optic disc drusens bilaterally and one unilaterally. Of these 11 patients three were children. Nine patients had degree I optic disc drusens bilaterally, and three patients with degree II drusens bilaterally (Graph 1, 2). Of the 20 adult patients, seven had RA glaucoma pathology, two had degree 0 drusens and five had degree I and II drusens. Corrected visual acuity fluctuated within the range of 5/5 to 5/15 in the case of degree I and II optic disc drusens, and within the range of 5/5 to 5/32 in eyes with degree 0 drusens.

The findings on B-scan sonography were positive in 45 eyes. The average IOP in the 20 adult patients was 17.1 torrs in the right eye (RE) and 17.3 torrs in the left eye (LE). Six patients

(eight eyes) had IOP of more than 21 torrs, of whom one patient has newly diagnosed primary open angle glaucoma, five patients (of whom two with RA glaucoma) are being monitored for intraocular hypertension. The visual field was evaluated in all adult eyes with optic disc drusens. In the case of degree 0 optic disc drusens, no defect of the visual field was recorded. In the case of degree I optic disc drusens, a defect of the visual field was recorded in two out of nine patients (four eyes) and in the case of degree II optic disc drusens a defect of the visual field was recorded in two out of three patients (three eyes). For degree I optic disc drusens the following defects of the visual field were recorded: in patient no. 1 spreading of blind stain bilaterally, in patient no. 2 small relative upper peripheral scotoma in RE, in LE suggestion of upper arcuate scotoma (Fig. 2). For degree II optic disc drusens a lower scotoma was recorded in patient no. 3 in RE, in LE arcuate scotoma in the lower nasal quadrant, and in patient no. 4 in lower nasal scotoma in RE, in LE relative upper arcuate scotoma and lower nasal scotoma (Fig. 3). All subjects had a result of the examination of the visual field with less than 33% fixation losses, false positives and false negative results.

A comparison of the thickness of the RNFL on OCT was conducted between each of the three groups of drusens

from degree 0 to II. Higher degrees had a progressively thinner RNFL. In degree 0 optic disc drusens a slight diminution of the RNFL was recorded in two patients (two eyes), although the visual field was unaffected – in one patient there was a diminution in the LE from the superior pole, in the second patient in the LE from the inferior pole and superior-nasally. The average thickness of the RNFL with a diameter of 3.45 mm was in RE 116.72 μm and in LE 107.21 μm . In degree I optic disc drusens a diminution of the RNFL was recorded in seven out of nine patients (11 eyes), of which there were medium severe diminutions of the RNFL in two patients, but no disruption of the visual field was recorded. The diminution of the RNFL was from the superior pole in eight eyes, from the inferior pole in seven eyes. In degree II optic disc drusens a diminution of the RNFL was recorded in all three patients, in two (four eyes) there was medium severe diffusive loss of the RNFL, in one patients (two eyes) slight diminution of the RNFL superior-temporally, also superior-nasally and inferior-nasal thickening of the RNFL in this region. The average thickness of the RNFL in degree I drusens in RE was 101.56 μm in comparison with degree II drusens 93.35 μm , LE 97.26 μm in degree I drusens in comparison with degree II drusens, in which it was 91.64 μm (Graph 3). In

Tab. 1 Souhrn pacientů s patologickým zorným polem a s jinými komplikacemi

Pacienti pohlaví/věk	OP/OL	Nejlépe korigovaná zraková ostrost OP i OL	Porucha zorného pole	Stupeň drúz papily ZN	Průměrná tloušťka RNFL v μm v průměru 3,45 mm /Analýza RNFL	Jiné komplikace
Pacient č. 1 žena/62 let	OP	5/7,5	Rozšíření slepé skvrny	I	100,99 Mírný úbytek v ST	ne
	OL	5/7,5	Rozšíření slepé skvrny		103,26 Mírný úbytek v IT	
Pacient č. 2 žena/32let	OP	5/5	Drobné relativní horní skotomy	I	107,27 Fyziologické	ne
	OL	5/5	Náznak horního arkuátního skotomu		102,37 Mírný úbytek IN	
Pacient č. 3 muž/78 let	OP	5/7,5	Dolní skotom	II	76,94 Mírný úbytek v ST a IN	ne
	OL	5/10	Obloukovitý skotom v dolním nazálním kvadrantu		69,35 Difúzní úbytek	
Pacient č. 4 žena/60 let	OP	5/7,5	Dolní nasální skotom	II	82,28 Difúzní úbytek	P. HMF OL, PH OL
	OL	5/15	Horní relativní skotom, dolní nazální skotom		78,88 Difúzní úbytek	
Pacient č. 5 muž/38 let	OP	5/15	Fyziologické zorné pole	0	109,54 Fyziologické	CME OPL, PH OL, P. HMF OL
	OL	5/32	Fyziologické zorné pole		108,3 Fyziologické	

Vysvětlivky: OP – pravé oko, OL – levé oko, OPL – oko pravé i levé, RNFL – vrstva nervových vláken, ST – úsek superotemporálně, SN – úsek superonazálně, IN – úsek inferonazálně, IT – úsek inferotemporálně, P. HMF – parciální hemoftalmus, PH – parapapilární hemoragie, CME – cystoidní makulární edém.

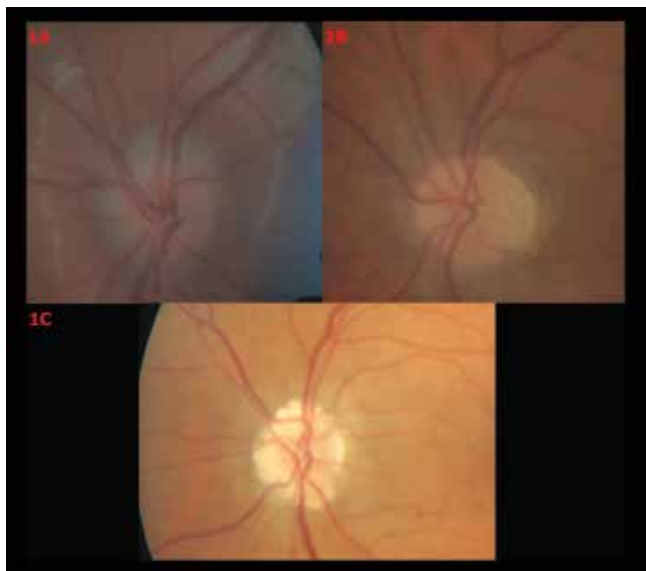
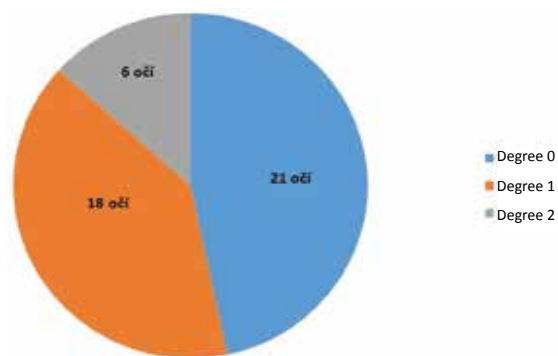


Fig. 1 – Colour photographs of papilla of optic nerve in various stages of drusen

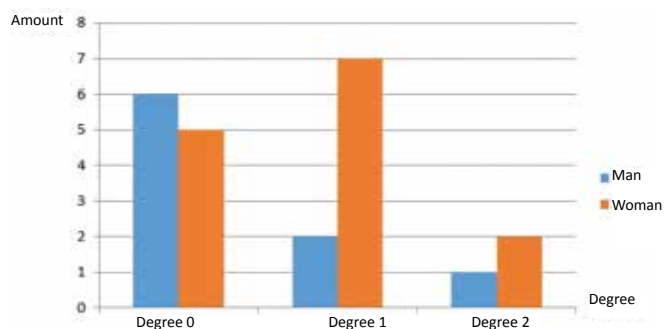
1A – Degree 0 drusen, 1B – degree I drusen, 1C – degree II drusen

comparison with degree 0 drusen, degrees I and II demonstrated significant thinning of the RNFL from the superior pole (Graph 4).

In optic disc drusen there was furthermore evident thicke-



Graph 1 – Division of eyes according to degrees of optic disc drusen 0-II



Graph 2 – Representation of sex in individual degrees of optic disc drusen

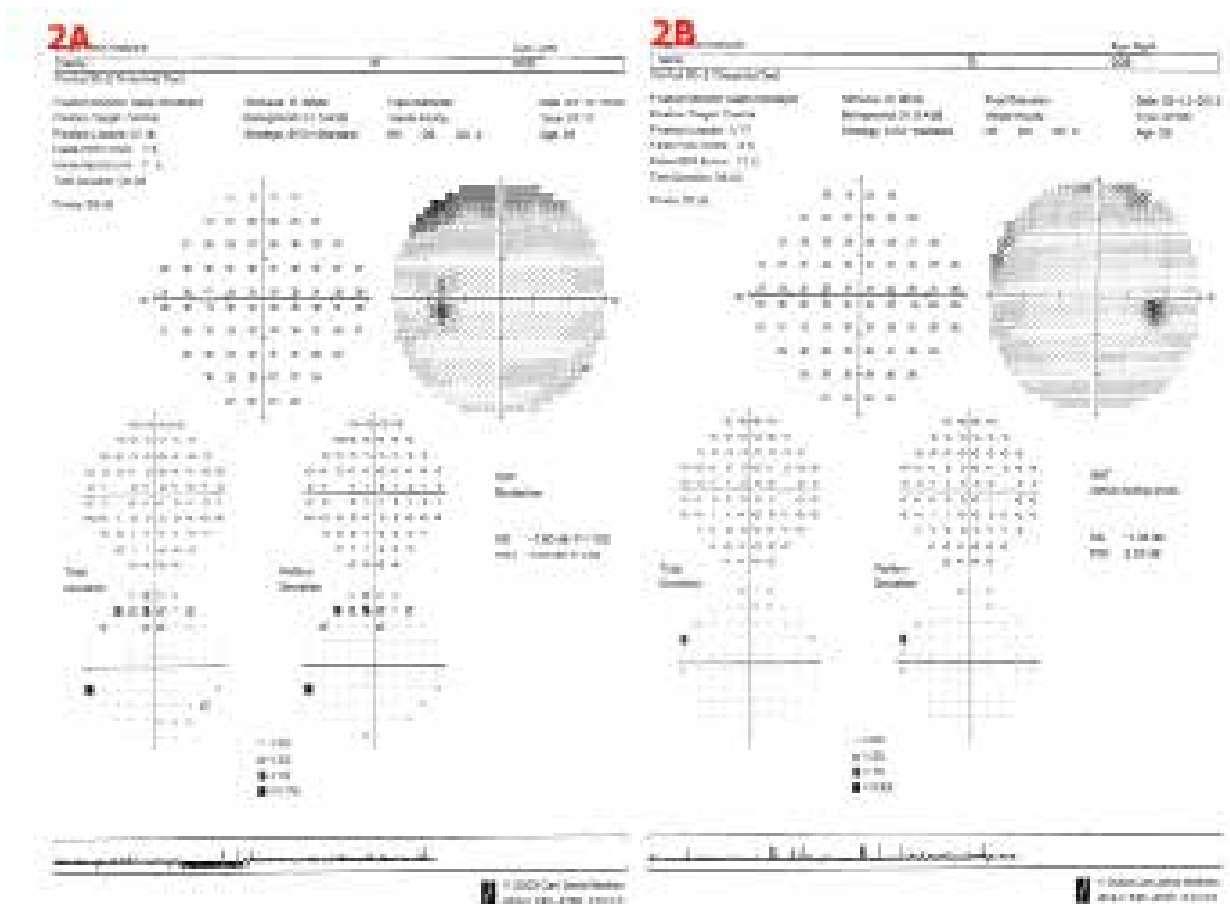


Fig. 2 – Perimetric examination on patient no. 2

2A – LE – suggestion of upper arcuate scotoma, 2B – RE – small relative upper scotomas.

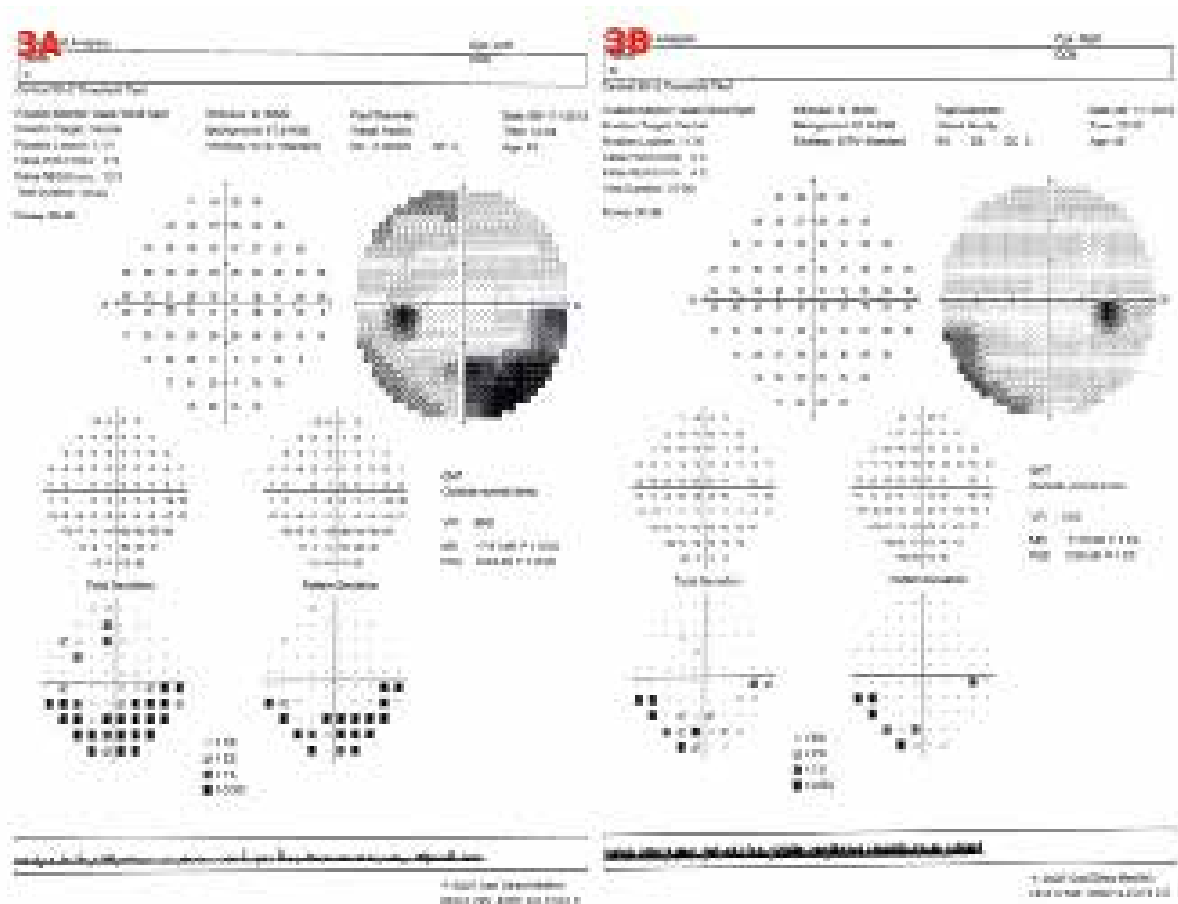


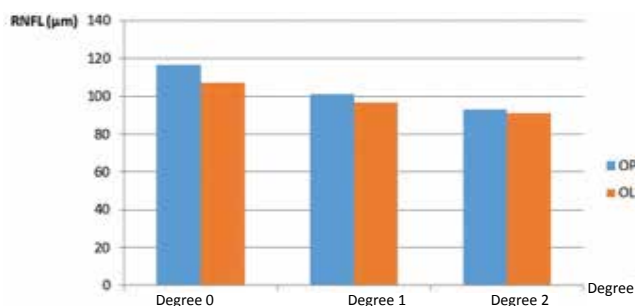
Fig. 3 – Perimetric examination on patient no. 4 3A – LE – arcuate lower nasal scotoma, relative upper temporal scotoma, 3B – RE – lower nasal scotoma.

ning of the RNFL, in degree 0 in four patients (four eyes), in degree I in no patients and in degree II in one patient (two eyes).

In 3 patients (degree 0 and I) we observed other complications of optic disc drusens. In patient no. 4 with degree I drusens there was a disorder of vision due to partial haemophthalmus in LE and there was also present peripapillary haemorrhage. In patient no. 5 with degree 0 drusens there was a disorder of vision due to CME bilaterally on a background of drusens. The patient also had peripapillary haemorrhage in the worse LE, partial haemophthalmus and shunts on the papilla of the ON. In one patient with degree 0 drusens pro-

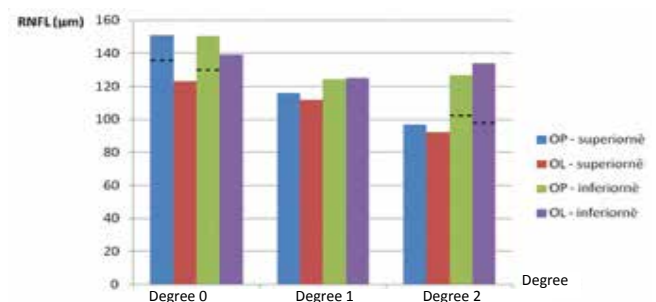
nouncedly tortuous capillaries were found (Table 2).

Six patients from the study cohort are treated with anti-glaucomatous drugs – two patients have previously diagnosed glaucoma, one has newly diagnosed primary open-angle glaucoma (patient no. 3), patient no. 5 is undergoing anti-glaucomatous therapy for CME on a background of optic disc drusens, patient no. 1 for disruption of the visual field on the basis of optic disc drusens and patient no. 4



Graph 3 – Comparison of RNFL in micrometres according to OCT for degree 0-II drusens. Thinning of RNFL is in patients with higher degrees – I and II.

Key: RE – right eye, LE – left eye, RNFL – retinal nerve fibre layer in micrometres (µm), OCT – optical coherence tomography.



Graph 4 – Comparison of RNFL in micrometres superior and inferior according to OCT for degrees of optic disc drusens. Significant thinning of RNFL thickness is mainly superior in patients with optic disc drusens degree I and II.

Key: Broken lines – leaving of patient with thickening of RNFL – below line.

RE – right eye, LE – left eye, RNFL – retinal nerve fibre layer in micrometres (µm), OCT – optical coherence tomography

Tab. 2 Oční komplikace drúz ZN u našeho souboru pacientů

Oční komplikace	Počet pacientů
Defekty zorného pole	4
Úbytek RNFL	12
Hemoragie papily ZN	2
Hemofthalmus	2
Tortuózní cévy	1
CME	1

Vysvětlivky: RNFL – vrstva nervových vláken, ZN – zrakový nerv, CME – cystoidní makulární edém.

for disruption of the visual field and diminution of the RNFL (normotensive glaucoma cannot be excluded) (Fig. 4, 5, 6).

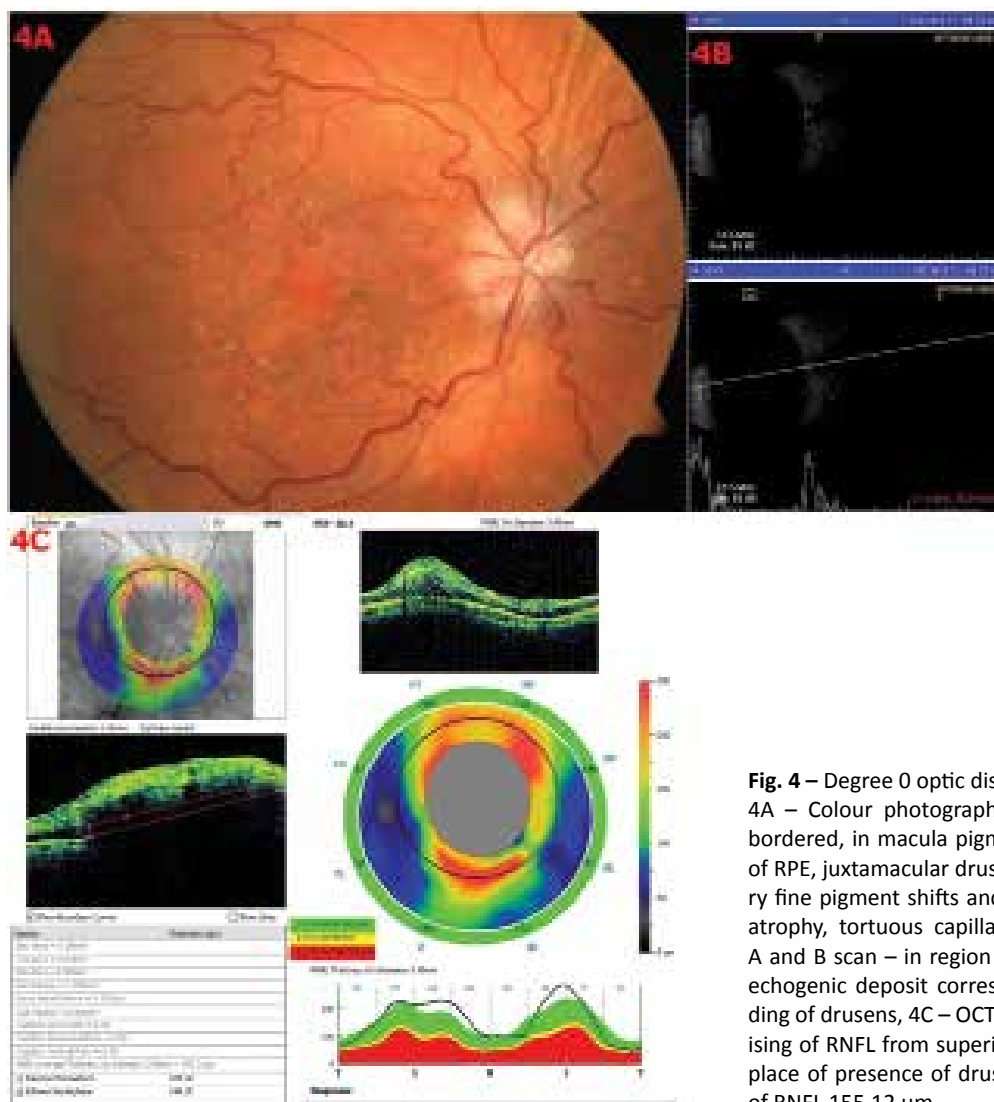
DISCUSSION

Optic disc drusens are usually bilateral and in most cases are asymptomatic. Men and women are afflicted with equal frequency [2]. In our study cohort there was only one

patient with unilateral optic disc drusens, thus we demonstrated 95.5% of drusens bilaterally. Optic disc drusens do not usually occur in children aged under four years, our youngest patient was aged 8 years and the oldest 82 years. There was a slight predominance of women in our cohort. In the majority of patients this represents a chance finding, a proportion of patients experience deterioration of visual acuity and blind spots in the visual field [3]. The authors Obuchowska and Mariak [16] point to the frequent association of optic disc drusens and hypermetropic eyes.

In the observed cohort (23 patients) 18 patients had a chance finding, only 5 were examined for disorders of vision. Of the 18 patients with a chance finding, 16 were entirely without complaints and 2 suffered from headaches. Visual acuity was reduced by other ocular defects or complications of optic disc drusens. No refractive error predominated in our cohort.

The image of superficial optic disc drusens is typical and diagnostically problem-free. There are isolated or more numerous translucent yellowish-white bodies which may form cluster-like deposits arching above the surface of the papilla. In the case of drusens embedded in the deep layers,

**Fig. 4** – Degree 0 optic disc drusen

4A – Colour photograph – papilla not sharply bordered, in macula pigment shifts and atrophy of RPE, juxtamacular drusens, in central periphery fine pigment shifts and small deposits of RPE atrophy, tortuous capillaries, 4B – Sonography A and B scan – in region of papilla of ON highly echogenic deposit corresponding to clinical finding of drusens, 4C – OCT – analysis of RNFL – raising of RNFL from superior and inferior poles in place of presence of drusens, average thickness of RNFL 155.12 μm .

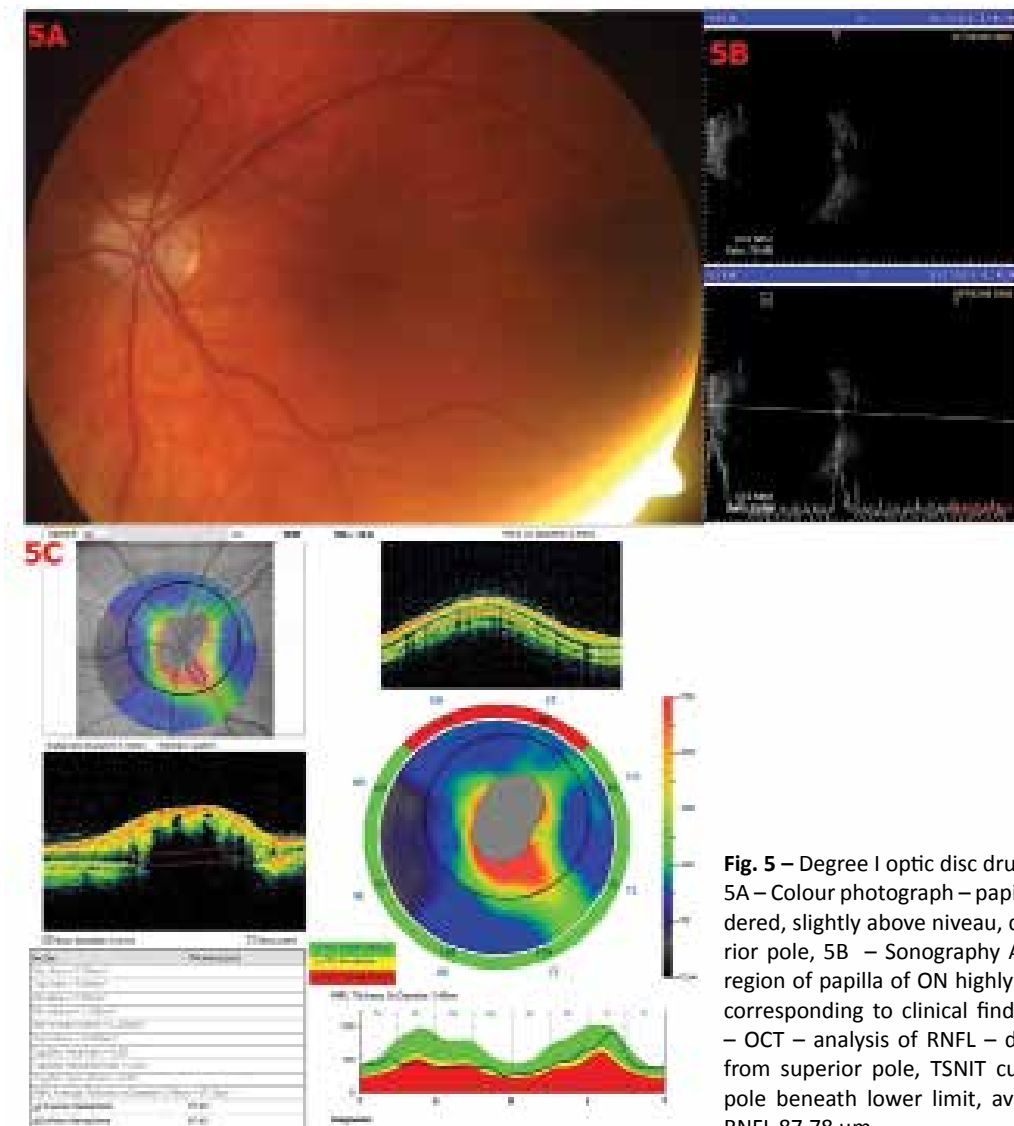


Fig. 5 – Degree I optic disc drusen
5A – Colour photograph – papilla not sharply bordered, slightly above niveau, drusens from superior pole, 5B – Sonography A and B scan – in region of papilla of ON highly echogenic deposit corresponding to clinical finding of drusens, 5C – OCT – analysis of RNFL – diminution of RNFL from superior pole, TSNIT curve from superior pole beneath lower limit, average thickness of RNFL 87.78 μm .

the boundaries of the papilla, in particular nasally, are generally imprecise and undulating. They may imitate papilledema of the ON. It is not possible to diagnose them precisely ophthalmoscopically, but the corrugated surface of the papilla of the ON and the garlanded outline causes suspicion of this diagnosis. In children and young adults optic disc drusens are generally deeply hidden, and only emerge more visibly during the course of life [3, 9, 17].

Our patients were divided into degrees 0-II according to the visibility of the optic disc drusens. All age groups were represented in degree 0 drusens, in the case of degree I-II drusens all the patients were aged over 27 years.

Optic disc drusens are diagnosed most reliably with the help of B-scan sonography [3]. We confirmed optic disc drusens sonographically in all our 23 patients, the finding was unilateral in only one patient. Enlarging drusens may compromise and endanger the nerve fibres and vascular supply, which leads to several complications, including disruptions of the visual field, occlusion of capillaries and haemorrhages [3]. Defects of the visual field in the case of optic disc drusens are common, with frequency ranging from 24 % to 87 %. De-

fects of the visual field reminiscent of glaucoma damage are often observed in patients with optic disc drusens. Concentric constriction of the visual field, spread of a blind stain and arcuate scotoma are characteristic defects of the visual field for optic disc drusens. Defects are most commonly found in the lower bundle of nerve fibres. These defects of the visual field may not necessarily correspond to the position of the optic disc drusen, with the result that interpretation of the defects of the visual field by optic disc drusens is more difficult [3]. In a study by the authors Wilkins and Pomeranz, 73 % of patients with visible optic disc drusens had an abnormal visual field in comparison with only 36% of patients with deep optic disc drusens [26]. According to a study by Katz and Pomeranz, disruptions of the visual field are less common in the case of more deeply embedded optic disc drusens [16].

In our cohort, two out of three patients (three eyes) with degree II optic disc drusens had an abnormal visual field, in comparison with two out of nine patients (four eyes) with degree I optic disc drusens. We did not record concentric constriction of the visual field in any patient. The most com-

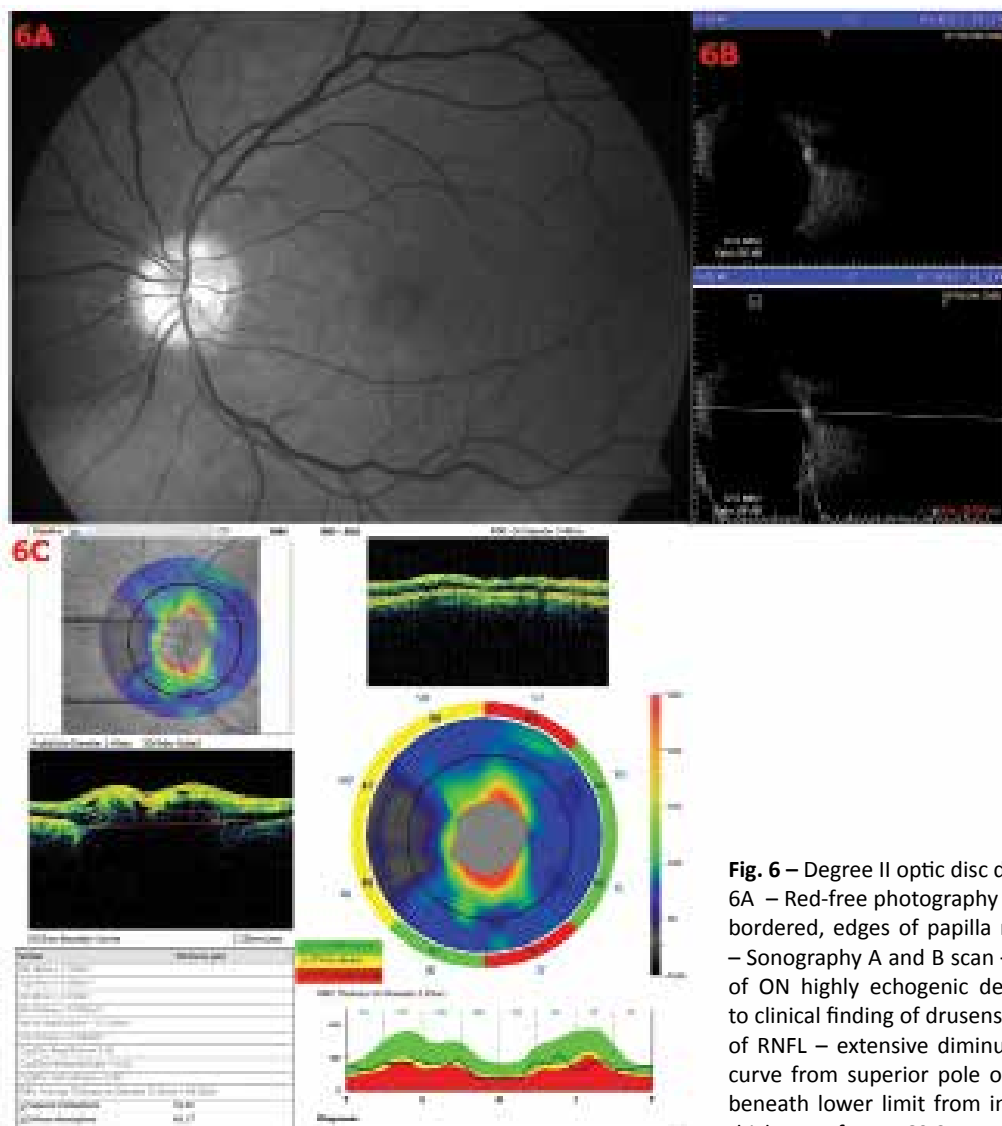


Fig. 6 – Degree II optic disc drusen

6A – Red-free photography – papilla not sharply bordered, edges of papilla rough – drusens, 6B – Sonography A and B scan – in region of papilla of ON highly echogenic deposit corresponding to clinical finding of drusens, 6C – OCT – analysis of RNFL – extensive diminution of RNFL, TSNIT curve from superior pole on borderline norms, beneath lower limit from inferior pole, average thickness of RNFL 69.35 μm .

mon defects of the visual fields were recorded in the lower quadrants.

A study by the authors Roh et al. described loss of the RNFL in correlation with the degree of visible optic disc drusens. The presence of deep degree 0 drusens which are not clinically evident did not represent any diminution of the RNFL. In patients with superficial drusens, a diminution of the RNFL was evident, as demonstrated by the pronounced diminution of the RNFL in patients with degree I and II drusens in comparison with degree 0 drusens. This means that deeply embedded optic disc drusens do not influence the thickness of the RNFL, in contrast with clinically visible optic disc drusens [25]. In patients with deeply embedded drusens, focal defects of the RNFL may occur, but with normal average thickness of the RNFL [21]. Our results support this finding. Patients with higher degrees of drusens had a thinner RNFL. Patients with degree 0 drusens had imperceptible thinning in the RNFL. In comparison with patients with degree 0 drusens, patients with degree I and II drusens manifested significant thinning of the RNFL from the superior pole. In some patients with degree 0 and II drusens there

was furthermore evident thickening of the RNFL, evidently as a consequence of infarction of the nerve fibres and subsequent swelling of the RNFL in the area of calcification. Nevertheless, thickening of the nerve fibres may also be caused by deep optic disc drusens (Fig. 7) [25].

Optic disc drusens are very often linked with various anomalies of the arteries and veins. In a study by the authors Auw-Haendrich et al. on patients with optic disc drusens, the incidence of retinal haemorrhages was from 2 to 10 % [3]. In a study by Borruat and Sanders, haemorrhages occurred in 23 eyes out of 116 cases. The majority of haemorrhages occurred in the case of deep drusens. Vascular shunts occurred in 6.9% of cases, the majority in more superficial drusens [6]. In two patients we recorded splinter haemorrhages on the papilla of the ON, and also two patients with partial haemophthalmus, whose optic disc drusens were degrees 0 and I.

We commenced anti-glaucomatous therapy on one patient due to a disruption of the visual field, on two patients due to diminution of the RNFL and on one for CME bilaterally on a background of optic disc drusens.

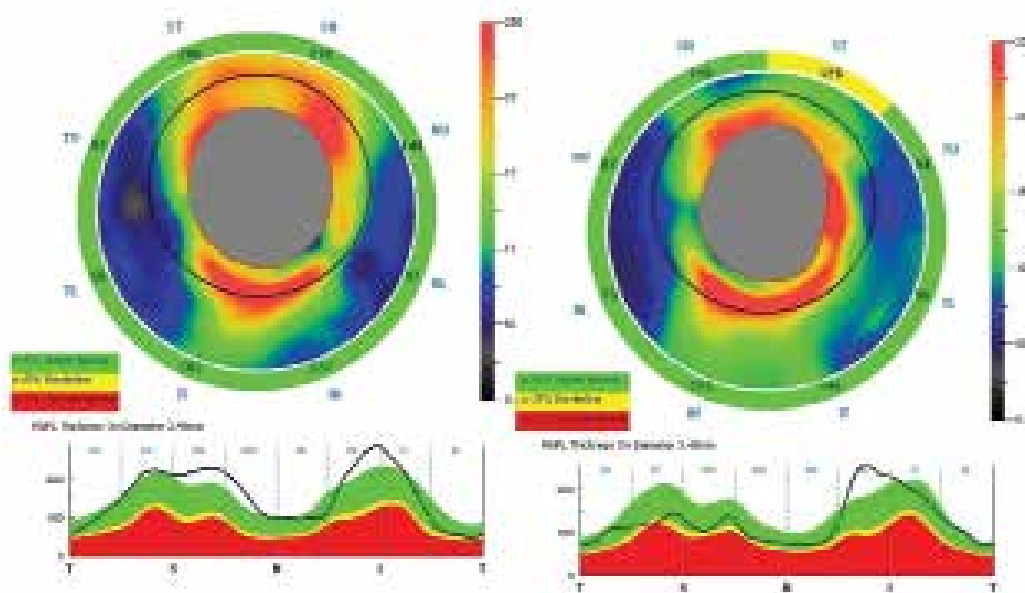


Fig. 7 – Thickening of RNFL on OCT in optic disc drusen

CONCLUSION

Optic disc drusen occur in 0.3 – 1 % of the population and are bilateral in approximately 75 – 91% of patients. Drusen grow with age as a consequence of continuing apposition of calcium. Deep optic disc drusen should be included in differential diagnostics of papilledema of the ON.

Optic disc drusen may cause serious defects of the visual field simulating defects in glaucoma, as well as diminution of the RNFL, and are frequently accompanied by circulatory disorders of the branches of the posterior ciliary arteries, primarily the disc of the ON. Ultrasound is the most reliable

method for diagnosis of deep, invisible optic disc drusen. Patients with drusen of the ON should undergo regular eye examinations focusing on IOP, visual field and analysis of RNFL. Anti-glaucomatous therapy is recommended for patients with disruption of the visual field and borderline IOP.

Thanks to Dr. Petra Svozílková of the Department of Ophthalmology, 1st Faculty of Medicine at Charles University in Prague and the General University Hospital in Prague for professional consultation. The pictorial documentation and data was obtained at the Department of Ophthalmology at Thomayer Hospital – thank you.

LITERATURE

1. Antclif, R., Spalton, D.: Are optic disk drusen inherited? *Ophthalmology*, 1999; vol. 106, no. 7: s. 1278–1281.
2. Aumiller, M. S.: Optic disc drusen: Complications and management. *Optometry – Journal of the American Optometric Association*, 2007; vol. 78, no. 1: 10–16.
3. Auw-Haendrich, C., Staubach, F., Witschel, H.: Optic Disk Drusen. *Survey of Ophthalmology*, 2002; vol. 47, no. 6: 515–532.
4. Baráková, D.: *Echografie v oftalmologii*. 1. vyd. Praha: Professional Publishing, 2002, 150 s. ISBN 8086419150.
5. Borruat, F. X., Sanders, M.: Vascular anomalies and complications of optic nerve drusen. *Graefes' Archive For Clinical and Experimental Ophthalmology* [online]. 1998, vol. 20, iss. 5. [cit. 1996-05-01]. Dostupné z <<http://www.ncbi.nlm.nih.gov/pubmed/8766031>>.
6. Davis, P. L., Jay, W. M.: Optic nerve head drusen. *Seminars in Ophthalmology*, December 2003; vol. 18, no. 4: 222–242.
7. Fišer, I.: Angioidní pruhy. In: Kuchynka, P. et al. *Oční lékařství*. 1. vyd. Praha: Grada, 2007. Kapitola 10.7, s. 336–337.
8. Georgalas, I., Papaconstantinou, D., Koursandre, C., et al.: Angioid streaks, clinical course, complications and current therapeutic management. *Therapeutics and Clinical Risk Management* [online]. March 2009, vol. 5. [cit. 2009-03-26]. Dostupné z <<http://www.ncbi.nlm.nih.gov/pmc/articles/PMC2697526>>.
9. Grippo, T. M., Rogers, S. W., Tsai, J. C., et al.: Optic Disc Drusen: Practical implications and management. *Glaucoma today*, January - February 2012: 19–24.
10. Hauptvogelová, M., Šustykevičová, Z.: Non-arteritická predná ischemická optická neuropatia pri drúzach zrakového nervu. *Čes a slov Oftalmol*, 2010; 66, no. 2: 184–187.
11. Jirásková, N., Rozsival, P.: Dekomprese obalu zrakového nervu. *Čes a slov Oftalmol*, 1995; vol. 51: 254–257.
12. Jirásková, N., Rozsival, P.: Dekomprese obalu zrakového nervu – výsledky u prvních 37 operovaných očí. *Čes a slov Oftalmol*, 1996; vol. 52, no. 5: 297–308.
13. Jirásková, N., Rozsival, P.: Výsledky 62 dekompresí obalu zrakového nervu. *Čes a slov Oftalmol*, 1999; vol. 55, no. 3: 136–144.
14. Kanski, J. J.: *Ophthalmology: Clinical Signs and Differential Diagnosis*. 5th edition. Mosby International Limited, 2007. 485 s. ISBN 0-7234-3121-3.
15. Karel, I., Otradovec, J., Peleška, M.: Fluorescence angiography in circulatory disturbances in drusen of the optic disc. *Ophthalmologica*, 164; 1972: 449–462.
16. Katz, B. J., Pomeranz, H. D.: Visual field defects and retinal nerve fiber layer defects in eyes with buried optic nerve dru-

- sen. American Journal of Ophthalmology. February 2006; vol. 141, no. 2: 248–253.
17. **Kuchynka, P. et al.:** Oční lékařství. 1.vyd. Praha: Grada, 2007. 768 s. ISBN 978-80-247-1163-8.
 18. **Obuchowska, I., Mariak, Z.:** Refraction and the axial length of the eyeball in patients with the optic disc drusen. American Journal of Ophthalmology [online]. January 2009; vol. 111, no. 1-3: s. 33–36.
 19. **Otradovec, J., Karel, I.:** Příspěvek k patogenezi funkčních poruch u drúzové papily. Čs Oftalmol, 29; 1973: 262–272.
 20. **Otradovec, J.:** Klinická neurooftalmologie. 1. vyd. Praha: Grada a.s., 2003. 504 s. ISBN 80-247-0280-0.
 21. **Roh, S., Noecker, R., Schuman, J. S., et al.:** Effect of Optic Nerve Head Drusen on Nerve Fiber Layer Thickness. Ophthalmology, May 1998; vol. 105, no. 5: 878–885.
 22. **Romero, J., - Sowka, J., Shechtman, D.:** Hemorrhagic complications of optic disc drusen and available treatment options. Optometry - Journal of the American Optometric Association, September 2008; vol. 79, no. 9: 496–500.
 23. **Suelves, A. M., Francés-Munoz, E., Gallego-Pinazo, R., et al.:** Central serous papillopathy by optic nerve head drusen. Clinical Ophthalmology, November 2010; vol. 25, no. 4: 1379–1382.
 24. **Tryfon, G. R., Marilita, M. M.:** Cystoid macular edema. Clinical Ophthalmology, December 2008; vol. 2, no. 4: 919–930.
 25. **Turgut, B., Kaya, M. K., Demir, T.:** An atypical case of optic disc drusen with nerve fiber layer thickening. Eye and Brain [online]. May 2010, vol. 2. [cit. 2010-05-26]. Dostupné z <<http://www.dovepress.com/getfile.php?fileID=6430>>.
 26. **Wilkins, J.M., Pomeranz, H.D.:** Visual manifestations of visible and buried optic disc drusen. Journal of Neuro-Ophthalmology, June 2004; vol. 24, no. 2: 125–129.