

Fatal progression of multifocal infection of *Aspergillus sp.* and multi-resistant *Pseudomonas aeruginosa* in a patient with toxic epidermal necrolysis and renal cancer

Lipový B.^{1,2}, Říhová H.¹, Hanslianová M.³, Chaloupková Z.^{1,2}, Hromaníková M.^{1,2}, Pavlovský Z.⁴, Kempný T.¹, Suchánek I.¹, Brychta P.^{1,2}

¹Department of Burns and Reconstructive Surgery, University Hospital Brno, Czech Republic

²Medical Faculty of Masaryk University Brno, Czech Republic

³Department of Clinical Microbiology, University Hospital Brno, Czech Republic

⁴Department of Pathology, University Hospital Brno, Czech Republic

ABSTRACT

Toxic epidermal necrolysis is an autoimmune disease expressed predominantly on the skin and mucous membranes. It is a serious bullous disease manifesting itself by induction of apoptosis in the dermo-epidermal junction. In most cases, it is attributable to the use of some drug. The basic approach to stopping progression of the disease is immunosuppression. Unfortunately, patients with such extensive loss of epidermis and defective mucosa are confronted by a variety of opportunistic, potentially pathogenic microorganisms. Unsurprisingly, infectious complications are

today a predominant cause of death in patients thusly affected. Despite thorough review of the literature, we found no comprehensive case report concerning the development of multifocal *Aspergillus* infection in patients with this disease

KEYWORDS:

toxic epidermal necrolysis – *Pseudomonas aeruginosa* – *Aspergillus sp.*

SOUHRN

Lipový B., Říhová H., Hanslianová M., Hromaníková M., Pavlovský Z., Kempný T., Suchánek I., Brychta P.: **Fatální průběh multifokální infekce *Aspergillus sp.* a multirezistentní *Pseudomonas aeruginosa* u pacienta s toxickou epidermální nekrolýzou a renální malignitou**

Toxická epidermální nekrolýza je autoimunitní onemocnění, které se dominantně projevuje v oblasti kůže a sliznic. Jedná se o závažné bulózní onemocnění, při kterém dochází k indukci apoptózy v oblasti dermo-epidermální junctce. U většiny případů byla popsána souvislost s předchozím užitím nějakého farmaka. Základním přístupem k zastavení progresu onemocnění je imunosuprese. Bohužel pacienti s rozsáhlou ztrátou kožního

krytu a mnohdy defektní sliznici jsou konfrontováni s celou řadou často i oportunních potenciálně patogenních mikroorganismů. Nepřekvapí proto, že v dnešní době jsou infekční komplikace dominantní příčinou úmrtí u takto postižených pacientů. I přes důslednou literární revizi jsme nenašli ucelenou kazuistiku týkající se rozvoje multifokální aspergilové infekce u pacienta s tímto onemocněním.

KLÍČOVÁ SLOVA:

toxická epidermální nekrolýza – *Pseudomonas aeruginosa* – *Aspergillus sp.*

Epidemiol. Mikrobiol. Imunol., 66, 2017, č. 3, s. 128–132

INTRODUCTION

Toxic epidermal necrolysis (TEN) was first described in 1956 by Scottish dermatologist Alan Lyell. It is a life-threatening, drug-induced toxoallergic reaction causing extensive skin and mucous exfoliation in the dermo-epidermal junction (induction of apoptosis). The condition is also complicated by systemic toxicity [1]. Toxic epidermal necrolysis syndrome is the most serious of the SCARS (Severe Cutaneous Adverse Reactions) group. Incidence in the population is very rare, and it ranges from 0.5–2 cases per million inhabitants per year. The disease is associated

with a high mortality rate (30–50%) [2]. Unlike in the case of Stevens-Johnson syndrome (SJS), a minimum exfoliation range of 30% of total body surface area (TBSA) must be present for diagnosis of TEN. An important clinical feature is the pseudo-Nikolsky sign, wherein slow pulling of the affected skin leads to its exfoliation. This is the immunological response to the presence of a foreign antigen [3]. In the case of TEN, an association with the start of using special drugs is often evident. It is not always easy to determine the causative agent. It is reported that in about 5% of patients no drug association can be detected [4]. Increasingly, the importance of a vi-

rus (HSV, HIV) or mycoplasma infection is mentioned in connection with the development of TEN [5].

Due to the nature of this disease, the basic therapeutic approaches include immunoparalysis, immunosuppression, or such other procedures as intravenous immunoglobulin or plasmapheresis. Consequently, therapy often leads to the development of infectious complications caused by opportunistic, potentially pathogenic microorganisms. It is therefore absolutely necessary to conduct precise microbiological surveillance and react promptly to the results. In our case report, we present that even constant microbiological monitoring and administration of targeted antimicrobial therapy do not always guarantee success. Despite regression of the local state, the patient developed combined multifocal infection caused by multi-resistant *Pseudomonas aeruginosa* and *Aspergillus* sp. (the second was not detected until the autopsy, because the symptoms had been masked by pseudomonas infection).

CASE REPORT

A male patient who had been hospitalized primarily in the internal department for acute coronary syndrome and bilateral cardiac decompensation was admitted to the Department of Burns and Reconstructive Surgery at University Hospital Brno. Echocardiography detected diastolic dysfunction of the left ventricle with restrictive filling character and haemodynamically significant mitral regurgitation. The ejection fraction was estimated to be 30–40%. Angiography for peripheral arterial disease was performed on the patient, and in doing so a tumour was found on the lower pole of the right kidney (renal cell carcinoma of size 7 x 8 x 5.5 cm). The urologist indicated nephrectomy. During hospitalization, the patient developed nosocomial bilateral bronchopneumonia. According to the results from microbiological surveillance of the respiratory tract and antibiotic sensitivity, amoxicillin/clavulanate therapy was indicated. Toxoallergic exanthema developed six days after the beginning of boosted aminopenicillin therapy. At that time, the patient was also medicated with nadroparin and omeprazole with amlodipine as part of chronic medication. A consulting dermatologist indicated therapy with corticosteroids (methylprednisolone in dose 125-0-80 mg) and expressed suspicion of the potential development of TEN. Despite the therapy, the disease progressed to 35% exfoliation of TBSA. The patient was transferred to our department seven days after the onset of symptoms. Upon admission, the patient was medicated with vancomycin in a dose of 500 mg/8 hours to identify gram-positive bacteria in the exfoliated areas. According to the results and clinical findings, the primary scoring severity of TEN (SCORTEN – SCOR of Toxic Epidermal Necrosis) was evaluated as 3 points [6]. Such score prognoses 35.3% mortality. One of the calculated risk factors for mortality was the presence of malignancy. Nephrectomy was indicated in the patient, although he had no oncological treatment other than surgical therapy.

Primary treatment was performed under general anaesthesia in the operating room, where the overall extent and localization of the infection was evaluated. The mucosa was primarily affected only in the

conjunctiva and no further mucosal impairment was found. Photographic documentation from the primary treatment at the department is shown in Figure 1.

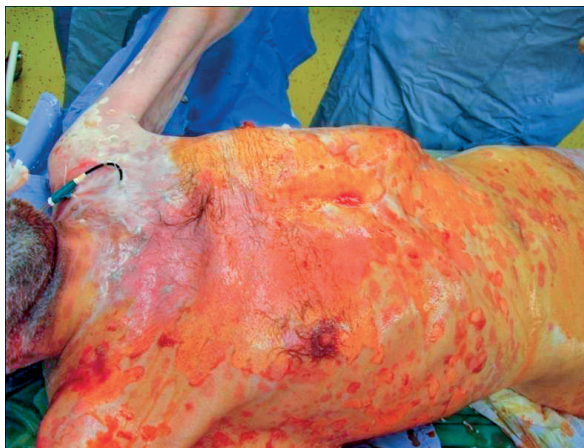

Figure 1. Extent of exfoliated surfaces on the ventral trunk

We increased the amount of corticosteroids (methylprednisolone at 125-80-80mg) to the patient. Alginate (Flaminal® Hydro) was applied topically to affected surfaces and the patient was re-dressed under general anaesthesia every two days. An antiseptic containing octenidine dihydrochloride was used for secondary cover. Despite the slow phase process, wounds progressively epithelized and were partially healed by the 22nd day of hospitalization. About 10% of TBSA continued to show deep defects due to the infection. The quality of the granulation tissue weakened due to the corticosteroid therapy. When taking dermo-epidermal graft we would create further skin defects in the donor sites. Moreover, with the disturbed granulation tissue it would be very difficult to heal the recipient site itself. Despite balanced enteral and parenteral nutrition, this led to gradual deterioration of cachexia and the patient died on the 42nd day due to severe sepsis of multi-pathogen aetiology.

Microbiology

Gram-positive cocci (coagulase-negative *Staphylococcus*) and *Klebsiella pneumoniae*, which produced a broad spectrum beta-lactamase (Extended Spectrum Beta Lactamase = ESBL +) were isolated already upon primary microbiological surveillance of material from exfoliated surfaces obtained by semi-quantitative imprint method. At the same time, several potentially pathogenic microorganisms (*Morganella morganii* and *Escherichia coli*) were also isolated from primary examination of the urine. Only normal flora was isolated from the respiratory tract, and the blood culture was primarily sterile.

Coagulase-negative *Staphylococci* and *Klebsiella pneumoniae* producing ESBL from the exfoliated surfaces were repeatedly isolated during hospitalization. *Klebsiella pneumoniae* ESBL+ was detected in blood cultures after three weeks of hospitalization. Later, the state of the patient was complicated by pseudomonas infection of the surfaces (multi-resistant *Pseudomonas aeruginosa* with proven sensitivity only to colistin and intermediate sensitivity to

PŮVODNÍ PRÁCE

Table 1. Compartments and detection of various pathogens during hospitalization

	Week 1	Week 2	Week 3	Week 4
Exfoliated surfaces	KLPN ESBL+ CNS	KLPN ESBL+	–	PSAE-MDR KLPN ESBL+
Bloodstream	–	–	KLPN ESBL+ CNS	PSAE-MDR
Lower respiratory tract	–	–	PSAE-MDR KLPN ESBL+	PSAE-MDR
Urinary system	MOMO ESCO CA	PRMI	PSAE-MDR	PRMI PSAE-MDR

(KLPN ESBL+ = *Klebsiella pneumoniae* producing ESBL, CNS = coagulase-negative *Staphylococcus*, MOMO = *Morganella morganii*, ESCO = *Escherichia coli*, CA = *Candida albicans*, PRMI = *Proteus mirabilis*, PSAE-MDR = multidrug-resistant *Pseudomonas aeruginosa*)

amikacin), also with a response in blood cultures. This strain was also the originator of chorioretinitis, which developed on the 40th day of hospitalization (Fig. 2). Detection of potentially pathogenic microorganisms in different compartments and periods of hospitalization is reported in Table 1.

Throughout the hospitalization period, all biological material sent for culture was examined for the presence of bacterial pathogens as well as for the presence of yeasts and moulds. Except for the first examination at the beginning of hospitalization, when *Candida albicans* was isolated from the end of the excavated urinary

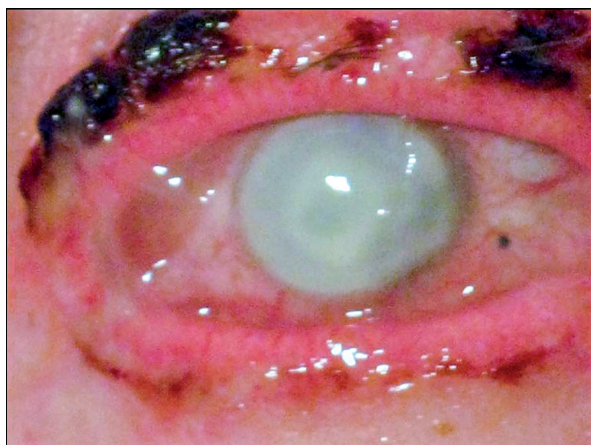

Figure 2. Chorioretinitis of the right eye of endogenous aetiology verified by ultrasonography and laboratory. Originating from multi-resistant strain of *Pseudomonas aeruginosa*.

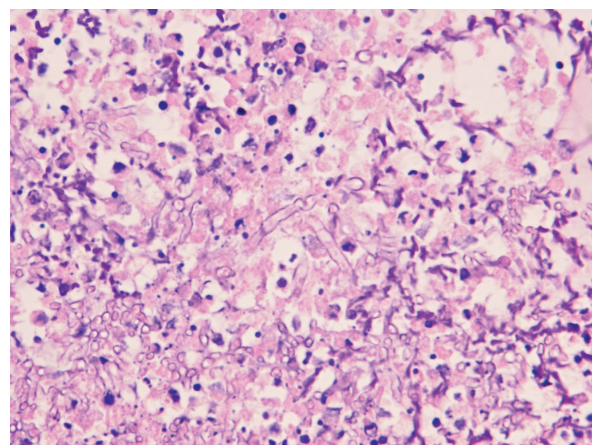


Figure 4. *Aspergillus* sp. in the right frontal lobe of the brain (haematoxylin-eosin staining, 800x magnification)

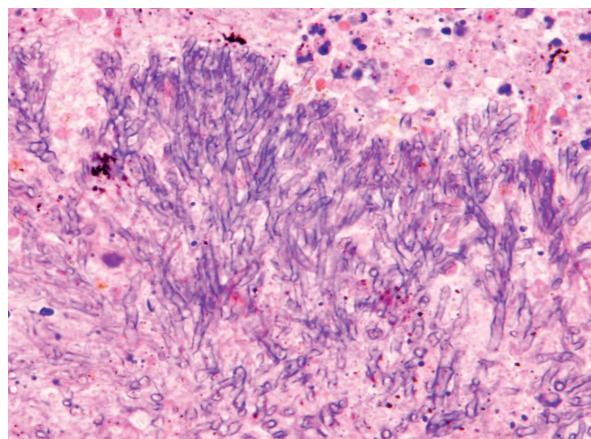


Figure 3. *Aspergillus* sp. in the right lung (haematoxylin-eosin staining, 800x magnification)

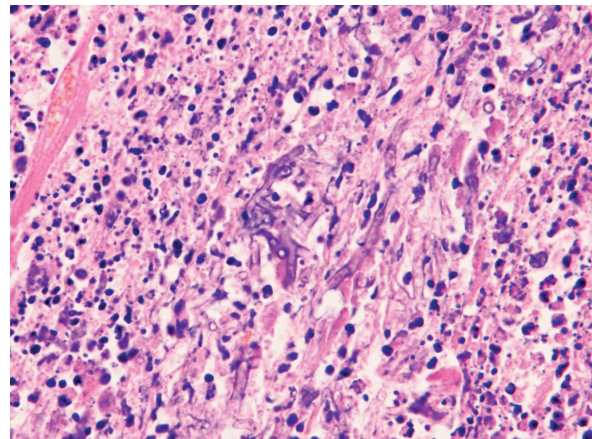


Figure 5. *Aspergillus* sp. in myocardium (haematoxylin-eosin staining, 800x magnification)

catheter, no yeasts or fungi were detected in any biological material.

At admission, vancomycin dosage was modified to 1 g/12 hours. For culture of *Klebsiella pneumoniae* ESBL+ from the exfoliated areas and *Morganella morganii* and *Escherichia coli* from the urinary system, meropenem at an initial dosage of 2 g/8 hours was also introduced for the patient. To isolate *Candida albicans* from the urinary system, the therapy was also supplemented with fluconazole at 400 mg/day. Administration of meropenem in the patient was extended to the third week of hospitalization because *Klebsiella pneumoniae* ESBL+ was also isolated from the lower respiratory tract and bloodstream. Due to cultures of multidrug-resistant *Pseudomonas aeruginosa* from various compartments, and because according to the antibiogram this pseudomonad is resistant to all available antibiotics except for colistin, colistin was introduced on the fourth week of hospitalization (2,000,000 IU/8 hours). In this period, *Proteus mirabilis* was also cultivated, but only from the permanent urinary catheter. This finding was resolved by replacing the catheter.

Histopathology

Metastatic renal cell carcinoma, bilateral pyelonephritis, and trachea-bronchitis were found during autopsy. The focus of abscessed mycotic bronchopneumonia was found in the upper lobe of the right lung (Fig. 3) and the focus of mycotic encephalitis in the right frontal lobe (Fig. 4). Mycotic myocarditis was also detected (Fig. 5). In all cases *Aspergillus* sp. was isolated.

DISCUSSION

In our case report, we present a rare case of a patient with a combination of malignancy and TEN. One would assume that patients with malignancy generally have a poorer prognosis. This is reflected also in the most versatile scoring scheme (SCORTEN) for patients with TEN, where the presence of any malignancy is burdened with a higher mortality rate.

Gravante et al. focused in their work on describing basic epidemiological data of patients with TEN and of TEN patients with a malignancy [7]. They compared 32 patients with histological confirmation of TEN, of which 9 patients were simultaneously diagnosed with a malignancy. Based on their results, the authors reached the interesting conclusion that patients with both TEN and malignancy were far more likely to develop infectious complications than were patients with TEN but without malignancy. Sepsis was identified in patients with TEN and malignancy in 77.7% of cases (7/9 patients), while in non-oncological patients it was identified in only 47.8% (11/23 patients). Similar results were obtained, however, when comparing isolations and targeted microbiological surveillance of exfoliated surfaces. Positive culture was recorded in 77.7% of oncological patients (7/9 patients) and in 74% of non-oncological patients (17/23 patients). Surprisingly, this fact was not reflected in the actual length of hospitalization or in mortality. The average length of hospitalization for oncological patients was 16.5 days and 2/9 patients died (22% mortality rate). In patients without malignancy, the average length of hospitalization was 16.8 days and 9/23 patients died (39% mortality rate).

A series of case statements describing the development of TEN in patients with breast cancer has been published. These detail the development of clinical symptoms of TEN induced by drugs targeted directly against tumours and supportive drugs. In their case report, Chia et al. described the development of TEN in a patient with breast cancer taking the non-steroid aromatase inhibitor letrozole [8]. Among supporting therapy drugs, anticonvulsants, which are used for protection in brain radiotherapy, are blamed in particular for the development of TEN. For example, Vincenzi et al. described precisely such a case when the patient took phenobarbital during radiotherapy of the brain and subsequently developed TEN [9]. Similar cases of severe bullous reaction were published at the turn of the millennium. Cockey et al. described the development of Stevens-Johnson syndrome (SJS) after radiotherapy in 1996, in which case the patient had developed SJS after taking phenytoin [10]. A similar case was documented by Eralp et al. in 2001 [11].

The literature has also described the development of SJS or TEN in patients treated for other types of malignancies. Ikeda et al. described a case in which SJS developed after administration of sorafenib for metastatic renal cell carcinoma [12]. Cases of TEN development in patients with non-small cell lung cancer after treatment with pemetrexed and cisplatin have also been reported, as have cases of TEN in patients with head and neck cancer or colon cancer after cetuximab therapy [13, 14, 15].

The presence of malignancy does not play an essential role in the context of mortality during the treatment period, mainly due to the short (about 2–3 weeks) length of this phase and the fact that today infectious complications play the dominant role in the mortality of patients with TEN. This assertion is supported by several factors. The first very important factor is the actual clinical manifestation – the development of skin (sometimes mucosal) exfoliations in various sizes. Even though there is a cutaneous “de-attachment” of the dermo-epidermal junction, and therefore the surface has the potential of complete spontaneous re-epithelialization, a merely local infection in exfoliated surfaces may deepen the defect itself and can stop the optimum phase process of wound healing. The only option then is to solve the definitive closure of the defect surgically, thus by auto-transplantation with skin grafts. This conversion further extends hospitalization and the increasing risk of developing infectious complications also raises the risk of mortality. Another important factor causing dramatic increase in the development of infectious complications in patients with TEN stems from immunosuppressive therapy. The most common potentially pathogenic microorganisms which play an important role in the development of infectious complications are Gram-positive bacteria (*Staphylococcus* sp., *Enterococcus* sp.) and particularly Gram-negative bacilli (e.g., *Pseudomonas aeruginosa*, *Enterobacter cloacae*, *Acinetobacter baumannii*, *Klebsiella pneumoniae*). Due to the nature of the patient and the disease, it is not surprising that yeasts, moulds and other opportunistic infectious agents also play a significant role in the development of infectious complications.

As already mentioned, infectious complications in patients with TEN are a frequent cause of mortality or lead to prolongation of hospitalization. Lee et al. describe a case of severe pneumonia caused by *Pneumocystis jiro-*

PŮVODNÍ PRÁCE

veci, parainfluenza virus type 3, cytomegalovirus and *Aspergillus fumigatus* in a patient with SJS/TEN overlap syndrome [16]. This syndrome differs from TEN particularly in the range of the lesions (in TEN 30% TBSA, in overlap TEN 10–30% TBSA). In this patient, clinical symptoms developed after using allopurinol. The patient was treated with a combination of intravenous immunoglobulin and corticosteroids. The authors suggest that the main reason for the development of pneumonia caused by some potentially pathogenic microorganisms may have been due in particular to corticosteroid use.

On the other hand, cases of TEN's development in patients with aspergillosis have also been described. Curigliano et al. reported cases wherein TEN developed during voriconazole therapy for pulmonary aspergillosis in patients after receiving chemotherapy [17].

In the presented patient, a total of 166 samples from various compartments were sent for microbiological examination during the hospitalization period. In all materials, culture was made also for yeasts and moulds. With the exception of a positive urinary culture from the first week of hospitalization, no micromycete was isolated from the patient. Nevertheless, there still was increased risk for the patient to develop a micromycetal infection (corticotherapy, antibiotic therapy). This risk, however, was not as high as, for example, in haemato-oncological patients or patients with sarcoidosis. In patients with TEN, we have always relied therefore on cultivation/microscopic examination in cases of micromycetal infections and used serological diagnostics only for monitoring the therapeutic effect of antimicrobials. Due to the development of nosocomial pneumonia, for which the multidrug-resistant *Pseudomonas aeruginosa* was repeatedly isolated, the symptoms of aspergillus infection were masked. Considering that no adequate response to the administered anti-infectives occurred and no fibrous fungus was detected by culture from any material, the dominant clinical symptomatology was assigned to the pseudomonads.

CONCLUSION

In our case report, we present a unique case of multi-pathogen and multifocal infection in a patient with renal cancer and TEN. Due to the character of the disease and the therapeutic approach, patients with TEN are at substantial risk of infection complications, including infections caused by micromycetes. Although there exists no general recommendation concerning serological diagnostics (detection of fungal antigens) in patients with TEN, the presented casuistry demonstrates that relying on only culture/microscopic detection can fail. Introduction of complementary serological diagnostics in patients with TEN is absolutely essential for precise microbiological surveillance.

REFERENCES

1. Paul C, Wolkenstein P, Adle H, et al. Apoptosis as a mechanism of keratinocyte death in toxic epidermal necrolysis. *Br J Dermatol*, 1996;134(4): 710–714.
2. Harry T, French LE. Toxic epidermal necrolysis and Steven-Johnson syndrome. *Orphanet J Rare Dis*, 2010;5: 39–50.
3. Chantaphakul H, Sanon T, Klaewsongkram J. Clinical characteris-

tics and treatment outcome of Stevens-Johnson syndrome and toxic epidermal necrolysis. *Exp Ther Med*, 2015;10(2): 519–524.

5. Schwartz RA, McDonough PH, Lee BW. Toxic epidermal necrolysis: Part I. Introduction, history, classification, clinical features, systemic manifestations, etiology, and immunopathogenesis. *J Am Acad Dermatol*, 2013;69(2): 173.e1–13; quiz 185–186.
5. Knight L, Muloiwa R, Dlamini S, et al. Factors associated with increased mortality in a predominantly HIV infected population with Stevens-Johnson syndrome and toxic epidermal necrolysis. *PLoS One*, 2014;9(4): e93543. doi: 10.1371 / journal.pone.0093543.
6. Bastuji Garin S, Fouchard N, Bertocchi M, et al. SCORTEN: and severity-of-illness score for toxic epidermal necrolysis. *J Invest Dermatol*, 2000;115(2): 149–153.
7. Gravano G, Delogu D, Marianetti M, et al. Toxic epidermal necrolysis and Steven-Johnson syndrome in oncologic patients. *Eur Rev Med Pharmacol Sci*, 2007;11(4): 269–274.
8. Chia WK, Lim YL, Greaves MW, et al. Toxic epidermal necrolysis in patient with breast cancer receiving letrozole. *Lancet Oncol*, 2006;7(2): 184–185.
9. Vincenzi B, Santini D, Grilli C, et al. Complications of therapy in cancer patients: Case 3. Toxic epidermal necrolysis induced by oral phenobarbital and whole-brain radiotherapy in a breast cancer patient. *J Clin Oncol*, 2004;22(22): 4649–4651.
10. Cockey GH, Amann ST, Reents SB, et al. Stevens-Johnson syndrome resulting from whole-brain radiation and phenytoin. *Am J Clin Oncol*, 1996;19(1): 32–34.
11. Eralp Y, Aydinler A, Taş F, et al. Stevens-Johnson syndrome in a patient receiving anticonvulsant therapy during cranial irradiation. *Am J Clin Oncol*, 2001;24(4): 347–350.
12. Ikeda M, Fujita T, Amoh Y, et al. Stevens-Johnson syndrome induced by cell sorafenib for metastatic renal carcinoma. *Urol Int*, 2013; 91(4): 482–483. doi: 10.1159 / 000351918th.
13. Then C, von Einem JC, Muller D, et al. Toxic epidermal necrolysis after pemetrexed cisplatin for and non-small cell lung cancer in a patient with sharp syndrome. *Oncology*, 2012;35(12): 783–786. doi: 10.1159 / 000345109th.
14. Lee SS, Chu PY. Toxic epidermal necrolysis caused by cetuximab plus minocycline in head and neck cancer. *Am J Otolaryngol*, 2010;31(4): 288–290. doi: 10.1016 / j.amjoto.2009.02.021
15. Lin WL, Lin WC, Yang JY, et al. Fatal toxic epidermal necrolysis associated with cetuximab in a patient with colon cancer. *J Clin Oncol*, 2008;26(16): 2779–2780. doi: 10.1200 / JCO.2007.15.7883.
16. Lee T, Bae YJ, Park SK, et al. Severe pneumonia caused by combined infection with *Pneumocystis jiroveci*, parainfluenza virus type 3, cytomegalovirus, and *Aspergillus fumigatus* in a patient with Stevens-Johnson syndrome / toxic epidermal necrolysis. *Acta Derm Venereol*, 2010;90(6): 625–629. doi: 10.2340 / 00015555-0977.
17. Curigliano G, Formica V, De Pas T, et al. Life threatening toxic epidermal necrolysis during voriconazole therapy for invasive aspergillosis after chemotherapy. *Ann Oncol*, 2006;17(7): 1174–1175.

Do redakce došlo dne 10. 9. 2016.

Adresa pro korespondenci:

MUDr. Břetislav Lipový, Ph.D.

Klinika popálenin a rekonstrukční chirurgie FN Brno
Jihlavská 20
625 00 Brno
e-mail: b.lipovy@seznam.cz