

TWO-YEAR FOLLOW-UP RESULTS OF PATIENTS WITH MACULAR EDEMA DUE TO RETINAL VEIN OCCLUSION TREATED WITH RANIBIZUMAB

Hladíková Z., Klofáčová E., Kalvodová B.

Department of Ophthalmology, 1st Faculty of Medicine, Charles University and General University Hospital, Prague, Head: doc. MUDr. Jarmila Heissigerová, Ph.D., MBA

The results were presented at the 18th annual Vejdovský Science Day in Olomouc on 1 April 2017

The authors of the study declare that no conflict of interest exists in the compilation, theme and subsequent publication of this professional communication, and that it is not supported by any pharmaceuticals company.



MUDr. Zuzana Hladíková
Oční klinika, 1. LF UK a VFN v Praze
U Nemocnice 2
128 08 Praha 2
e-mail: zuzana.hladikova@vfn.cz

SUMMARY

Purpose: To evaluate 2-year follow-up results of patients with macular oedema (ME) caused by central (CRVO) and branch (BRVO) retinal vein occlusion treated with intravitreal ranibizumab at the Department of Ophthalmology, First Faculty of Medicine, Charles University and General University Hospital in Prague, Czech Republic.

Methods: Retrospective study.

Results: The 2-year follow-up was completed by 18 patients with ME caused by CRVO and 16 patients with ME caused by BRVO. In CRVO group mean age at diagnosis was 63 years, mean interval from diagnosis to the beginning of treatment was 3,6 months. During the first year of treatment the mean improvement of best corrected visual acuity (BCVA) was 17,4 letters of Early Treatment Diabetic Retinopathy Study (ETDRS) optotype, during the second year +2,4 letters. Mean number of injections was 6,8 in the first and 3,6 in the second year of treatment, mean total of 10,2 injections. In BRVO group the mean age at diagnosis was 68 years, mean interval from diagnosis to the beginning of treatment 6 month, mean gain in BCVA was +18,7 letters in the first and +1 letters in the second year of treatment, mean number of injections was 7 and 3,2 respectively, mean total of 9,6 injections. In both groups neither ocular nor systemic serious adverse effects were noted.

Conclusion: According to our results intravitreal ranibizumab is a safe and effective treatment for ME caused by retinal vein occlusion. Our results in BRVO group were in accordance with published international studies – BRAVO (BRVO) +18,3 letters, HORIZON -0,7 and even slightly better in CRVO group - CRUISE (CRVO) +13,9 letters, HORIZON study -4,1 letters

Key words: macular oedema, ranibizumab, retinal vein occlusion, central retinal vein occlusion, branch retinal vein occlusion, 2-year follow-up

Čes. a slov. Oftal., 73, 2017, No. 2, p. 43–51

INTRODUCTION

1.1 Basic terms and distinction of retinal vein occlusion

After diabetic retinopathy, retinal vein occlusion (RVO) is the second most common vascular pathology of the retina (12). From an anatomical perspective it is divided into branch retinal vein occlusion (BRVO), central retinal vein occlusion (CRVO) and hemiretinal vein occlusion, which results in the affliction only of the upper or lower half of the retina. Hemiretinal vein occlusion is considered a variant of CRVO (hemi CRVO) (1).

1.2 Etiopathogenesis and clinical manifestations

Obstruction of the blood flow of the vein occurs due to the formation of a thrombus in its lumen, most frequently in the place of pressure by an atherosclerotically altered artery (20). In patients with CRVO this occurs in the region of the lamina cribrosa, in patients with BRVO in the place of the crossing of the vein and the artery, where both vessels have a common adventitia (19). Further possible causes may be exterior compression of a different etiology, or a pathology of the vascular wall (e.g. in the case of vasculitis) (20).

1.3 Prevalence

In 2010 an extensive study was published, summarising the results of population studies from the USA, Europe, Asia and Australia. It concerned data on a total of 68751 persons from 15 studies. The prevalence of RVO in this group was 5.2/1000, CRVO 0.8/1000 and BRVO 4.42/1000 (17).

1.4 Risk factors

Upon the occurrence of RVO, a very important role is played by systemic risk factors. The most frequently stated is higher age (11, 13, 16, 17) and also systemic pathologies such as arterial hypertension (11, 26), diabetes mellitus (DM) (11, 26), hyperlipidaemia and hypercholesterolaemia (6), conditions connected with hyperviscosity of blood and disorders of the coagulation cascade, which include deficit of protein C and S, antithrombin, hyperprothrombenaemia or Leiden mutation (19). Of the ocular risk factors the most frequently stated is open-angle glaucoma (13, 26).

1.5 Prognosis

Significant prognostic factors are initial visual acuity (22, 23) and the degree of retinal perfusion. In patients with ischaemic form of CRVO, the prognosis is markedly worse than in patients with non-ischaemic form.

1.6 Complications

The most frequent complications of RVO are the occurrence of macular edema (ME) and ischaemia of the retina, leading to the occurrence of neovascularisation (NV) of the anterior (iris and chamber angle) and posterior (neovascularisation of the disc of the optic nerve and retina) segment of the eye (20). A key role in the occurrence of ME is played especially by high intracapillary pressure and also by the release of a range of angiogenic and inflammatory factors such as vascular endothelial growth factor (VEGF) and interleukin 6 (IL6) (14, 18).

1.7 Treatment

1.7.1 Laser coagulation of the retina

For many years, the gold standard in treatment was laser coagulation of the retina. The Central Vein Occlusion Study Group (CVOS) did not demonstrate an improvement of best corrected visual acuity (BCVA) in patients in the case of CRVO treated with grid laser coagulation of the macula, and does not recommend the performance of this procedure on these patients (24). This group further examined the influence of preventive performance of panretinal photocoagulation (PRP) of the retina on the development of NV of the anterior segment of the eye, and came to the conclusion that prophylactic PRP did not prevent the development of NV of the iris and chamber angle in all patients. The performance of PRP is thus recommended only after the discovery of these NV (25).

The effectiveness of grid laser coagulation of the macula in patients with ME upon BRVO was investigated by the Branch Vein Occlusion Study Group (BVOS). In 1984 this group published data which showed that during the course of the years 65% of these patients (28 out of 43) treated with grid laser coagulation of the retina gained 2 or more rows of BCVA in comparison with only 37% (13 out of 35) of patients in the group which was only observed (22).

1.8 Medicamentous treatment – intravitreal preparations

The introduction of intravitreal preparations into the treatment of ME due to RVO substantially improved the prognosis of this pathology.

1.8.1 Corticosteroids

Of the group of corticosteroids, at present a biodegradable implant containing dexamethasone in a dose of 0.7 mg (Ozurdex, Allergan) is used. The effectiveness and safety of use of this implant in patients with ME due to CRVO and BRVO was examined by the GENEVA study (7). The main adverse effects are increase of intraocular pressure (IOP) and progression of cataract (in 29.8% of phakic eyes following two applications of biodegradable implant with dexametha-

sone in a dose of 0.7 mg).

The use of this preparation in the Czech Republic is limited by the restriction on coverage to only 2 biodegradable implants with dexamethasone 0.7 mg into each eye per one episode of ME due to RVO (10). For a range of patients, this quantity is not sufficient (21).

1.8.2 Ranibizumab

Ranibizumab (Lucentis, Novartis) is a fragment of humanised monoclonal antibody, which bonds selectively and neutralises all isoforms of VEGF-A. It is used in a dose of 0.5mg/0.05 ml in one intravitreal injection, the interval between individual applications should be no shorter than 4 weeks. The effectiveness and safety of ranibizumab in the first year of treatment of ME due to CRVO was observed by the CRUISE study (3), in the case of BRVO by the BRAVO study (2). These studies were followed on from by the studies HORIZON (2nd year of treatment) (8) and RETAIN, with an average observation period of 49 months (4). The unfavourable finding of the RETAIN study was that ME was permanently reabsorbed during the course of observation only in 44% (14 out of 32) patients with ME due to CRVO (of whom this took place in 71% during the course of the first two years of treatment) and in 50% of patients (17 out of 34) with ME due to BRVO (of whom this took place in 76% during the course of the first two years of treatment). The persistence of ME in both groups was linked with a worse resulting visual acuity.

1.8.3 Aflibercept

Aflibercept (Eylea, Bayer) is a fusion protein composed of fragments of extracellular domains of human VEGF receptors 1 and 2 fused to an Fc fragment of human IgG1. Aflibercept binds VEGF A, VEGF B and placental growth factor. In the treatment of ME due to CRVO it is used intravitreally in a dose of 2mg/0.05ml, the interval between two doses should be no shorter than one month.

The effectiveness and safety of intravitreally administered aflibercept in the treatment of ME due to CRVO was evaluated by two studies – COPERNICUS (in the USA, Canada, Columbia, India and Israel) and GALILEO (in Europe and South East Asia) (9, 19). The effectiveness of intravitreally administered aflibercept in comparison with grid laser coagulation of the macula in patients with ME due to BRVO was examined by the VIBRANT study (5).

The aim of this study is to retrospectively evaluate the results of two year intravitreal treatment by ranibizumab in a dose of 0.5 mg in patients with ME due to CRVO and BRVO at the Department of Ophthalmology at the General University Hospital in Prague and the 1st Faculty of Medicine of Charles University.

METHODOLOGY

The data on the patients was obtained from the medical documentation of our clinic. In the patients we observed age upon determination of the diagnosis of ME due to RVO, sex, presence of risk factors, interval between the origin of ME and the commencement of treatment, type of RVO,

state of perfusion of the retina according to fluorescence angiography (FAG), presence of NV of anterior and posterior segment of the eye upon commencement and during the course of treatment, initial BCVA and central retinal thickness (CRT) and their development during the course of treatment, and the number of applications of ranibizumab. BCVA was examined on ETDRS optotypes.

The treatment was commenced on patients who met the restriction of coverage of the preparation, i.e. those in whom BCVA had deteriorated due to the influence of ME caused by RVO, in which the changes in the macula were not of an irreversible character and were resistant to laser therapy, BCVA was within the range of 6/120 and 6/12, CRT was $> 250\mu\text{m}$ and the duration of ME was < 12 months. For all patients, before the commencement of treatment we required compensation of general condition (especially DM, arterial hypertension, dyslipidemia etc.) by a general practitioner or internal specialist. The exclusion criterion was myocardial infarction (MI) or stroke in the last 3 months. A condition for commencement of treatment was also compensated IOP. In each patient only one eye was treated in all cases.

Treatment was commenced by applications of ranibizumab intravitreally every 4 weeks until stabilisation was achieved, i.e. stable BCVA and CRT at three consecutive visits. Afterwards the patients were observed at an interval of 4 weeks. For patients in whom long-term stable results were achieved, the intervals of the follow-up examinations were subsequently individually extended. For the purposes of evaluating the results, values from the previous follow-up examination were used in these cases. Applications were recommenced in the case that BCVA deteriorated and/or we recorded an increase of CRT, and thus a relapse of ME. In these cases we again applied ranibizumab at an interval of 4 weeks until stabilisation was achieved. At each follow-up examination, independently of whether or not application was indicated, measurement of IOP was conducted with a non-contact tonometer, as well as examination of BCVA, biomicroscopical examination of the anterior segment, examination of the posterior segment in artificial mydriasis and optical coherence tomography (OCT) using a Spectralis instrument by the company Heidelberg Engineering. During the course of the first three months of treatment, FAG was performed on all patients. We repeated this examination after one year. According to FAG we performed laser treatment of the area of non-perfusion and infiltration, in patients with ME due to BRVO we performed focal or grid laser coagulation of the macula.

RESULTS

4.1 CRVO

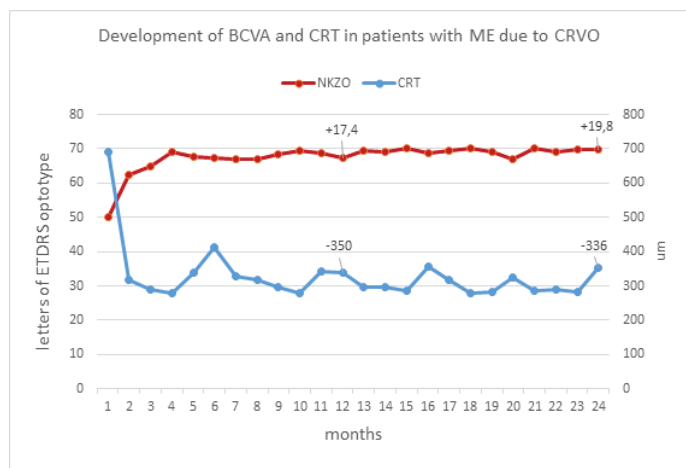
Two year observation was completed by a total of 18 patients (11 men and 7 women) treated with ranibizumab. The average age of the patients upon determination of the diagnosis of ME was 63 years (23-81). The most commonly occurring systemic risk factor was arterial hypertension, which was present in 13 out of 18 patients (72%), followed by dyslipidemia (in 7 out of 18, 39%) and DM (in 6 out of

18, 33%). One patient suffered from chronic atrial fibrillation, thrombophilic mutations were not diagnosed in any of the patients. The incidence of open angle glaucoma was relatively high among our patients, in 9 out of 18 (50%). The average interval between the origin of ME and the commencement of treatment was 3.6 months (median 2.5 months, range 1-11). On the basis of FAG performed during the course of the first three months, we evaluated CRVO as ischaemic in three patients. In two of these we performed PRF due to the presence of NV, in the remaining patient only targeted treatment of the area of non-perfusion according to FAG was performed. In one patient a conversion from non-ischaemic to ischaemic form of CRVO took place during the first year of treatment, due to the development of NV of the retina we performed PRF. In the remaining 14 patients we evaluated CRVO as non-ischaemic. Average initial BCVA was 49.9 letters of ETDRS optotype, average initial CRT was $690\mu\text{m}$. After the first year of treatment, average BCVA increased to 67.3 letters of ETDRS optotype (+17.4 letters), and CRT was reduced to $340\mu\text{m}$. After the second year of treatment BCVA improved to 69.7 letters of ETDRS optotype (+19.8 letters from the initial values, +2.4 for the second year of treatment), and average CRT was $354\mu\text{m}$ ($-336\mu\text{m}$ since the beginning of treatment, +14 μm for the second year). Twelve patients out of 18 (67%) gained > 15 letters of ETDRS optotype, none of our patients lost $>$ letters of ETDRS optotype – the worst result was -10 letters. In 9 patients (50%) complete regression of ME was achieved during the course of treatment, which means that these patients were without symptoms of ME on OCT images 6 and more months before the end of the two year observation.

During the course of two years we applied an average of 10.2 injections to patients (median 10, total 3-20), of which on average 6.8 in the first year of treatment (median 7, total 3-12) and 3.6 (median 2.5, total 0-10) in the second year. NV of the anterior and posterior segment was present in two patients at the beginning of treatment, in one patient NV of the retina appeared during the course of treatment. In all three patients NV regressed after the performance of PRF and intravitreal therapy of ME with ranibizumab. During the course of treatment we did not record any serious ocular or general adverse effects.

4.2 BRVO

Two year observation was completed by a total of 16 patients – 11 men and 5 women. The average age of the patients upon determination of the diagnosis of ME was 68 years (43-85). The most commonly occurring systemic risk factor was arterial hypertension, which was present in 14 out of 16 patients (88%), followed by dyslipidemia (in 7 out of 16, 44%) and DM (in 4 out of 16, 25%). Two patients had previously suffered from a stroke, one from MI. In one patient, during the course of the internal examination before the commencement of treatment with ranibizumab, a thrombophilic mutation was diagnosed, specifically a mutation of factor II (prothrombin) in heterozygote form. The incidence of open angle glaucoma was lower than in the patients with CRVO – only 3 out of 16 patients (19%). The



Graph 1

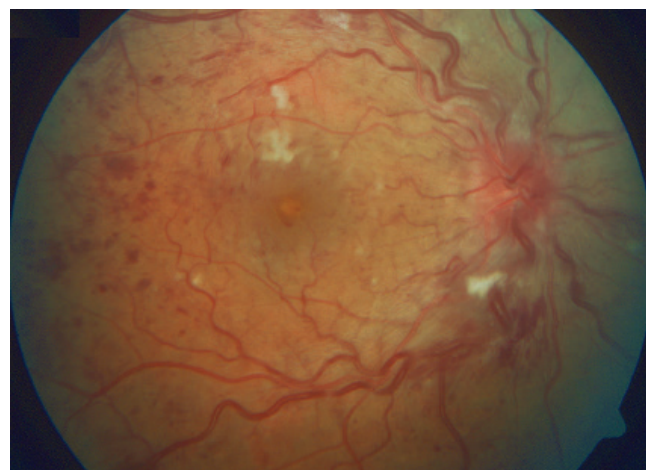


Fig. 1 Patient – man, born 1965, initial BCVA was 60 letters of ETRS optotype, CRT 699 μm.

Condition before commencement of treatment – CRVO with edema and congestion of disc of optic nerve, dilatation and tortuosity of retinal veins, presence of flame-shaped and blot-shaped retinal haemorrhages, soft exudates and macular edema

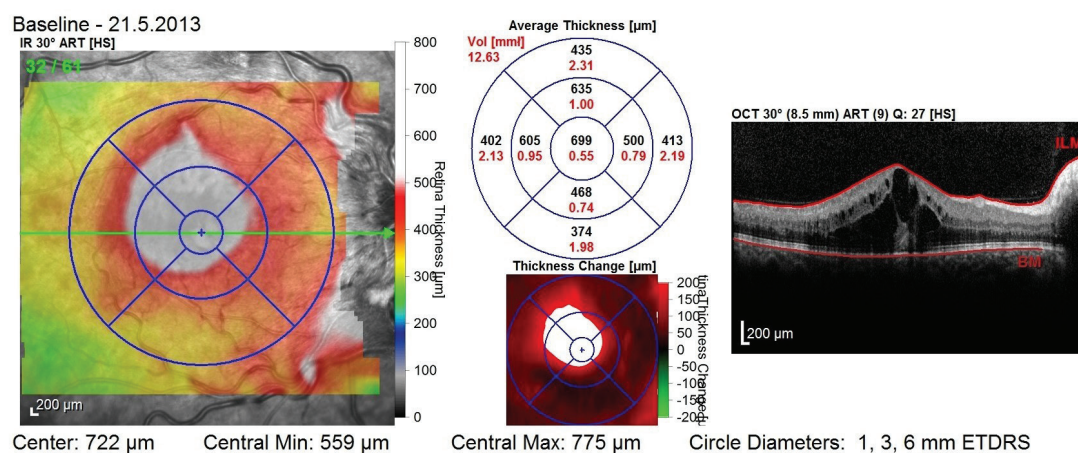


Fig. 2 OCT image before commencement of treatment – presence of cystoid macular edema

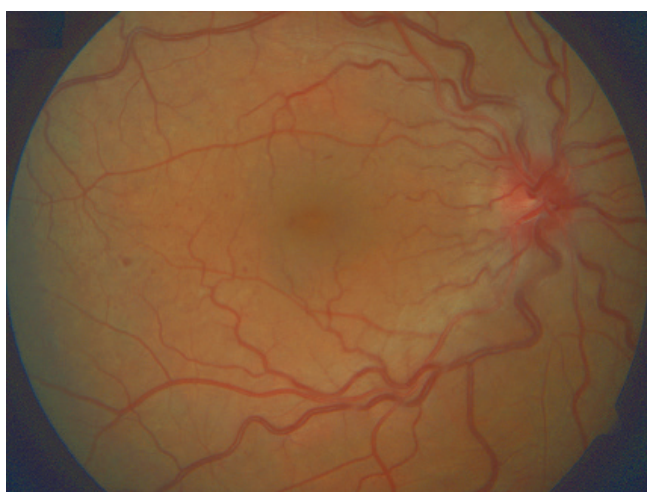

Fig. 3 Condition after 1 year of treatment – persistence of mild congestion of disc of optic nerve and dilated, tortuous veins, significant regression of retinal haemorrhage, soft exudates and ME had occurred

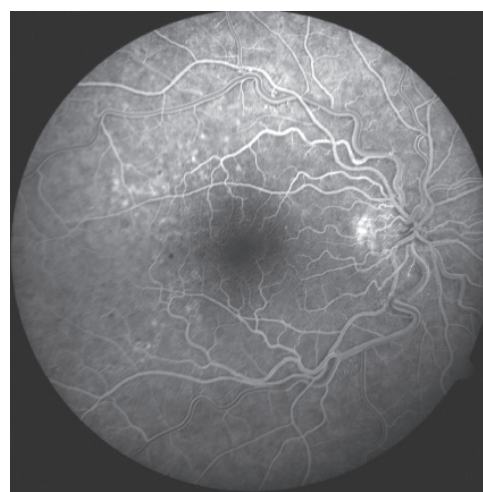


Fig. 4 FAG after 1 year of treatment demonstrates infiltration of colouring from dilated capillaries, especially in upper temporal quadrant in region of posterior pole

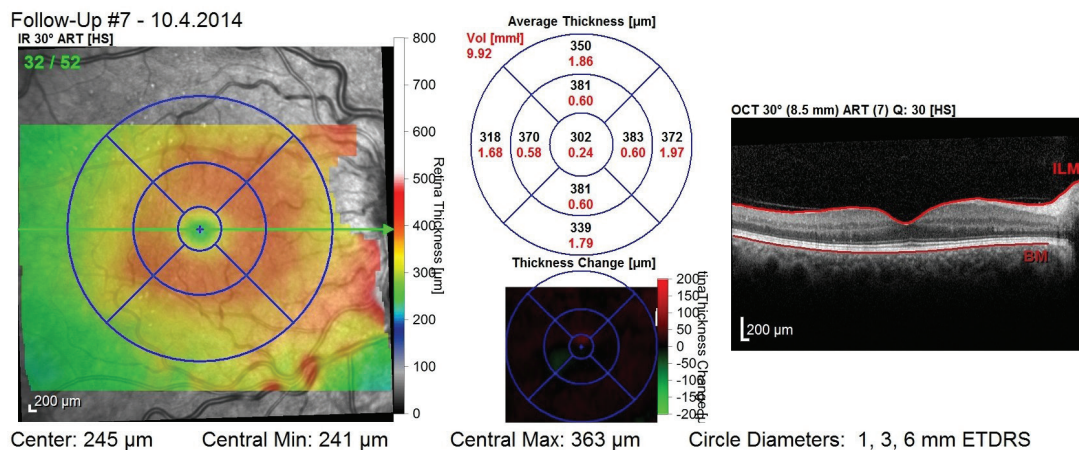


Fig. 5 OCT image after 1 year of treatment (total 5 applications) – regression of ME, good morphology of outer layers of neuroretina, CRT 302 μm and BCVA 81 letters of ETDRS optotype

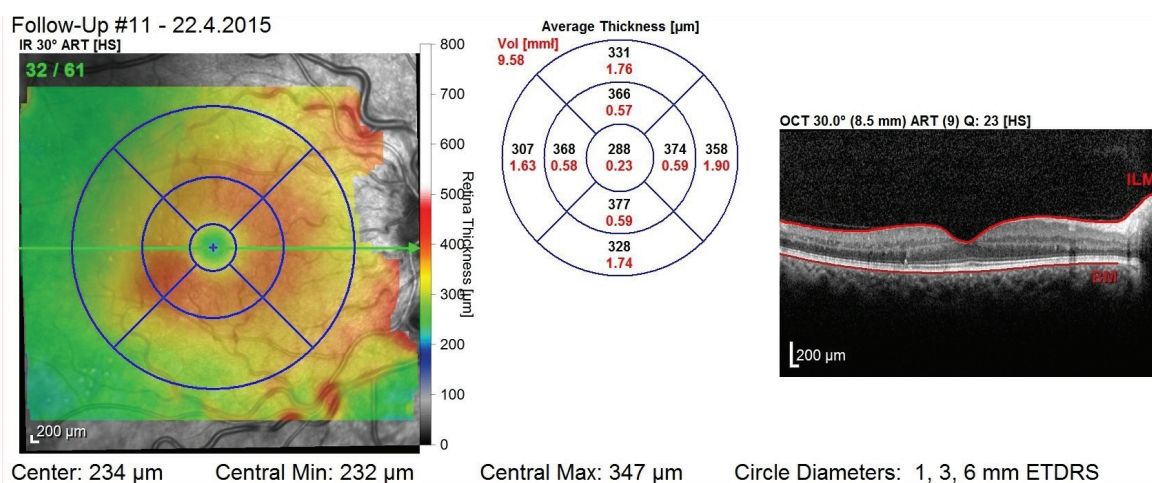
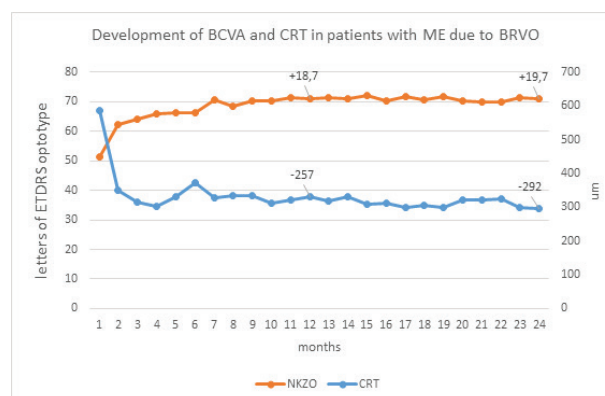


Fig. 6 OCT image after 2 years – even without application during 2nd year of treatment, stable finding persists without symptoms of ME, with good morphology of outer layers of neuroretina, CRT 288 μm and BCVA 85 letters of ETDRS optotype

average and median interval between the origin of ME and the commencement of treatment was 6 months (2 weeks to 11 months). Average initial BCVA was 51.4 letters of ETDRS optotype and average initial CRT was 588 μm. After the first year of treatment, average BCVA increased to 70.1 letters of ETDRS optotype (+18.7 letters), and CRT was reduced to 331 μm (-257 μm). After the second year of treatment BCVA improved to 71.1 letters of ETDRS optotype (+19.7 letters from the initial values, +1 for the second year of treatment), and average CRT was 296 μm (-292 μm since the beginning of treatment, -35 μm for the second year). In 7 patients (44%) complete regression of ME was achieved during the course of treatment, which means that these patients were without symptoms of ME on OCT images 6 and more months before the end of the two year observation. In the case of one patient from this group, this nevertheless concerned an atrophy of the macula (CRT 119 μm after 3 initial applications), with unsatisfactory visual acuity.

During the course of two years we applied an average of 9.6 (median 8.5, total 3-22), of which on average 7 in the



Graph 2

first year of treatment (median 7, total 3-12) and an average of 3.2 (median 2, total 0-10) in the second year. During the course of treatment, similarly to the patients with ME due to CRVO, we did not record any serious ocular or systemic adverse effects. NV did not appear in any of the patients

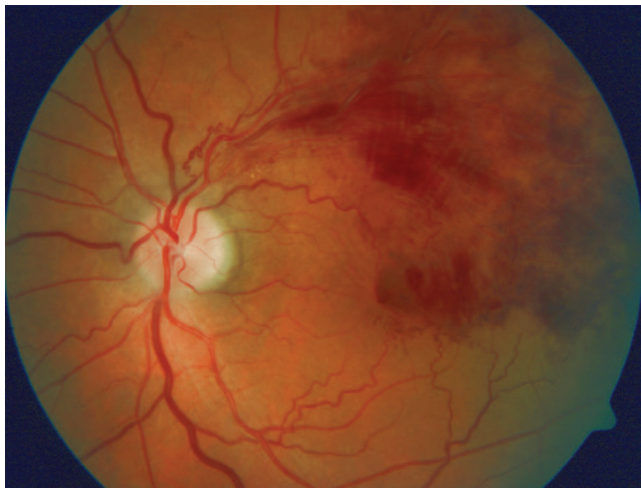


Fig. 7 Patient – man, born 1950, initial BCVA 62 letters of ETDRS optotype and CRT 603 μm

DISCUSSION

At present anti-VEGF therapy is the method of first choice for patients with ME due to RVO. Its introduction into clinical practice led to a marked improvement in the prognosis of this pathology. In our cohort of patients with ME due to RVO we intended to verify the safety and effectiveness of intravitreal treatment using ranibizumab, and to compare our results with the results of international clinical trials.

Although our cohort is relatively small, in its composition it corresponds to the cohorts of the aforementioned studies. Similarly to these studies, the average age of our patient was over 60 years – in the group of CRVO 63 years (range 23-81) in comparison with 68 years in the CRUISE study (20-91 years) (3), in the BRVO group 68 years (43-85) in comparison with 66 years (3) in the BRAVO study (26-91) (2).

In our group also a slight predominance of affliction of men was confirmed – 61% (11 out of 18) in the CRVO group in comparison with 57% in the CRUISE study (3) and 69% (11 out of 16) in the BRVO group in comparison with 53% in the BRAVO study (2).

In co-operation with outpatient ophthalmologists and diagnostic centres, in the CRVO we succeeded in attaining similarly timely commencement of treatment as was

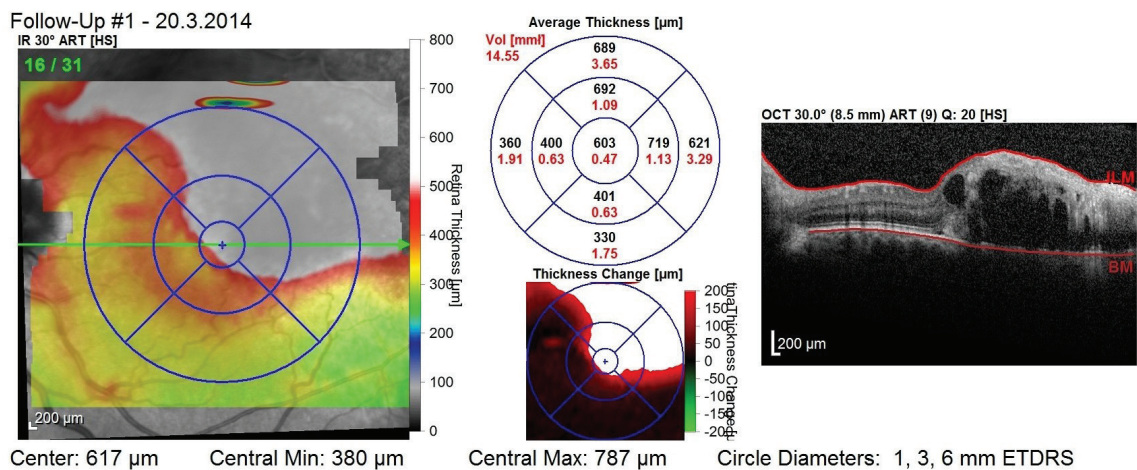


Fig. 8 OCT image before commencement of treatment – presence of cystoid macular edema

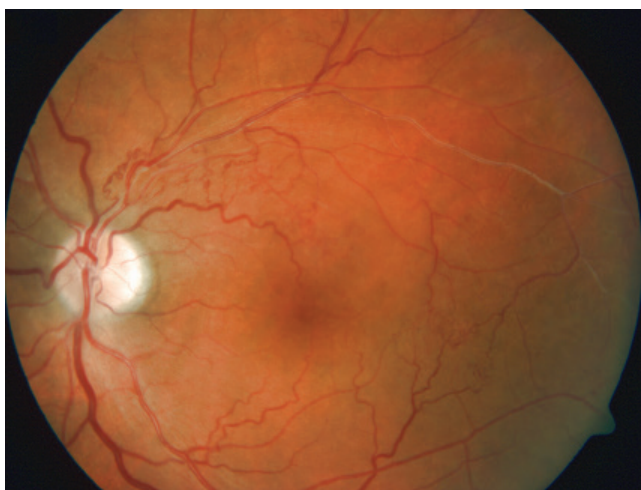

Fig. 9 Condition after 1 year of treatment, significant regression of haemorrhages and ME achieved, evident presence of collateral in treated area

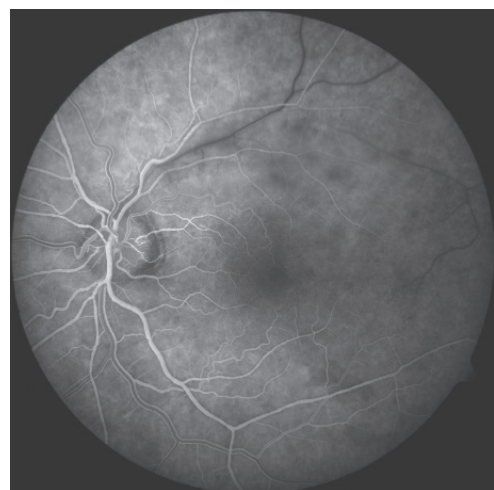

Fig. 10 FAG after 1 year of treatment – in the arteriovenous phase there is evident delayed filling of the vein peripherally from the closure and presence of collateral

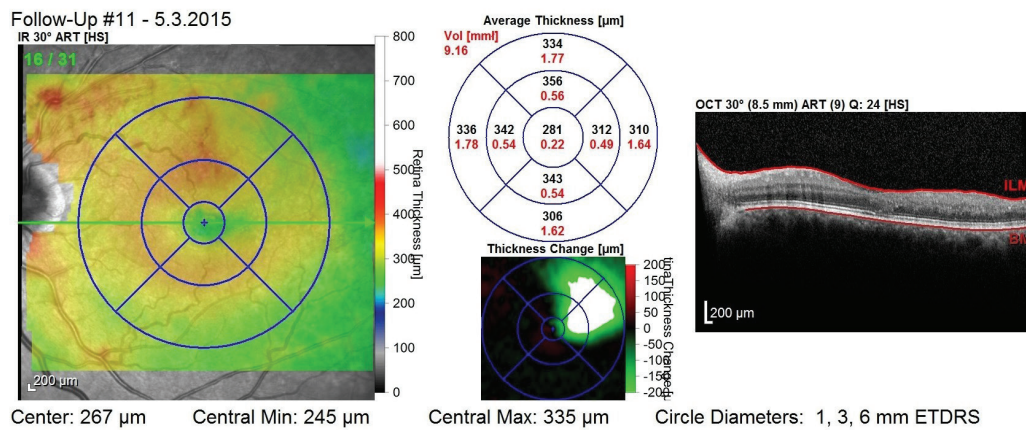


Fig. 11 OCT image after 1 year of treatment (9 applications) – without symptoms of ME, slight disorganisation of outer layers of neuroretina, CRT 281 μm and BCVA 85 letters of ETDRS optotype

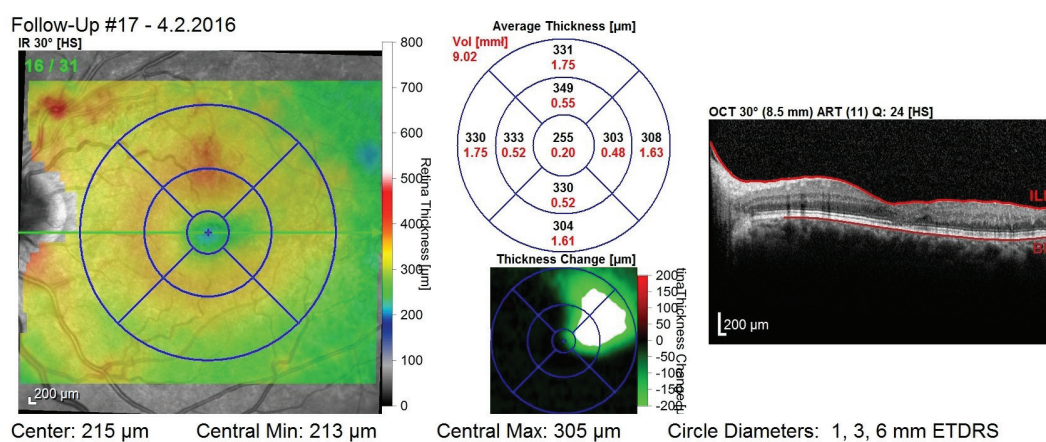


Fig. 12 OCT image after 2 years of treatment (6 applications administered during 2nd year of treatment) – without symptoms of ME, slight disorganisation of outer layers of neuroretina, CRT 255 μm and BCVA 80 letters of ETDRS

attained in the CRUISE study – the average interval between the origin of ME and the commencement of treatment in our patients was 3.6 months, median 2.5 months, in the CRUISE study 3.3 months, median 2 months (3). In the group of patients with ME due to BRVO, in our cohort treatment was commenced somewhat later – the average and median interval between the origin of ME and the commencement of treatment was 6 months in comparison with an average of 3.5 months and median of 2 months in the BRAVO study (2). We explain the later commencement of treatment of patients with ME due to BRVO with reference to the fact that the decrease of BCVA in this group may be slower, as a result of which upon binocular vision patients may become aware of this later.

The initial functional and anatomical parameters of our patients were also very similar to those in the compared studies – average BCVA in our cohort was 49.9 letters of ETDRS optotype in the group of patients with CRVO, and average initial CRT was 690 μm, in the CRUISE study 48.3 letters and 685 μm (3). In the group of patients with ME due to BRVO, average initial BCVA was 51.4 letters of ETDRS optotype and average initial CRT was 588 μm, in the BRAVO study 54.6

letters and 521 μm (2).

In the group of patients with ME due to BRVO we achieved similar functional results as were achieved in the compared clinical trials (2, 8). In the group of patients with ME due to CRVO our results are slightly better (3). At the end of the first year of treatment, the average gain in the group of patients with ME due to CRVO was 17.4 letters of ETDRS optotype, and CRT was reduced by 350 μm upon an average of 6.8 injections per patient. In the CRUISE study patients attained an improvement of 13.9 letters of ETDRS optotype and a reduction of 461 μm upon 8.8 injections (3). We attribute the better anatomical effect achieved in the CRUISE study to the higher number of injections administered in the first year of treatment, and especially to the monthly dosing in the first 6 months. The results for the second year of treatment in our cohort were a gain of 2.4 letters of ETDRS optotype and an increase of CRT by 14 μm upon an average of 3.6 injections, in comparison with the HORIZON study, in which at the end of the second year of treatment BCVA deteriorated by 4.1 letters of ETDRS optotype and CRT increased by 68.4 μm upon 3.5 injections (8). We assume that the better results of our patients during the course of

the second year of treatment may be caused both by the small size of the group and also by the fact that we transferred a number of patients to another treatment due to their insufficient response to treatment or tachyphylaxis before the end of the two year period, as a result of which they were not included within this cohort.

The results in the group of patients with ME due to BRVO were +18.7 letters and -257 μm at the end of the first year upon an average of 7 injections per patient, in comparison with +18.3 letters and -347 μm upon an average of 8.4 injections in the BRAVO study (2), in the second year of treatment +1 letter and -35 μm upon 3.2 injections in comparison with -0.7 letters and +35.3 μm upon 2.1 injections in the HORIZON study (8). Again we attribute the worse anatomical result of our patients in the first year, and contrastingly the slightly better result in the second year to the difference in the number of administered injections.

In accordance with the results of the clinical trials, in our cohort also it was demonstrated that the initial substantial improvement in BCVA and the reduction of CRT achieved in the early applications during the course of the first year can be maintained in the majority of patients even upon a reduction of the number of applications in transition to a regime of PRN or Treat and Extend in the further observation. On the other hand it is evident that although frequent applications of ranibizumab eliminate the influence of VEGF-A and cause a reduction of ME, they do not lead to a suppression of its production, and as a result some patients require a short interval between applications in order to maintain good functional results – accordingly in both groups of patients the highest number of applications in the first year was 12 (range 3-12) and in the second year 10 (range 0-10).

The end functional result is dependent not only on the degree of regression of ME, but the degree of ischaemia of the macula and changes of the morphology of the outer layers

of the neuroretina are of fundamental significance. Therefore, in our cohort also there were patients in whom resulting BCVA was unsatisfactory despite the elimination of ME, due to the above-described changes.

In clinical trials with anti-VEGF preparations, whether this concerns studies with ranibizumab or aflibercept, in a comparison of the results of treated groups and groups which received only a placebo from the outset, the necessity of timely commencement of anti-VEGF treatment was emphasised in order to achieve the maximum functional effect. In our cohort, with regard to its size, it was not possible to conduct a comparison of patients on whom treatment had been commenced in a timely manner with patients on whom treatment was commenced later. However, clinical practice leads us to the same conclusion.

CONCLUSION

The results of our cohort confirm the effectiveness and safety of intravitreal treatment with ranibizumab in patients with ME due to RVO. More than 15 letters of ETDRS optotype were gained by 12 out of a total of 18 patients (67%) with ME due to CRVO, and by 10 out of 16 (63%) patients with BRVO. None of our patients lost > 15 letters of ETDRS optotype after 2 years of observation. These results correspond to the results of published clinical trials (2, 3, 8) and demonstrate their usability in regular practice.

Therapy using anti-VEGF preparations is indisputably beneficial for patients with ME due to RVO. However, its disadvantages include the necessity of frequent follow-up examinations, most preferably at monthly intervals, which places a burden both on patients and on application centres, as well as the fact that according to the results of the RETAIN study (4), practically one half of patients require long-term treatment.

LITERATURE

1. **Bowling, B.:** Kanski's Clinical Ophthalmology: A Systemic Approach, Eighth edition, Edinburgh, Elsevier, 2016, p. 539–44.
2. **Brown, D.M., Campochiaro, P.A., Bhisitkul, R.B. et al.:** Sustained Benefits from Ranibizumab for Macular Edema Following Branch Retinal Vein Occlusion: 12-Month Outcomes of a Phase III Study. *Ophthalmology*, 118, 2011: 1594–1602.
3. **Campochiaro, P.A., Brown, D.M., Awh C.C. et al.:** Sustained Benefits from Ranibizumab for Macular Edema following Central Retinal Vein Occlusion: Twelve-Month Outcomes of a Phase III Study. *Ophthalmology*, 118, 2011: 2041–49.
4. **Campochiaro, P.A., Sophie, R., Pearlman, J. et al.:** Long-term Outcomes in Patients with Retinal Vein Occlusion Treated with Ranibizumab The RETAIN Study. *Ophthalmology*, 121, 2014: 209–19.
5. **Clark, W.L., Boyer, D.S., Heier, J.S. et al.:** Intravitreal Aflibercept for Macular Edema Following Branch Retinal Vein Occlusion 52-Week Results of the VIBRANT Study. *Ophthalmology*, 123, 2016: 330–36.
6. **Dodson, P.M., Galton, D.J., Hamilton, A.M. et al.:** Retinal vein occlusion and the prevalence of lipoprotein abnormalities. *Br J Ophthalmol*, 66, 1982: 161–64.
7. **Haller, J.A., Bandello, F., Belfort, R. Jr. et al.:** Dexamethasone Intravitreal Implant in Patients with Macular Edema Related to Branch or Central Retinal Vein Occlusion Twelve-Month Study Results. *Ophthalmology*, 118, 2011: 2453–2460.
8. **Heier, J.S., Campochiaro, P.A., Yau, L. et al.:** Ranibizumab for Macular Edema Due to Retinal Vein Occlusions Long-term Follow-up in the HORIZON Trial. *Ophthalmology*, 119, 2012: 802–809.
9. **Heier, J.S., Clark, W.L., Boyer, D.S. et al.:** Intravitreal Aflibercept Injection for Macular Edema Due to Central Retinal Vein Occlusion: Two-Year Results from the COPENICUS Study. *Ophthalmology*, 121, 2014: 1414–1420.
10. <http://www.sukl.cz/modules/medication/detail.php?code=0167756&tab=prices>
11. **Klein, R., Klein, B.E.K., Moss, S.E. et al.:** The Epidemiology of Retinal Vein Occlusion: The Beaver Dam Eye Study. *Tr. Am. Ophth. Soc.*, 98, 2000: 133–143.
12. **Kuchynka, P.:** Oční lékařství, Praha, Grada Publishing, 2007, 291 s.
13. **Mitchell, P., Smith, W., Chang, A.:** Prevalence and associations of retinal vein occlusion in Australia. The Blue Mountains Eye Study. *Arch Ophthalmol*, 114, 1996: 1243–1247
14. **Noma, H., Funatsu, H., Mimura, T. et al.:** Aqueous humor levels of vasoactive molecules correlate with vitreous levels and macular edema in central retinal

- vein occlusion. *Eur J Ophthalmol*, 20, 2010: 402–409.
15. **Ogura, Y., Roider, J., Korobelnik, J. F. et al.:** Intravitreal Aflibercept for Macular Edema Secondary to Central Retinal Vein occlusion: 18-Month Results of the Phase 3 GALILEO Study. See comment in PubMed Commons below *Am J Ophthalmol*, 158, 2014: 1032–1038.
 16. **Ponto, K.A., Elbaz, H., Peto, T. et al.:** Prevalence and risk factors of retinal vein occlusion: the Gutenberg Health Study. *J Thromb Haemost*, 13, 2015: 1254–1263.
 17. **Rogers, S., McIntosh, R. L., Cheung, N. et al.:** The Prevalence of Retinal Vein Occlusion: Pooled Data from Population Studies from the United States, Europe, Asia, and Australia. *Ophthalmology*, 117, 2010: 313–319.
 18. **Řehák, J.:** Makulární edém u okluze sítnicové vény. In Ernest, J. et al.: *Makulární edémy*, Praha, Mladá fronta, 2014, s. 176–199.
 19. **Řehák J., Řehák, M.:** Venózní okluze sítnice, Praha, Grada Publishing, Praha, 2011, s. 51, s. 58.
 20. **Sivaprasad, S., Amoaku, W. M., Hykin, P. et al.:** The Royal College of Ophthalmologists Guidelines on retinal vein occlusions: executive summary. *Eye*, 29, 2015: 1633–1638.
 21. **Studnička J., Dusová, J., Skoupá, J. et al.:** Léčba makulárního edému při okluzi centrální sítnicové žíly Ozurdexem. *Čes. a Slov. Oftal*, 71, 2015: 199–203.
 22. **The Branch Vein Occlusion Study Group:** Argon Laser Photocoagulation for Macular Edema in Branch Vein Occlusion. *Am J Ophthalmol*, 98, 1984: 271–282.
 23. **The Central Vein Occlusion Study Group:** Natural History and Clinical Management of Central Retinal Vein Occlusion, *Arch Ophthalmol*, 115, 1997: 486–491.
 24. **The Central Vein Occlusion Study Group M report:** Evaluation of grid pattern photocoagulation for macular edema in central vein occlusion. *Ophthalmology*, 102, 1995: 1425–1433.
 25. **The Central Vein Occlusion Study Group N report:** A randomized clinical trial of early panretinal photocoagulation for ischemic central vein occlusion. *Ophthalmology*, 102, 1995: 1434–1444.
 26. **The Eye Disease Case-Control Study Group:** Risk Factors for Central Retinal Vein Occlusion. *Arch Ophthalmol*, 114, 1996: 545–554.